

Activate Online

For more effective study

- Access the complete set of cards and bonus cards
- Study with bonus multiple choice questions

REGISTER your PIN online now at
www.studentconsult.com




How to Register:

- 1 Gently scratch off the surface of the sticker at right with the edge of a coin to reveal your PIN code.
- 2 Visit www.studentconsult.com.
- 3 Follow the simple registration instructions.

NOTE: Product cannot be returned once panel is scratched off.

**Scratch off the panel
below for your PIN.**



Student | **CONSULT**

Activate your PIN today at www.studentconsult.com

Access to, and online use of, content through the STUDENT CONSULT website is for individual use only; library and institutional access and use are strictly prohibited. For information on products and services available for institutional access, please contact our Account Support Center at (+1) 877-857-1047. **Important note:** Purchase of this product includes access to the online version of this edition for use exclusively by the individual purchaser from the launch of the site. This license and access to the online version operates strictly on the basis of a single user per PIN number. The sharing of passwords is strictly prohibited, and any attempt to do so will invalidate the password. Access may not be shared, resold, or otherwise circulated, and will terminate 12 months after publication of the next edition of this product. Full details and terms of use are available upon registration, and access will be subject to your acceptance of these terms of use.

WWW.YAZDANPRESS.COM
SAUNDERS
ELSEVIER

1600 John F. Kennedy Blvd.
Ste 1800
Philadelphia, PA 19103-2899

NETTER'S ANATOMY FLASH CARDS

ISBN: 978-1-4377-1675-7

Copyright © 2011, 2007, 2002 by Saunders, an imprint of Elsevier Inc.

All rights reserved. No part of this book may be produced or transmitted in any form or by any means, electronic or mechanical, including photocopying, recording or any information storage and retrieval system, without permission in writing from the publishers. Permissions for Netter Art figures may be sought directly from Elsevier's Health Science Licensing Department in Philadelphia PA, USA: phone 1-800-523-1649, ext. 3276 or (215) 239-3276; or email H.Licensing@elsevier.com.

Notice

Knowledge and best practice in this field are constantly changing. As new research and experience broaden our knowledge, changes in practice, treatment and drug therapy may become necessary or appropriate. Readers are advised to check the most current information provided (i) on procedures featured or (ii) by the manufacturer of each product to be administered, to verify the recommended dose or formula, the method and duration of administration, and contraindications. It is the responsibility of the practitioner, relying on their own experience and knowledge of the patient, to make diagnoses, to determine dosages and the best treatment for each individual patient, and to take all appropriate safety precautions. To the fullest extent of the law, neither the Publisher nor the Editors assumes any liability for any injury and/or damage to persons or property arising out of or related to any use of the material contained in this book.

The Publisher

Library of Congress Cataloging-in-Publication Data

ISBN: 978-1-4377-1675-7

Acquisitions Editor: Elyse O'Grady
Developmental Editor: Marybeth Thiel
Publishing Services Manager: Linda Van Pelt
Project Manager: Francisco Morales
Design Direction: Louis Forgione

Printed in China

Last digit is the print number: 9 8 7 6 5 4 3 2 1

Working together to grow
libraries in developing countries

www.elsevier.com | www.bookaid.org | www.sabre.org

ELSEVIER

BOOK AID
International

Sabre Foundation

Section 1: Head and Neck

Section 2: Back and Spinal Cord

Section 3: Thorax

Section 4: Abdomen

Section 5: Pelvis and Perineum

Section 6: Upper Limb

Section 7: Lower Limb

Congratulations! You have just purchased the most popular and comprehensive set of anatomy flash cards available. *Netter's Anatomy Flash Cards* offer a unique learning resource to supplement the anatomy textbook, atlas, or dissection materials used in medical, dental, nursing, allied health, and undergraduate courses in human anatomy. This set of cards draws on the timeless medical illustrations of Frank H. Netter, MD, and includes not only the musculoskeletal system but also a review of important nerves, vessels, and visceral structures not commonly found in traditional flash card sets.

Each 4 × 6 full-color card details human anatomy as only Netter can. The set is organized regionally in accordance with Netter's widely popular *Atlas of Human Anatomy* (i.e., Head and Neck; Back and Spinal Cord; Thorax; Abdomen; Pelvis and Perineum; Upper Extremity; Lower Extremity). Within each region, cards are arranged sequentially as follows: Bones and Joints; Muscles; Nerves; Vessels; and Viscera. Moreover, the image on each card is referenced to the original plate in the *Atlas of Human Anatomy*, 5th Edition. Because each section opening card is slightly taller, you can easily pull out an entire section of cards for study. In addition, a corner of each card is prepunched so that you can insert it on the enclosed metal ring to keep an entire section of cards in the correct order.

Each card includes a **Comment** section, which provides relevant information about the structure(s) depicted on the front of the card, including detailed information for muscle origins, insertions, actions, and innervation. Most cards also contain a **Clinical** section that highlights the clinical relevance of the anatomy depicted on the front of the card. Bonus online content is available at www.studentconsult.com using the scratch-off PIN code on the first card. Online content includes over 300 **multiple-choice questions** to test your retention of the material. Over 20 bonus flash cards from other card sets within the Netter family of flash cards are also available on Student Consult. These cards offer an accurate and ready source of anatomic information in an easy-to-use and portable format.

Consensus regarding the specific anatomic details of such topics as muscle attachments or the range of motion of joints can vary considerably among anatomy textbooks. In fact, human anatomic variation is common and normal. Consequently, the anatomic detail provided on these cards represents commonly accepted information whenever possible. I am indebted to and wish to credit the following superb sources and their authors or editors:

Gray's Anatomy for Students, 2nd ed. Drake R, Vogl W, Mitchell A. Philadelphia, Elsevier, 2010.

Gray's Anatomy, 39th ed. Standring S. Philadelphia, Elsevier, 2005.

Netter's Clinical Anatomy, 2nd ed. Hansen JT. Philadelphia, Elsevier, 2010.

Clinically Oriented Anatomy, 6th ed. Moore KL, Dalley DR, Agur AMR. Philadelphia, Lippincott Williams & Wilkins, 2010.

Grant's Atlas of Anatomy, 12th ed. Philadelphia, Lippincott Williams & Wilkins, 2009.

Hollinshead's Textbook of Anatomy, 5th ed. Rosse C, Gaddum-Rosse P. Philadelphia, Lippincott Williams & Wilkins, 1997.

My hope is that the Netter Flash Cards will make learning more enjoyable and productive, and that the study of anatomy will inspire you with a sense of awe and respect for the human form.

John T. Hansen, PhD

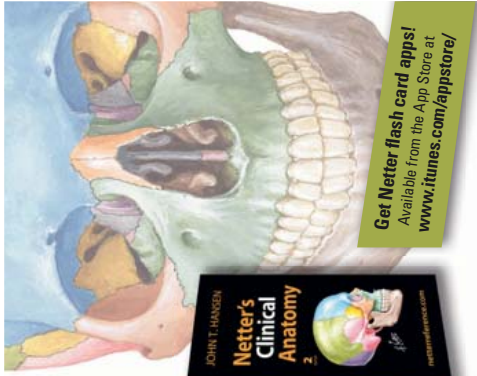Professor and Associate Dean

Department of Neurobiology and Anatomy

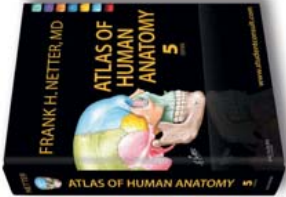
University of Rochester Medical Center

Rochester, New York

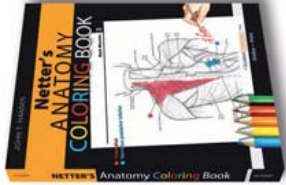
If the human body is your territory,
Netter is your map!



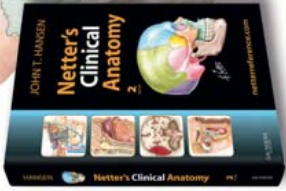
Get Netter flash card apps!
Available from the App Store at
www.itunes.com/appstore/



Atlas of Human Anatomy, 5th Edition
(978-1-4160-5951-6)



Netter's Anatomy Coloring Book
(978-1-4160-4702-5)



Netter's Clinical Anatomy, 2nd Edition
(978-1-4377-0272-9)



Look for these and other great **Netter products** at your local medical bookstore or visit www.elsevierhealth.com.

USMLE | CONSULT

STEPS ① ② ③

**SAVE
30%**

Subscribe to any USMLE Consult Step 1 product OR the Robbins Pathology Test Bank today and save 30% on your purchase!

Look for the Netter images in your USMLE Consult remediation for superior visual guidance.

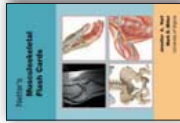


Order securely online at www.usmleconsult.com today.

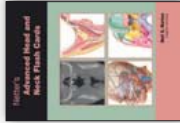Activate discount code **HANSENF30** to redeem special savings.

©Elsevier 2010-2012. Offer valid on subscriptions to USMLE Consult Step 1 products only. Expires 12/31/2012.

More exquisitely illustrated sets to help you review!
The Netter Flash Card Series



Netter's
Musculoskeletal
Flash Cards
(978-1-4160-4630-1)



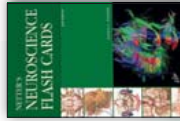Netter's
Advanced Head &
Neck Flash Cards
(978-1-4160-4631-8)



Netter's
Histology
Flash
Cards
(978-1-4160-4629-5)



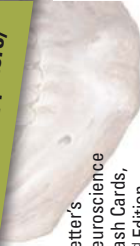Netter's
Physiology
Flash Cards
(978-1-4160-4628-8)



Netter's
Neuroscience
Flash Cards,
2nd Edition
(978-1-4377-0940-7)



Get Netter flash card apps!
Available from the App Store at
www.itunes.com/appstore/



Netter
F. Netter, M.D.



Look for these and other great **Netter products** at your local medical bookstore or visit www.elsevierhealth.com.

WWW.YAZDANPRESS.COM

NEW!

Netter's 3D Interactive Anatomy



InteractElsevier

powered by



CYBER-ANATOMY



ANATOMY EDUCATION

like never before!



Learn more at

www.interactelsevier.com!

Bones and Joints

- 1-1** Skull: Anterior View
- 1-2** Skull: Lateral View
- 1-3** Skull: Midsagittal Section
- 1-4** Lateral Wall of Nasal Cavity
- 1-5** Cranial Base: Inferior View
- 1-6** Foramina of Cranial Base: Superior View
- 1-7** Mandible: Anterolateral Superior View
- 1-8** Mandible: Left Posterior View
- 1-9** Temporomandibular Joint
- 1-10** Teeth
- 1-11** Tooth
- 1-12** Cervical Vertebrae: Atlas and Axis
- 1-13** External Craniocervical Ligaments
- 1-14** Internal Craniocervical Ligaments
- 1-15** Cartilages of Larynx
- 1-16** Auditory Ossicles

Muscles

- 1-17** Frontal Belly (Frontalis) of Epicranium Muscle
- 1-18** Occipital Belly (Occipitalis) of Epicranium Muscle
- 1-19** Orbicularis Oculi
- 1-20** Zygomaticus Major and Zygomaticus Minor
- 1-21** Orbicularis Oris
- 1-22** Depressor Anguli Oris
- 1-23** Buccinator



- 1-24** Platysma
- 1-25** Muscles of Facial Expression: Lateral View
- 1-26** Levator Palpebrae Superioris
- 1-27** Extrinsic Eye Muscles
- 1-28** Temporalis
- 1-29** Masseter
- 1-30** Medial Pterygoid
- 1-31** Lateral Pterygoid
- 1-32** Mylohyoid
- 1-33** Geniohyoid
- 1-34** Genioglossus
- 1-35** Hyoglossus
- 1-36** Styloglossus
- 1-37** Levator Veli Palatini
- 1-38** Tensor Veli Palatini
- 1-39** Roof of Mouth
- 1-40** Superior Pharyngeal Constrictor
- 1-41** Middle Pharyngeal Constrictor
- 1-42** Inferior Pharyngeal Constrictor
- 1-43** Stylopharyngeus
- 1-44** Sternocleidomastoid
- 1-45** Sternohyoid
- 1-46** Sternothyroid
- 1-47** Omohyoid
- 1-48** Thyrohyoid
- 1-49** Cricothyroid

- 1-50** Stylohyoid
- 1-51** Digastric
- 1-52** Oblique Arytenoids and Transverse Arytenoids
- 1-53** Posterior Cricoaarytenoid
- 1-54** Muscles of Larynx
- 1-55** Scalene Muscles
- 1-56** Longus Capitis and Longus Colli

Nerves

- 1-57** Cutaneous Nerves of Head and Neck
- 1-58** Facial Nerve Branches
- 1-59** Oculomotor, Trochlear, and Abducens Nerves:
Schema
- 1-60** Nerves of Orbit
- 1-61** Mandibular Nerve (CN V₃)
- 1-62** Nerves of Nasal Cavity
- 1-63** Autonomic Nerves in Head
- 1-64** Vestibulocochlear Nerve: Schema
- 1-65** Glossopharyngeal Nerve
- 1-66** Cervical Plexus In Situ

Vessels

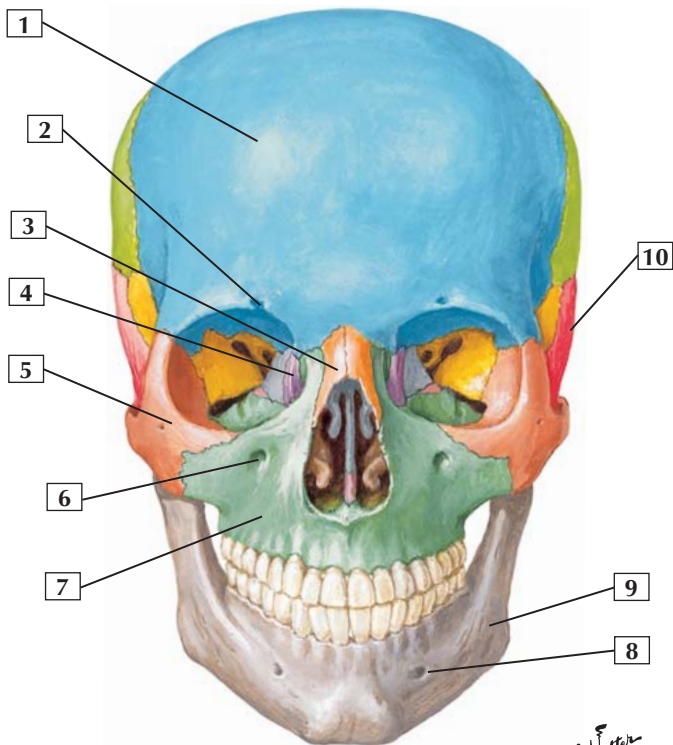
- 1-67** Superficial Veins and Arteries of Neck
- 1-68** Subclavian Artery
- 1-69** Carotid Arteries
- 1-70** Maxillary Artery



- 1-71** Arteries of Oral and Pharyngeal Regions
- 1-72** Veins of Oral and Pharyngeal Regions
- 1-73** Arteries of Brain: Inferior View
- 1-74** Dural Venous Sinuses
- 1-75** Schematic of Meninges

Viscera

- 1-76** Superficial Face and Parotid Gland
- 1-77** Lacrimal Apparatus
- 1-78** Eyeball: Horizontal Section
- 1-79** Anterior and Posterior Chambers of the Eye
- 1-80** Ear: Frontal Section
- 1-81** Lateral Wall of Nasal Cavity
- 1-82** Salivary Glands
- 1-83** Parathyroid and Thyroid Glands: Posterior View
- 1-84** Pharynx: Opened Posterior View



*F. Netter
M.D.*

1. Frontal bone
2. Supraorbital notch (foramen)
3. Nasal bone
4. Lacrimal bone
5. Zygomatic bone
6. Infraorbital foramen
7. Maxilla
8. Mental foramen
9. Mandible
10. Temporal bone

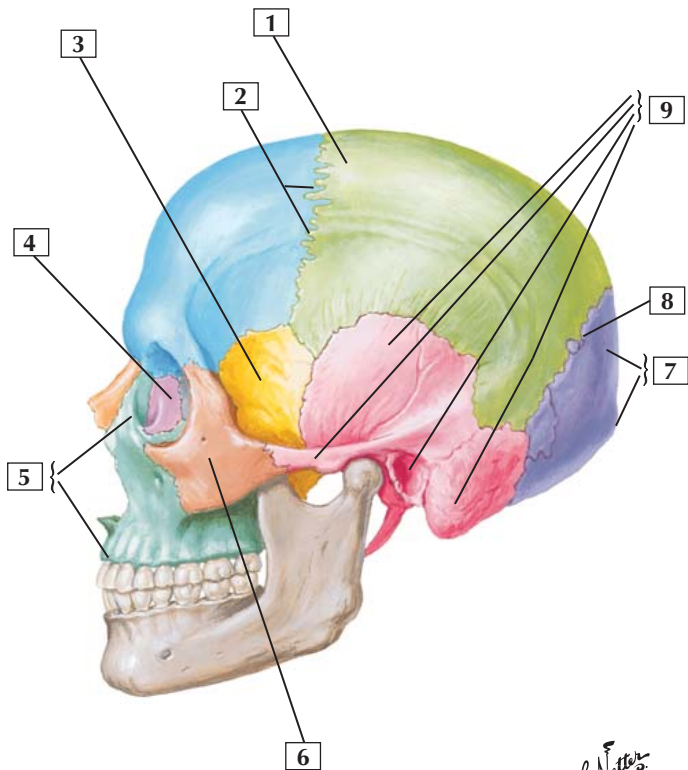
Comment: The skull bones are fused together at immovable, fibrous joints, such as the sutures.

The 2 general classes of skull bones are cranial bones (8 bones), which enclose the brain, and facial bones (14 bones). The 8 cranial bones are the frontal, occipital, ethmoid, and sphenoid bones, a pair of temporal bones, and a pair of parietal bones.

Associated bones of the skull include the auditory ossicles (3 in each middle ear cavity) and the unpaired hyoid bone. The skull and associated bones constitute 29 different bones (the 32 adult teeth are part of the mandible and maxilla and are not counted separately).

Clinical: Le Fort midface fractures:

- Le Fort I: horizontal fracture detaching the maxilla along the nasal floor
- Le Fort II: pyramidal fracture that includes both maxillae, nasal bones, infraorbital rims, and orbital floors
- Le Fort III: includes the Le Fort II fracture and both zygomatic bones



*F. Netter
M.D.*

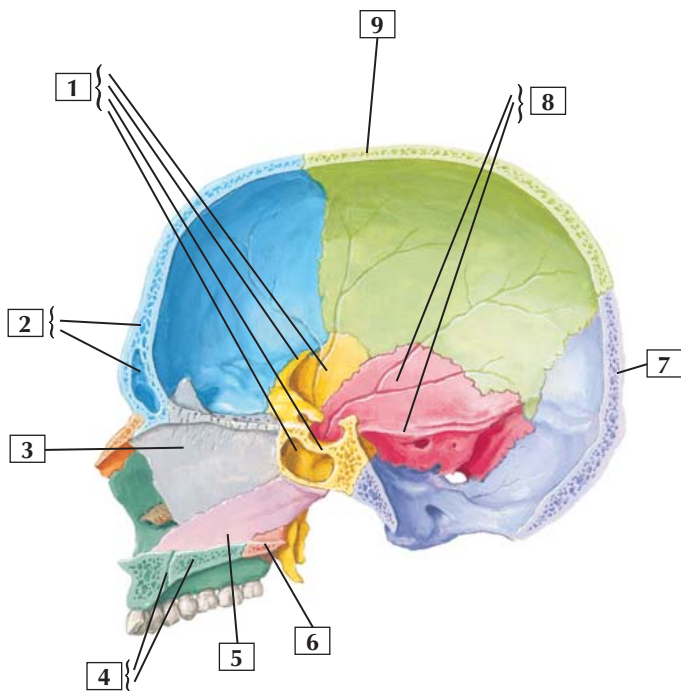
1. Parietal bone
2. Coronal suture
3. Sphenoid bone
4. Lacrimal bone
5. Maxilla (Frontal process; Alveolar process)
6. Zygomatic bone
7. Occipital bone (External occipital protuberance)
8. Lambdoid suture
9. Temporal bone (Squamous part; Zygomatic process; External acoustic meatus; Mastoid process)

Comment: This lateral view shows many bones of the cranium and some of the sutures of the skull. The coronal suture lies between the frontal bone and the paired parietal bones. The lambdoid suture lies between the paired parietal bones and the occipital bone.

The pterion is the site of union of the frontal, parietal, sphenoid, and temporal bones. A blow to the head or a skull fracture in this region is dangerous because the bone at this site is thin, and the middle meningeal artery, supplying the dural covering of the brain, lies just deep to this area.

Clinical: Skull fractures may be classified as:

- Linear: have a distinct fracture line
- Comminuted: have multiple bone fragments (depressed if driven inwardly, which can tear the dura mater)
- Diastasis: a fracture along a suture line
- Basilar: a fracture of the base of the skull



*F. Netter
M.D.*

1. Sphenoid bone (Greater wing; Lesser wing; Sella turcica; Sphenoidal sinus)
2. Frontal bone (Frontal sinus)
3. Ethmoid bone (Perpendicular plate)
4. Maxilla (Incisive canal; Palatine process)
5. Vomer
6. Palatine bone
7. Occipital bone
8. Temporal bone (Squamous part; Petrous part)
9. Parietal bone

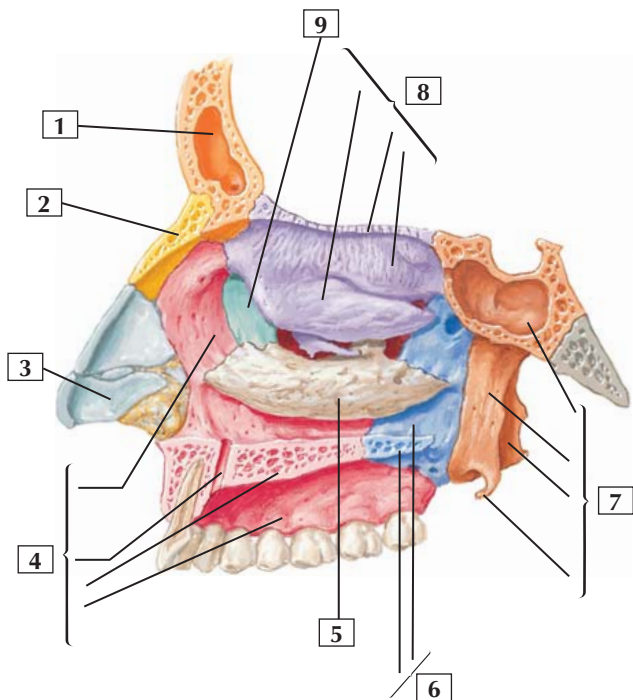
Comment: Note the interior of the cranium and the nasal septum. The 8 cranial bones enclosing the brain include the unpaired frontal, occipital, ethmoid, and sphenoid bones and the paired temporal and parietal bones. The 14 facial bones include the paired lacrimal, nasal, palatine, inferior turbinate (not shown), maxillary, and zygomatic bones (not shown) and the unpaired vomer and mandible (not shown).

The nasal septum is formed by the perpendicular plate of the ethmoid bone, the vomer, and the palatine bones and septal cartilages.

The petrous portion of the temporal bone contains the middle and inner ear cavities and the vestibular system.

Clinical: A blow to the skull that results in a fracture can tear the underlying periosteal layer of dura mater, which can result in an epidural (extradural) hematoma and/or leakage of the cerebrospinal fluid.

A slight deviation of the nasal septum is common. However, if this is severe or if deviated as a result of trauma, then it may be corrected surgically so as not to interfere with breathing.



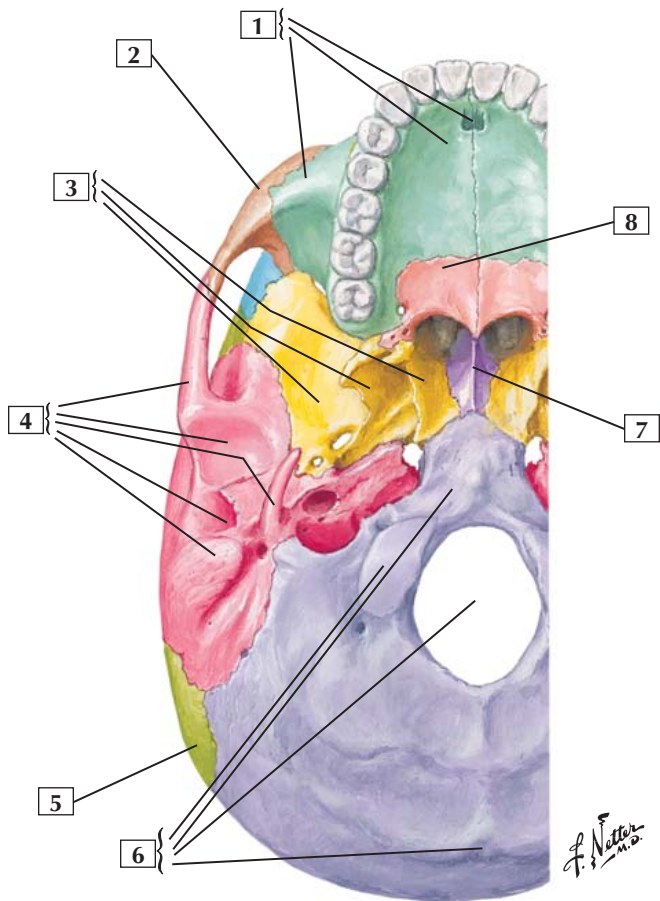
*F. Netter
M.D.*

1. Frontal bone (sinus)
2. Nasal bone
3. Major alar cartilage
4. Maxilla (Frontal process; Incisive canal; Palatine process; Alveolar process)
5. Inferior nasal concha
6. Palatine bone (Perpendicular plate; Horizontal plate)
7. Sphenoid bone (Sphenoidal sinus; Medial and Lateral plates of pterygoid process; Pterygoid hamulus)
8. Ethmoid bone (Middle nasal concha; Cribriform plate; Superior nasal concha)
9. Lacrimal bone

Comment: The lateral wall of the nasal cavity prominently displays the superior and middle conchae (turbinates) of the ethmoid bone and the inferior concha. Portions of other bones, including the nasal bone, maxilla, lacrimal bone, palatine bone, and sphenoid bone, contribute to the lateral wall.

The palatine processes of the maxillae and the horizontal plates of the palatine bones make up the hard palate.

Clinical: The pituitary gland lies in the hypophysial fossa, a depression seen just superior to the sphenoidal sinus in the sphenoid bone. The pituitary gland can be approached surgically through the nasal cavity by passing through the sphenoidal sinus and directly into the hypophysial fossa (trans-sphenoidal resection).

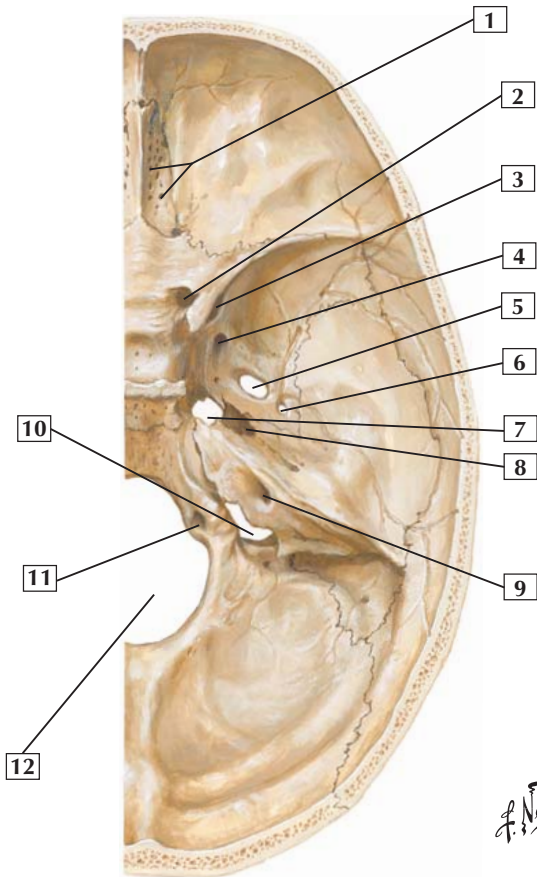


1. Maxilla (Incisive fossa; Palatine process; Zygomatic process)
2. Zygomatic bone
3. Sphenoid bone (Medial plate; Lateral plate; Greater wing)
4. Temporal bone (Zygomatic process; Mandibular fossa; Styloid process; External acoustic meatus; Mastoid process)
5. Parietal bone
6. Occipital bone (Occipital condyle; Basilar part; Foramen magnum; External occipital protuberance)
7. Vomer
8. Palatine bone (Horizontal plate)

Comment: Cranial bones and facial bones contribute to the base of the skull. Key processes and foramina associated with these bones can be seen in this inferior view.

The largest foramen of the skull is the foramen magnum, the site where the spinal cord and brainstem (medulla oblongata) are continuous.

Clinical: Basilar fractures (fractures of the cranial base) may damage important neurovascular structures passing into or out of the cranium via foramina (openings). The internal carotid artery may be torn, cranial nerves may be damaged, and the dura mater may be torn, resulting in leakage of the cerebrospinal fluid.

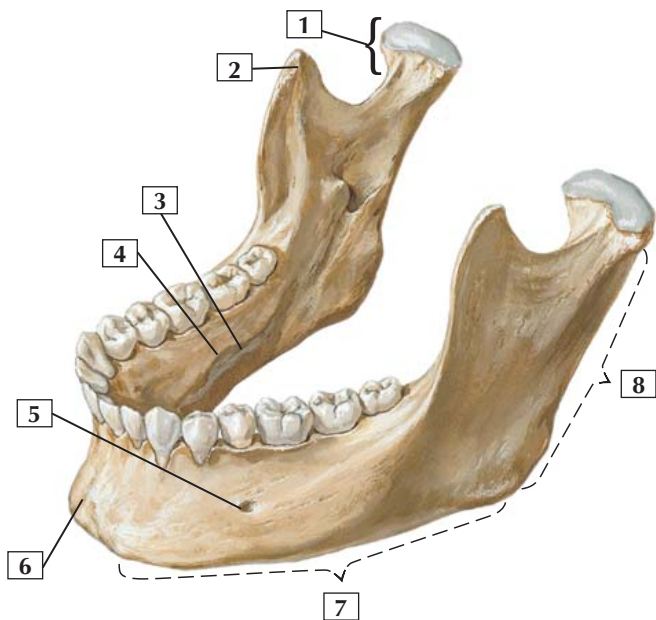


Foramina of Cranial Base: Superior View

1. Foramina of cribriform plate (Olfactory nerve bundles)
2. Optic canal (Optic nerve [CN II]; Ophthalmic artery)
3. Superior orbital fissure (Oculomotor nerve [CN III]; Trochlear nerve [CN IV]; Lacrimal, frontal, and nasociliary branches of ophthalmic nerve [CN V₁]; Abducens nerve [CN VI]; Superior ophthalmic vein)
4. Foramen rotundum (Maxillary nerve [CN V₂])
5. Foramen ovale (Mandibular nerve [CN V₃]; Accessory meningeal artery; Lesser petrosal nerve [occasionally])
6. Foramen spinosum (Middle meningeal artery and vein; Meningeal branch of mandibular nerve)
7. Foramen lacerum
8. Carotid canal (Internal carotid artery; Internal carotid nerve plexus)
9. Internal acoustic meatus (Facial nerve [CN VII]; Vestibulocochlear nerve [CN VIII]; Labyrinthine artery)
10. Jugular foramen (Inferior petrosal sinus; Glossopharyngeal nerve [CN IX]; Vagus nerve [CN X]; Accessory nerve [CN XI]; Sigmoid sinus; Posterior meningeal artery)
11. Hypoglossal canal (Hypoglossal nerve [CN XII])
12. Foramen magnum (Medulla oblongata; Meninges; Vertebral arteries; Meningeal branches of vertebral arteries; Spinal roots of accessory nerves)

Comment: Key structures passing through each foramen are noted in parentheses.

Clinical: Fractures or trauma involving any of these foramina may result in clinical signs and symptoms associated with the neurovascular elements passing through the foramen. Thus, it is important to know these structures and their relationships to the cranial base.



*F. Netter
M.D.*

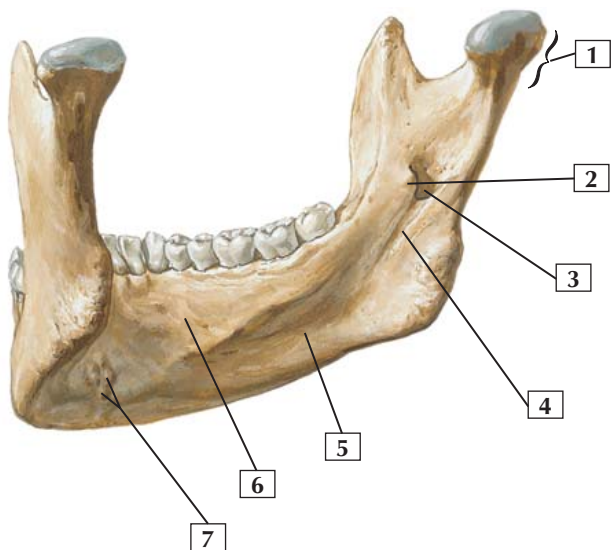
1. Condylar process (head and neck)
2. Coronoid process
3. Submandibular fossa
4. Mylohyoid line
5. Mental foramen
6. Mental protuberance
7. Body
8. Ramus

Comment: The mandible, or lower jaw, contains the mandibular teeth and the mandibular foramen. The inferior alveolar neurovascular bundle passes through the mandibular foramen; it innervates the mandibular teeth and supplies them with blood. The nerve ends as a cutaneous branch that exits the mental foramen (mental nerve).

The condylar process of the mandible articulates with the temporal bone, forming the temporomandibular joint.

Because of its vulnerable location, the mandible is the second most commonly fractured facial bone (the nasal bone is first). The most common sites of fracture are the cuspid (canine tooth) area and the third molar area.

Clinical: Fractures of the mandible are fairly common. The mandible's U-shape renders it liable to multiple fractures, which occur in over 50% of cases. The most common sites of fracture are the cuspid (canine tooth) area and the area just anterior to the third molar (wisdom tooth) area. When fractured, blood oozing from the mandible may collect in the loose tissues of the floor of the mouth, above the mylohyoid muscle.



*F. Netter
M.D.*

Mandible: Left Posterior View

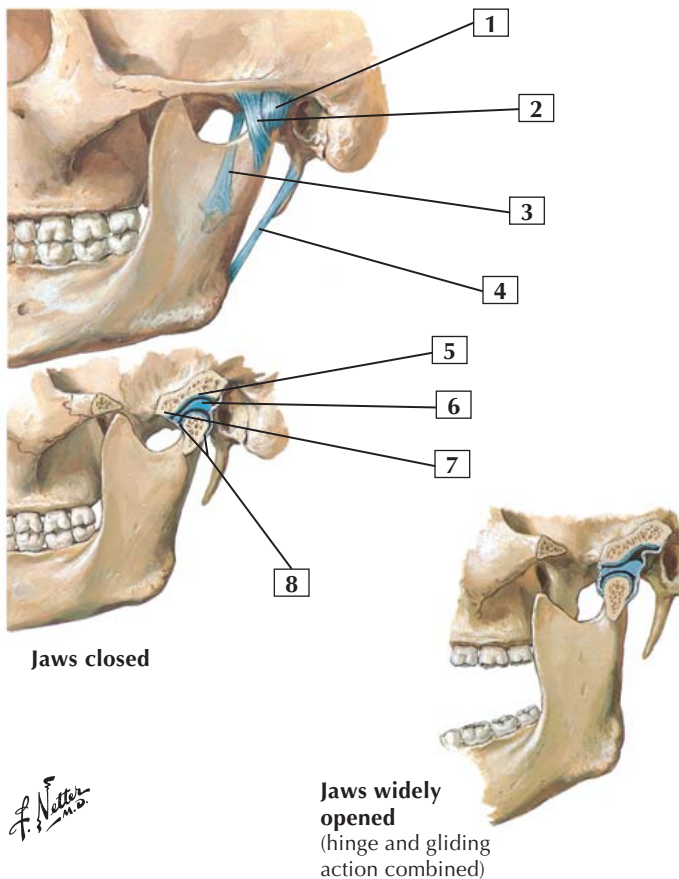
1. Condylar process
2. Lingula
3. Mandibular foramen
4. Mylohyoid groove
5. Submandibular fossa
6. Sublingual fossa
7. Mental spines

Comment: The inferior alveolar neurovascular bundle enters the mandibular foramen and courses through the bony mandible to supply the mandibular teeth and gums.

Depressions, or fossae, on the medial side of the mandible mark the locations of the submandibular and sublingual salivary glands.

Clinical: The mandible is the strongest and largest of the facial bones, and its landmarks are used for dental anesthesia via intraoral injections. When properly performed, infiltration of an anesthetic anesthetizes the inferior alveolar nerve and lingual nerve ipsilaterally (on the same side as the injection) where they lie in the pterygomandibular space proximal to the mandibular foramen. This will anesthetize the mandibular teeth (inferior alveolar nerve), the epithelium of the anterior two-thirds of the tongue (lingual nerve), all the lingual mucosa and lingual gingiva (gums) (lingual nerve), all the buccal mucosa and buccal gingiva from the premolars to the midline (mental nerve/terminal branch of the inferior alveolar nerve), and the skin of the lower lip (also via the mental nerve) ipsilaterally.

Lateral view



Jaws closed

Jaws widely
opened
(hinge and gliding
action combined)

*F. Netter
M.D.*

Temporomandibular Joint

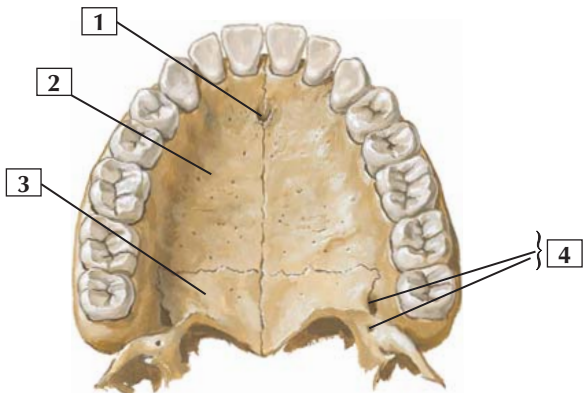
1. Joint capsule
2. Lateral (temporomandibular) ligament
3. Sphenomandibular ligament (phantom)
4. Stylomandibular ligament
5. Mandibular fossa
6. Articular disc
7. Articular tubercle
8. Joint capsule

Comment: The temporomandibular joint is the synovial joint between the mandibular fossa and the articular tubercle of the temporal bone and head of the mandible. The joint's 2 synovial cavities are separated by an articular disc.

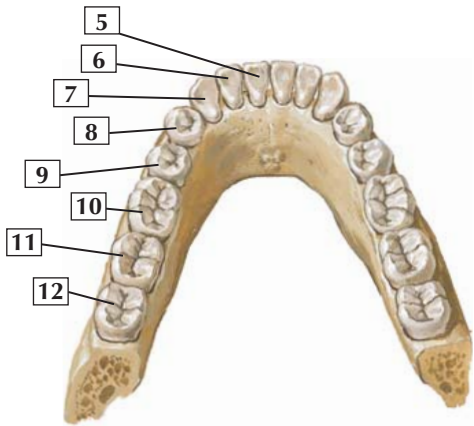
This unique joint combines an upper uniaxial, gliding joint, for forward gliding (protrusion) and backward gliding (retraction) movements and some side-to-side motion. The lower joint, below the articular disc, is a uniaxial hinge joint for closing (elevation) and opening (depression) the jaw.

This joint contains an articular capsule and is reinforced by the lateral and sphenomandibular ligaments.

Clinical: The temporomandibular joint (TMJ) has both a hinge and a gliding or sliding action. TMJ problems affect about 25% of the population and can result from trauma, arthritis, infection, clenching or grinding of the teeth (bruxism), or displacement of the articular disc. TMJ problems are more common in women than men.



Upper permanent teeth



Lower permanent teeth

*F. Netter
M.D.*

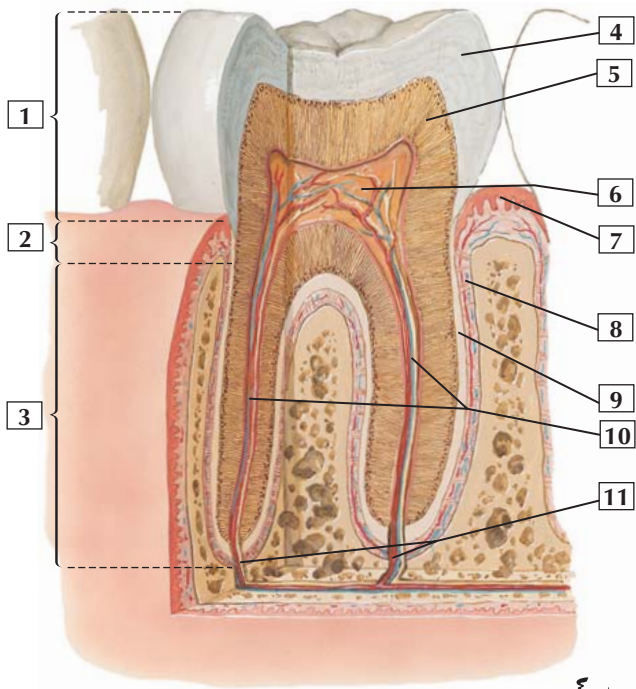
1. Incisive fossa
2. Palatine process of maxilla
3. Horizontal plate of palatine bone
4. Greater and lesser palatine foramina
5. Central incisor
6. Lateral incisor
7. Canine
8. 1st premolar
9. 2nd premolar
10. 1st molar
11. 2nd molar
12. 3rd molar

Comment: Humans have 2 sets of teeth: the deciduous teeth, which total 20, and the permanent teeth (shown in this illustration), which total 32 (16 maxillary and 16 mandibular teeth).

Permanent teeth in each quadrant of the jaw (mandible and maxilla) include 2 incisors, 1 canine, 2 premolars, and 3 molars. The third molars are often referred to as the wisdom teeth.

The maxillary teeth are innervated by the superior alveolar branches of the maxillary nerve. The mandibular teeth are innervated by the inferior alveolar branch of the mandibular nerve.

Clinical: Because of its vulnerable location, the mandible is the second most commonly fractured facial bone (the nasal bone is first). The most common sites of fracture are the cuspid (canine tooth) area and just anterior to the third molar area.



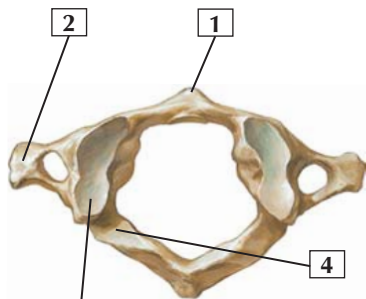
*F. Netter
M.D.*

1. Crown
2. Neck
3. Root
4. Enamel (substantia adamantina)
5. Dentine and dentinal tubules (substantia eburnea)
6. Dental pulp containing vessels and nerves
7. Gingival (gum) epithelium (stratified)
8. Periodontium (alveolar periosteum)
9. Cement (cementum)
10. Root (central) canals containing vessels and nerves
11. Apical foramina

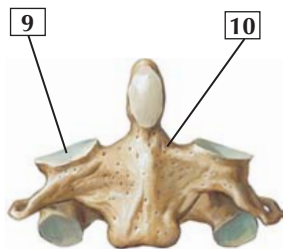
Comment: Each tooth is composed of an enamel-covered crown, dentine, and pulp. The pulp fills a central cavity and is continuous with the root canal. Blood vessels, nerves, and lymphatics enter the pulp through an apical foramen.

The crown projects above the gum, or gingival surface. The narrow portion between the crown and root is called the neck. The root is embedded in the alveolar bone of the maxilla or mandible and is covered by cement, which is connected to the alveolar bone by the periodontal ligament.

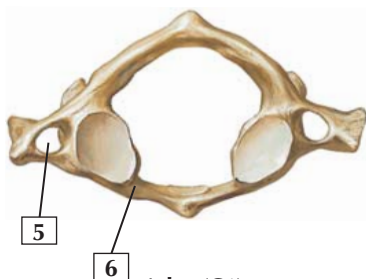
Clinical: Dental caries (tooth decay) is caused by oral bacteria that convert food into acids that then form dental plaque (a combination of bacteria, food particles, and saliva). Foods rich in sugars and starch may increase one's risk for forming plaque. If not removed by brushing, the plaque can mineralize and form tartar. Acid in the dental plaque can erode the tooth enamel and create a cavity. This may occur even though enamel (an acellular mineralized tissue) is the hardest material in the human body, consisting of 96-98% calcium hydroxyapatite.



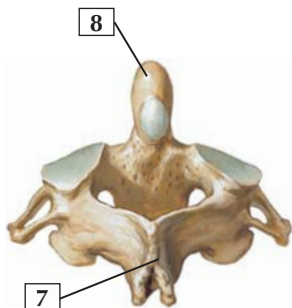
Atlas (C1):
superior view



Axis (C2):
anterior view



Atlas (C1):
inferior view



Axis (C2):
posterosuperior view

*F. Netter
M.D.*

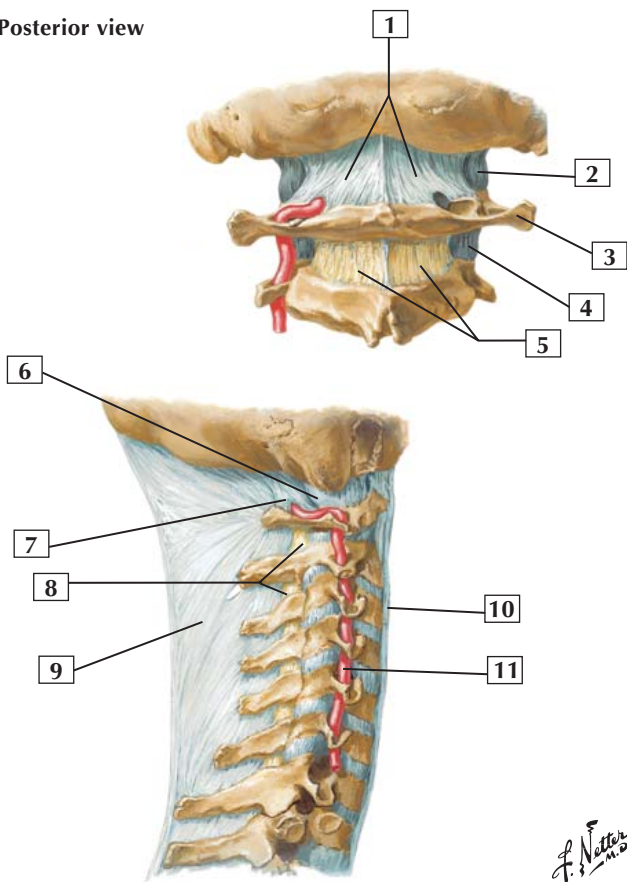
1. Anterior tubercle
2. Transverse process
3. Superior articular surface of lateral mass for occipital condyle
4. Groove for vertebral artery
5. Transverse foramen
6. Anterior arch
7. Spinous process
8. Dens
9. Superior articular facet for atlas
10. Pedicle

Comment: The 1st cervical vertebra is the atlas. It is named after the Greek god Atlas, who is often depicted with the world on his shoulders. The atlas has no body or spine but is made of anterior and posterior arches. The transverse processes contain a foramen that transmits the vertebral vessels.

The 2nd cervical vertebra is the axis. Its most characteristic feature is the dens (odontoid process). The dens articulates with the anterior arch of the atlas, providing a pivot about which the atlas and head can rotate.

Clinical: A blow to the top of the head may fracture the atlas, usually across the anterior and posterior arch. Such a fracture is called a Jefferson fracture. Fractures of the axis often involve the dens or involve a fracture across the neural arch between the superior and inferior articular facets. This is referred to as a “hangman” fracture.

Posterior view

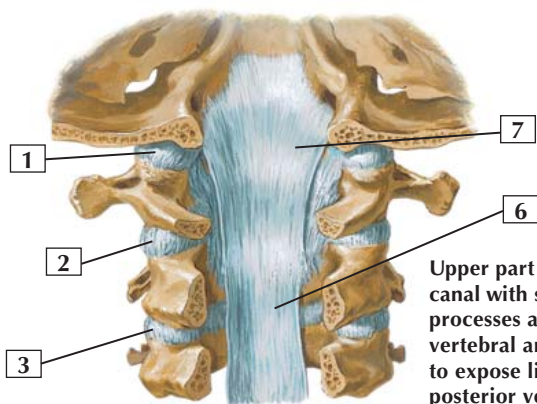


F. Netter M.D.

1. Posterior atlanto-occipital membrane
2. Capsule of atlanto-occipital joint
3. Transverse process of atlas (C1)
4. Capsule of lateral atlantoaxial joint
5. Ligamenta flava
6. Capsule of atlanto-occipital joint
7. Posterior atlanto-occipital membrane
8. Ligamenta flava
9. Ligamentum nuchae
10. Anterior longitudinal ligament
11. Vertebral artery

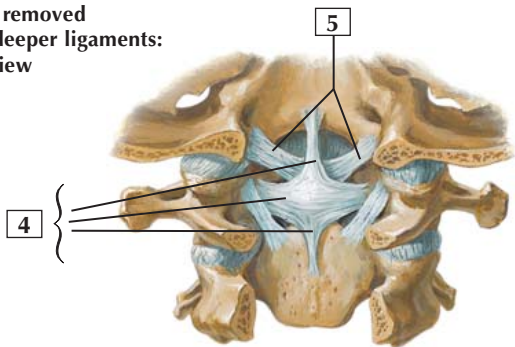
Comment: The atlanto-occipital joint, on each side, is covered with an articular capsule and posteriorly reinforced by the posterior atlanto-occipital membrane.

The ligamentum nuchae is a strong median fibrous septum. It is an extension of the thickened supraspinous ligaments that arise from the spinous process of C7 and extend to the external occipital protuberance.



Upper part of vertebral canal with spinous processes and parts of vertebral arches removed to expose ligaments on posterior vertebral bodies: posterior view

Principal part of tectorial membrane removed to expose deeper ligaments: posterior view



F. Netter M.D.

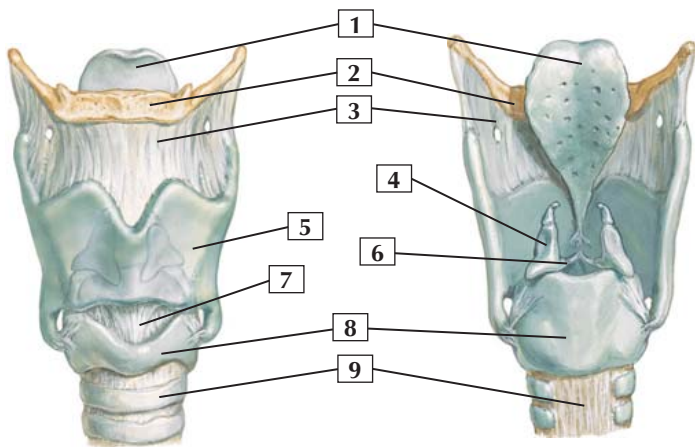
1. Capsule of atlanto-occipital joint
2. Capsule of lateral atlantoaxial joint
3. Capsule of zygapophyseal joint (C2-3)
4. Cruciate ligament (Superior longitudinal band; Transverse ligament of atlas; Inferior longitudinal band)
5. Alar ligaments
6. Posterior longitudinal ligament
7. Tectorial membrane

Comment: The atlanto-occipital joint is a biaxial condyloid synovial joint between the atlas and the occipital condyles. It permits flexion and extension, as when the head is nodded, and some lateral bending.

The atlantoaxial joints are uniaxial synovial joints. They consist of plane joints associated with the articular facets and a median pivot joint between the dens of the axis and the anterior arch of the atlas. The atlantoaxial joint permits the atlas and head to be rotated as a single unit, as when the head is turned from side to side.

These joints are reinforced by ligaments, especially the cruciate and alar ligaments. The alar ligaments limit rotation.

Clinical: Osteoarthritis is the most common form of arthritis and often involves erosion of the articular cartilage of weight-bearing joints, including the cervical spine. Extensive thinning of the intervertebral discs and of the cartilage covering the facet joints can lead to hyperextension of the cervical spine, narrowing of the intervertebral foramen, and the potential for impingement of the spinal nerves exiting the intervertebral foramen.



Anterior view

Posterior view

*F. Netter
M.D.*

1. Epiglottis
2. Hyoid bone
3. Thyrohyoid membrane
4. Arytenoid cartilage
5. Thyroid cartilage lamina
6. Vocal ligament
7. Median cricothyroid ligament
8. Cricoid cartilage
9. Trachea

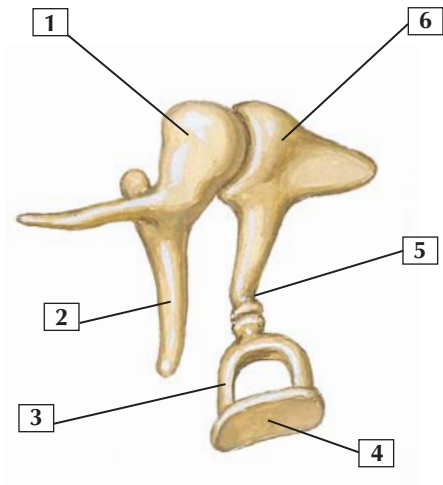
Comment: The cartilages of the larynx include the thyroid cartilage, cricoid cartilage, epiglottis, and the paired arytenoid, corniculate, and cuneiform cartilages.

Not shown in the illustration are the cuneiform cartilages. These paired elastic cartilages lie in the aryepiglottic folds and have no articulations with other cartilages or bone.

The thyroid cartilage possesses the anteriorly placed laryngeal prominence, or Adam's apple.

The thyrohyoid membrane has an opening through which the internal branch of the superior laryngeal nerve enters the larynx to provide sensory innervation above the vocal folds.

Clinical: Trauma to the cartilages of the larynx may result in fractures. Consequently, the underlying laryngeal mucosa and submucosa may hemorrhage, resulting in significant edema and the potential for airway obstruction. Ultimately, such an injury may result in hoarseness as the vocal folds swell and/or are compromised by the damage (muscle or nerve damage), making speaking difficult or impossible.

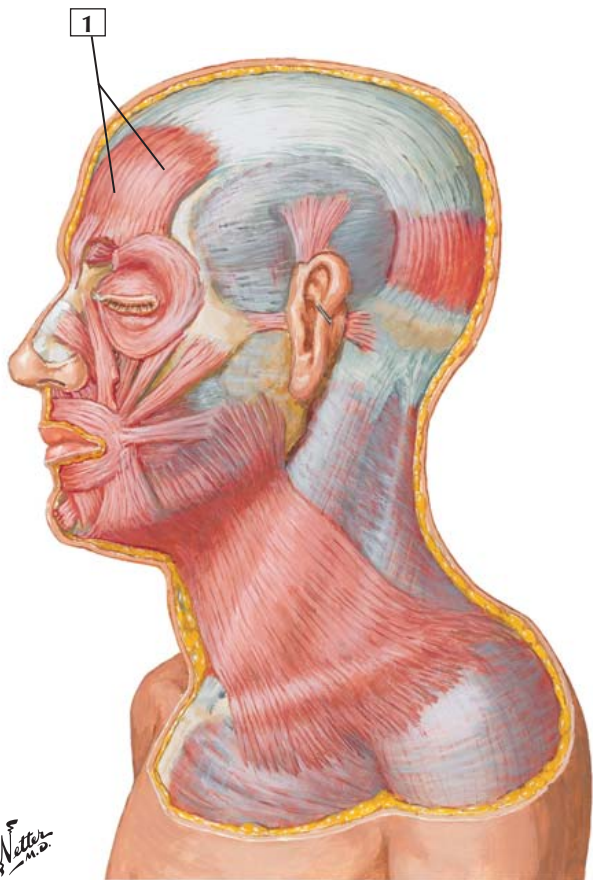


*F. Netter
M.D.*

1. Malleus (head)
2. Handle of malleus
3. Stapes
4. Base of stapes (footplate)
5. Lenticular process of incus
6. Incus

Comment: The 3 auditory ossicles reside in the middle ear, or tympanic cavity. They amplify sonic vibrations from the tympanic membrane and transmit them to the inner ear.

The 3 ear ossicles are the malleus (hammer), incus (anvil), and stapes (stirrup). The handle of the malleus is fused with the medial aspect of the tympanic membrane; the head articulates with the incus. The incus articulates with the stapes, whose footplate is attached to the oval window.



WWW.YAZDANPRESS.COM

Frontal Belly (Frontalis) of Epicranium Muscle

1. Frontal belly (frontalis) of epicranium muscle

Origin: This muscle has no bony origin, and its fibers arise and are continuous with 2 other anterior facial muscles, the procerus and the corrugator supercilii.

Insertion: The fibers are directed upward. They join the galea aponeurotica anterior to the coronal suture.

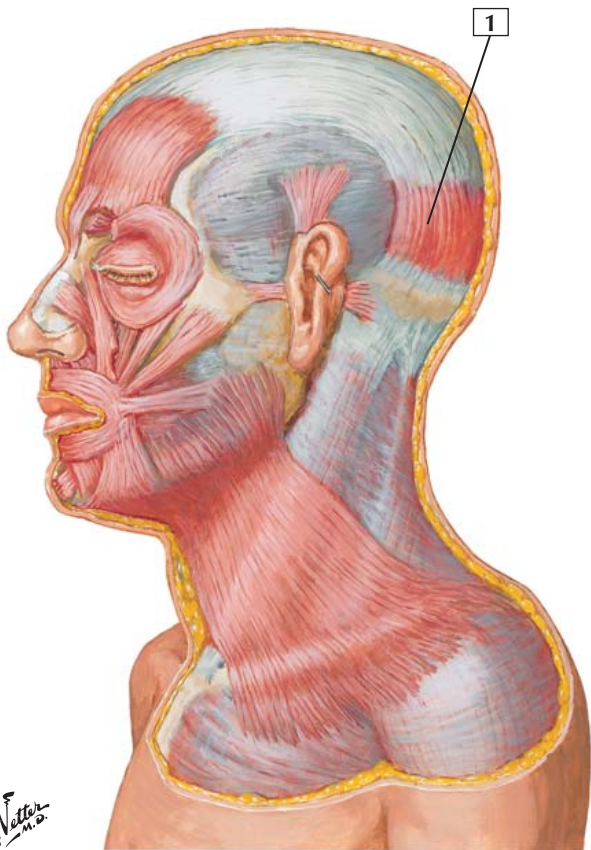
Action: Elevates the eyebrows and wrinkles the forehead, as when a person looks surprised.

Innervation: Branches of the facial nerve.

Comment: The epicranium muscle consists largely of the frontal and occipital bellies and an intervening galea aponeurotica (aponeurosis).

As a muscle of facial expression, this cutaneous muscle lies within the layers of the superficial fascia. These muscles vary from person to person, and they often blend together.

Clinical: All of the muscles of facial expression are derived embryologically from the second pharyngeal (branchial) arch and are innervated by the terminal branches of the facial nerve (CN VII). Acute, unilateral facial palsy is the most common cause of facial muscle weakness and is called Bell's palsy. In Bell's palsy, paralysis of the frontalis portion of the epicranium muscle would result in an inability to raise one's eyebrows and wrinkle the forehead skin.



Occipital Belly (Occipitalis) of Epicranium Muscle

1. Occipital belly (occipitalis) of epicranium muscle

Origin: Arises from the lateral two-thirds of the superior nuchal line of the occipital bone and the mastoid process of the temporal bone.

Insertion: Inserts into the epicranial aponeurosis (galea aponeurotica).

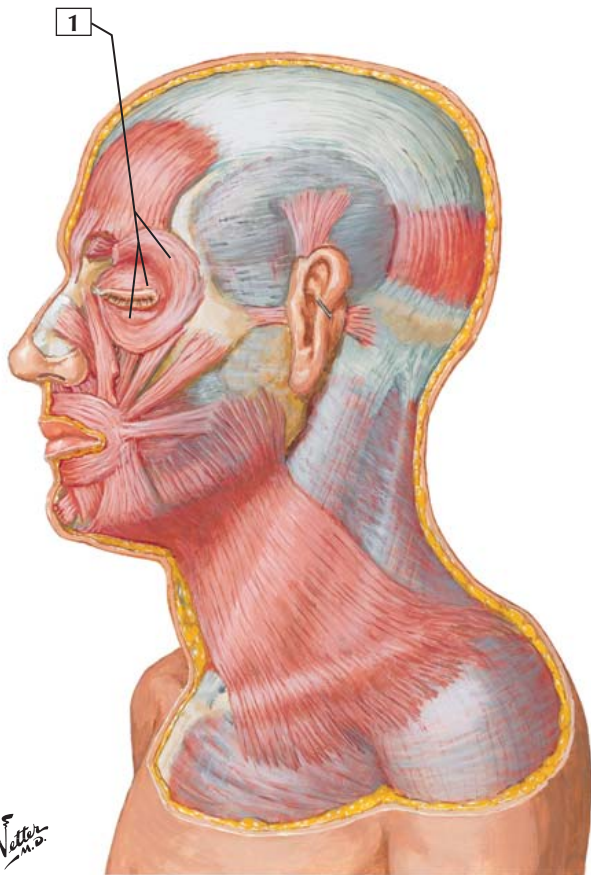
Action: The occipital and frontal bellies of the epicranial muscle act together to draw back the scalp. This action raises the eyebrows and wrinkles the forehead.

Innervation: Terminal branches of the facial nerve.

Comment: The extensive aponeurosis called the galea aponeurotica connects the frontal belly and occipital belly of the epicranial muscle.

As a muscle of facial expression, this cutaneous muscle lies within the layers of the superficial fascia. These muscles vary from person to person, and they often blend together.

Clinical: All of the muscles of facial expression are derived embryologically from the second pharyngeal (branchial) arch and are innervated by the terminal branches of the facial nerve (CN VII). Acute, unilateral facial palsy is the most common cause of facial muscle weakness and is called Bell's palsy. In Bell's palsy, paralysis of the occipitalis portion of the epicranium muscle would result in an inability to raise one's eyebrows or wrinkle the skin of the forehead.



1. Orbicularis oculi

Origin: Arises from the nasal portion of the frontal bone, the frontal process of the maxilla, the lacrimal bone, and the medial palpebral ligament.

Insertion: Attaches to the skin of the eyelids, surrounds the bony orbit, and inserts into the superior and inferior tarsi medial to the lacrimal puncta.

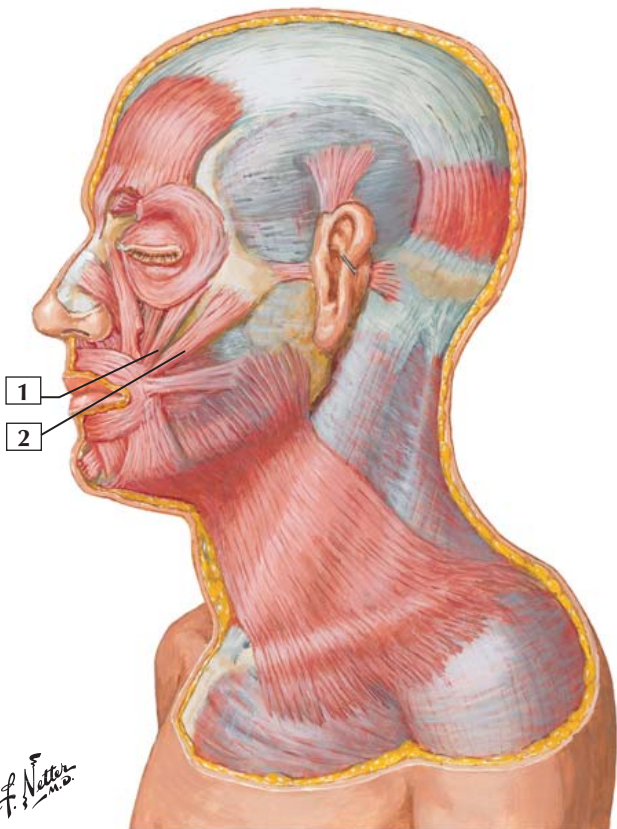
Action: This muscle is a sphincter that closes the eyelids. Its palpebral portion closes the lids gently, as in blinking. The orbital portion closes the eyelids more forcibly.

Innervation: Terminal branches of the facial nerve.

Comment: The orbicularis oculi has 3 parts: an orbital part, which is thicker and surrounds the orbital margin; a palpebral part, which is thin and lies in the eyelids; and a lacrimal part.

As a muscle of facial expression, this cutaneous muscle lies within the layers of the superficial fascia.

Clinical: All of the muscles of facial expression are derived embryologically from the second pharyngeal (branchial) arch and are innervated by the terminal branches of the facial nerve (CN VII). Acute, unilateral facial palsy is the most common cause of facial muscle weakness and is called Bell's palsy. In Bell's palsy, paralysis of the orbicularis oculi would result in an inability to wink or close the eyelid ipsilaterally with the potential for damage to the cornea because the tear film would not be evenly distributed across the cornea's surface.



WWW.YAZDANPRESS.COM

Zygomaticus Major and Zygomaticus Minor

1. Zygomaticus minor
2. Zygomaticus major

Origin: The zygomaticus major and minor arise from the zygomatic bone.

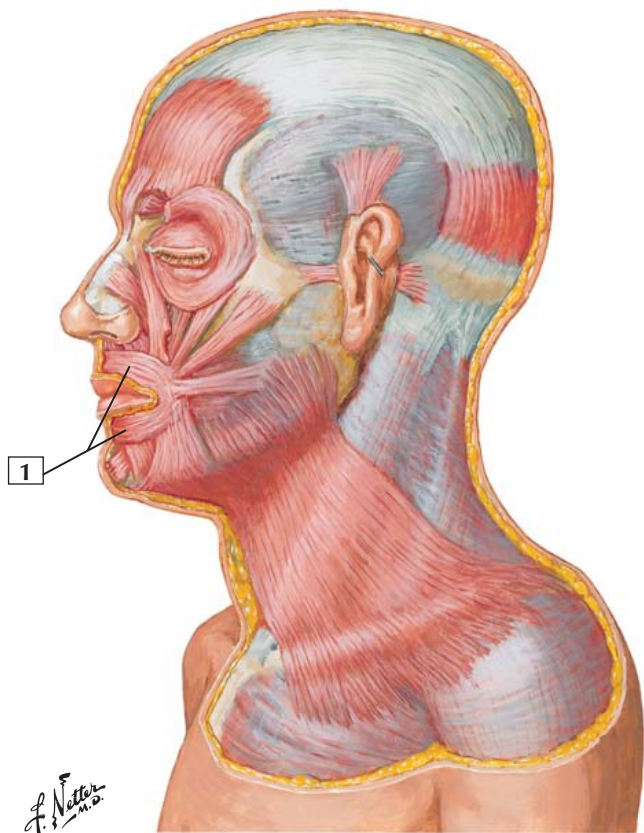
Insertion: The zygomaticus major is inserted into the angle of the mouth, where its fibers blend with those of the levator and depressor anguli oris muscles and with the orbicularis oris. The zygomaticus minor is inserted into the upper lip.

Action: The zygomaticus major draws the angle of the mouth upward and backward, as in laughing. The zygomaticus minor forms part of the nasolabial furrow; it deepens this furrow during an expression of contempt.

Innervation: Terminal branches of the facial nerve.

Comment: As muscles of facial expression, these cutaneous muscles lie within the layers of the superficial fascia. These muscles vary from person to person, and they often blend together.

Clinical: All of the muscles of facial expression are derived embryologically from the second pharyngeal (branchial) arch and are innervated by the terminal branches of the facial nerve (CN VII). Acute, unilateral facial palsy is the most common cause of facial muscle weakness and is called Bell's palsy. In Bell's palsy, paralysis of the zygomaticus major and minor would result in an inability to smile ipsilaterally and, with the face at rest, the ipsilateral nasolabial furrow would be less prominent (flattened).



1. Orbicularis oris

Origin: Fibers arise near the median plane of the maxilla above and from the mandible below.

Insertion: Fibers insert into the skin of the lips and into the mucous membrane beneath the lip.

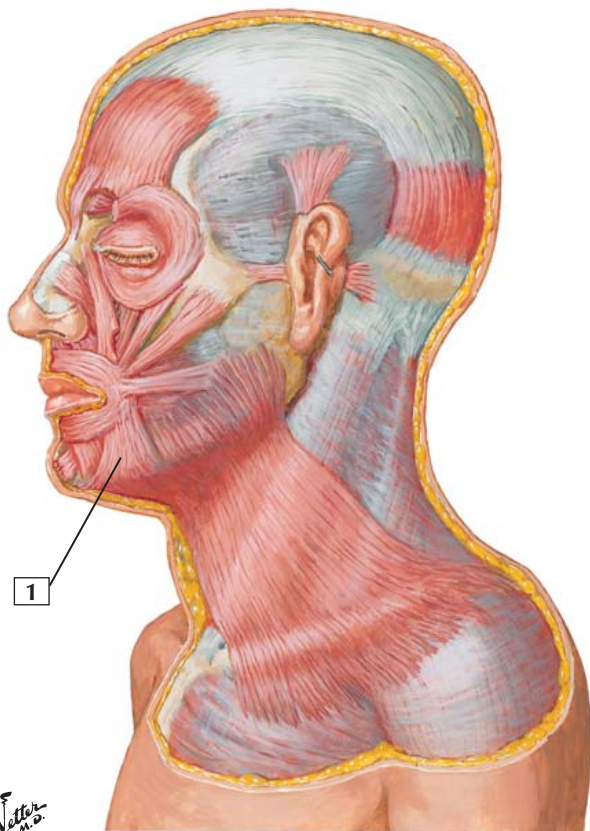
Action: This muscle acts primarily to close the lips. Its deep and oblique fibers pull the lips toward the teeth and alveolar arches. When all of its fibers act together, they can protrude the lips.

Innervation: Terminal branches of the facial nerve.

Comment: A major portion of this muscle is derived from the buccinator and blends with other facial muscles around the oral cavity. This muscle is especially important in speech because it alters the shape of the mouth.

As a muscle of facial expression, this cutaneous muscle lies within the layers of the superficial fascia.

Clinical: All of the muscles of facial expression are derived embryologically from the second pharyngeal (branchial) arch and are innervated by the terminal branches of the facial nerve (CN VII). Acute, unilateral facial palsy is the most common cause of facial muscle weakness and is called Bell's palsy. In Bell's palsy, paralysis of the orbicularis oris would result in an inability to ipsilaterally purse the lips, as in kissing someone, or protrude the lips.



*F. Netter
M.D.*

1. Depressor anguli oris

Origin: Arises from the oblique line of the mandible.

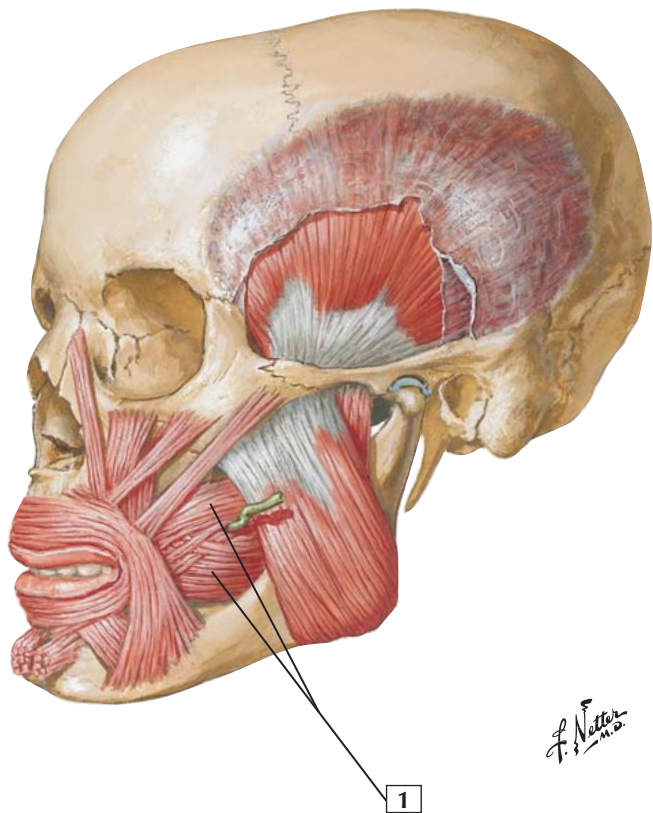
Insertion: Inserts into the angle of the mouth.

Action: Depresses the angle of the mouth and is an antagonist of the levator anguli oris and zygomaticus major.

Innervation: Terminal branches of the facial nerve.

Comment: As a muscle of facial expression, this cutaneous muscle lies within the layers of the superficial fascia. These muscles vary from person to person, and they often blend together.

Clinical: All of the muscles of facial expression are derived embryologically from the second pharyngeal (branchial) arch and are innervated by the terminal branches of the facial nerve (CN VII). Acute, unilateral facial palsy is the most common cause of facial muscle weakness and is called Bell's palsy. In Bell's palsy, paralysis of the depressor anguli oris would result in an inability to ipsilaterally draw the corners of the mouth downward.



*F. Netter
M.D.*

1. Buccinator

Origin: Arises from the mandible, pterygomandibular raphe, and alveolar processes of the maxilla and mandible.

Insertion: Attaches to the angle of the mouth.

Action: Contraction of this muscle presses the cheek against the molar teeth and aids in chewing. This muscle also can expel air from the mouth, as when a musician plays a woodwind or brass instrument.

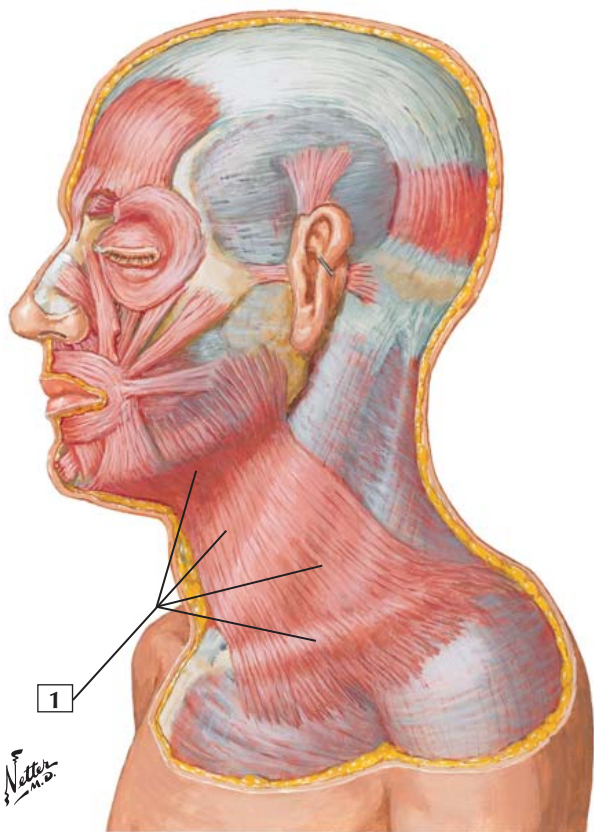
Innervation: Terminal branches of the facial nerve.

Comment: By pressing the cheek against the teeth, the buccinator holds food between the molars. When the muscle contracts too forcefully during chewing, the teeth bite the cheek.

The term *buccinator* is Latin for “trumpet player.” This muscle may be well developed in a trumpet player. The buccinator is a muscle of facial expression.

Fibers of this muscle blend with other muscles around the mouth.

Clinical: All of the muscles of facial expression are derived embryologically from the second pharyngeal (branchial) arch and are innervated by the terminal branches of the facial nerve (CN VII). Acute, unilateral facial palsy is the most common cause of facial muscle weakness and is called Bell’s palsy. In Bell’s palsy, paralysis of the buccinator muscle would result in an inability to ipsilaterally suck one’s cheek inward.





1. Platysma

Origin: Arises from the superficial fascia covering the superior portions of the pectoralis major and deltoid muscles.

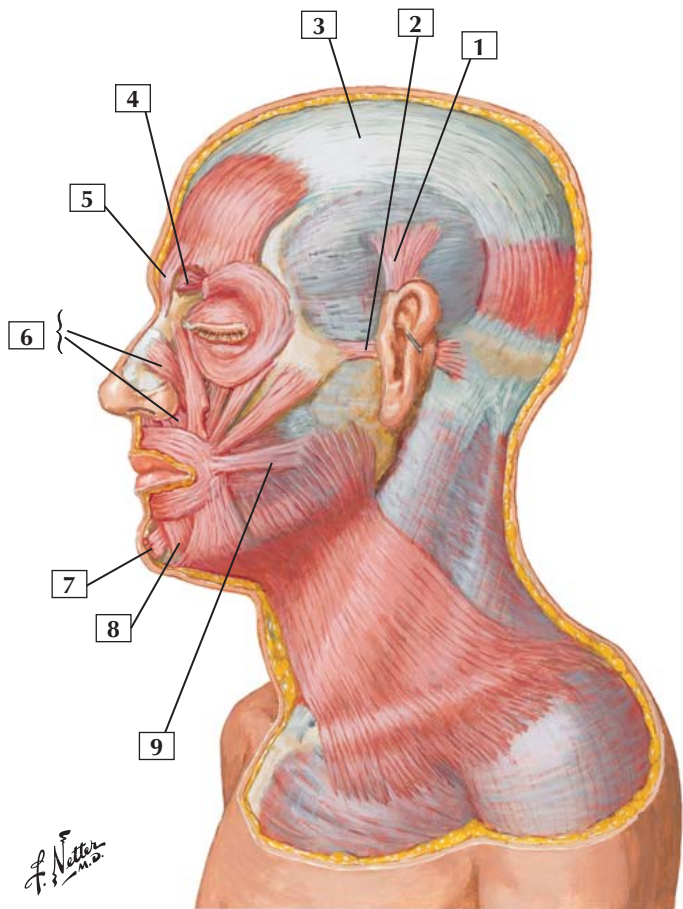
Insertion: Ascends over the clavicle and is directed medially to insert into the mandible below the oblique line. Other portions of the muscle insert into the skin and subcutaneous tissue of the lower portion of the face.

Action: Draws the lower lip and corner of the mouth inferolaterally and partially opens the mouth, as during an expression of surprise. When all the fibers act together, the skin over the clavicle and lower neck is wrinkled and drawn upward toward the mandible.

Innervation: Terminal branches of the facial nerve.

Comment: As a muscle of facial expression, this cutaneous muscle lies within the layers of the superficial fascia.

Clinical: All of the muscles of facial expression are derived embryologically from the second pharyngeal (branchial) arch and are innervated by the terminal branches of the facial nerve (CN VII). Acute, unilateral facial palsy is the most common cause of facial muscle weakness and is called Bell's palsy. In Bell's palsy, paralysis of the platysma muscle would result in an inability to ipsilaterally draw the corner of the lip downward and tense the skin of the neck between the clavicle and the mandible.



Muscles of Facial Expression: Lateral View

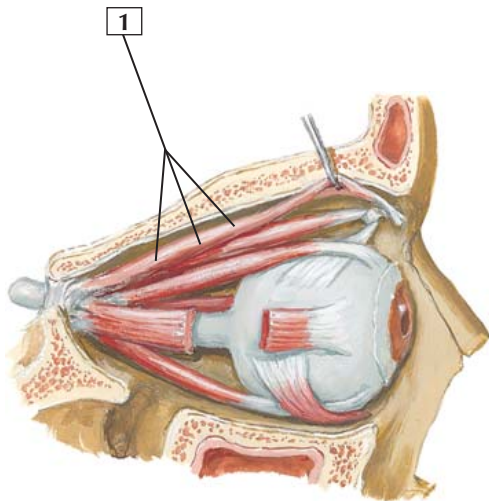
1. Auricularis superior
2. Auricularis anterior
3. Epicranial aponeurosis (galea aponeurotica)
4. Corrugator supercilii (frontalis and orbicularis oculi, partially cut away)
5. Procerus
6. Nasalis (Transverse part; Alar part)
7. Mentalis
8. Depressor labii inferioris
9. Risorius

Comment: This lateral view shows additional muscles of facial expression. The muscles around the eyes, ears, nose, and mouth blend with muscles of the lips, chin, and cheek. All are innervated by terminal branches of the facial nerve.

As muscles of facial expression, these cutaneous muscles lie within the layers of the superficial fascia. They vary from person to person, and they often blend together.

All of the muscles of facial expression are derived embryologically from the 2nd pharyngeal (branchial) arch and are innervated by the facial nerve (CN VII).

Right lateral view



*F. Netter
M.D.*

1. Levator palpebrae superioris

Origin: Arises from the lesser wing of the sphenoid bone, anterior and superior to the optic canal.

Insertion: Attaches to the skin and tarsal plate of the upper eyelid.

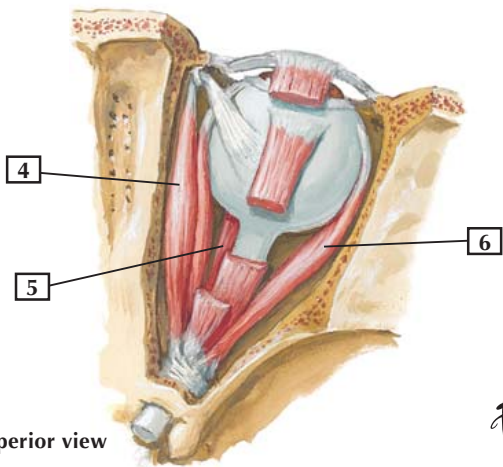
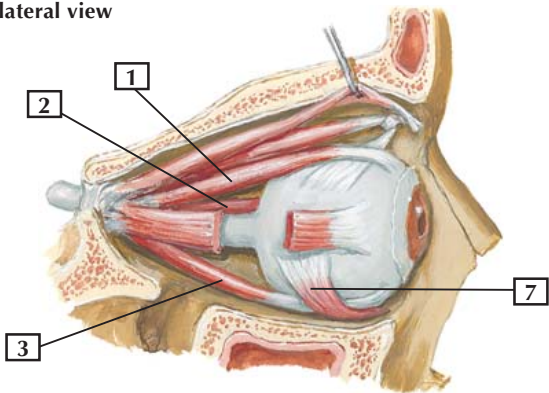
Action: Raises the upper eyelid.

Innervation: Oculomotor nerve (CN III). At the distal end of this muscle, near its attachment to the tarsal plate, is a small amount of smooth muscle called the superior tarsal muscle. The fibers of the superior tarsal muscle are supplied by postganglionic sympathetic fibers of the autonomic nervous system.

Comment: Because of the dual nature of this muscle (it is skeletal and has a small smooth muscle component), drooping of the upper eyelid can result from a nerve lesion affecting the oculomotor nerve or the sympathetic fibers. This drooping is called ptosis.

Clinical: Ptosis can result from nerve damage at two different sites. Damage to the oculomotor nerve (CN III) can result in paralysis of the levator palpebrae superioris muscle and significant ptosis. Damage anywhere along the sympathetic pathway from the upper thoracic sympathetic outflow to the head, the cervical sympathetic trunk, or the superior cervical ganglion and beyond can result in denervation of the small tarsal muscle (smooth muscle) that is found at the free distal margin of the levator palpebrae superioris muscle. This will result in a mild ptosis: the ipsilateral upper eyelid droops, but only slightly.

Right lateral view



Superior view

F. Netter M.D.

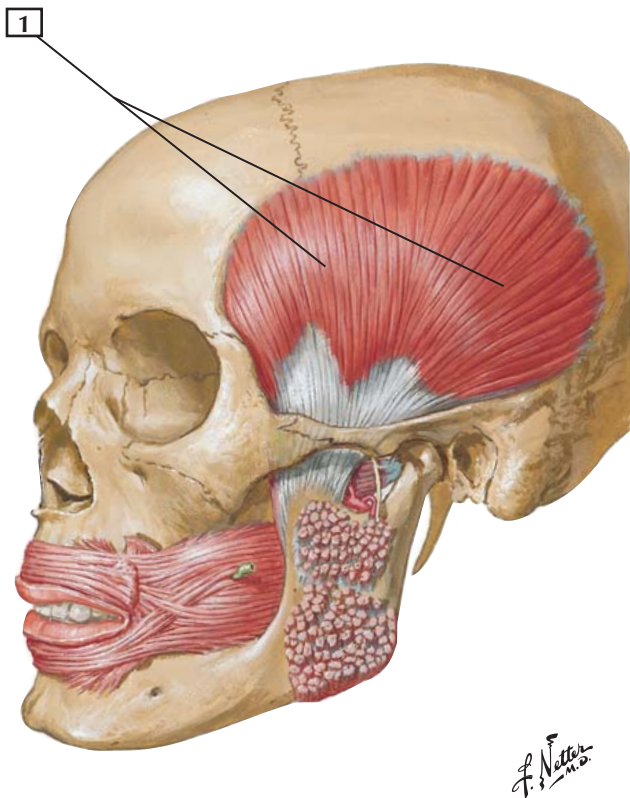
1. Superior rectus
2. Medial rectus
3. Inferior rectus
4. Superior oblique
5. Inferior rectus
6. Lateral rectus
7. Inferior oblique

Origin: The 4 rectus muscles and the superior oblique arise from a common tendinous ring (anulus of Zinn) on the body of the sphenoid bone. The inferior oblique arises from the floor of the orbit.

Insertion: The 4 rectus muscles insert into the sclera, just posterior to the cornea. The superior oblique muscle passes forward, and its tendon passes through a fibrous ring (trochlea) and inserts into the sclera deep to the superior rectus muscle. The inferior oblique inserts into the sclera deep to the lateral rectus muscle.

Actions: In clinical testing, when the eye is abducted, the superior rectus elevates the globe and the inferior rectus depresses it. When the eye is adducted, the superior oblique depresses the globe and the inferior oblique elevates it. The medial rectus is a pure adductor, whereas the lateral rectus is a pure abductor. The anatomic actions differ from the actions tested for clinical evaluation of the muscles.

Innervation: The lateral rectus is innervated by the abducens nerve (CN VI); the superior oblique is innervated by the trochlear nerve (CN IV). All the other rectus muscles and the inferior oblique are innervated by the oculomotor nerve (CN III).



1. Temporalis

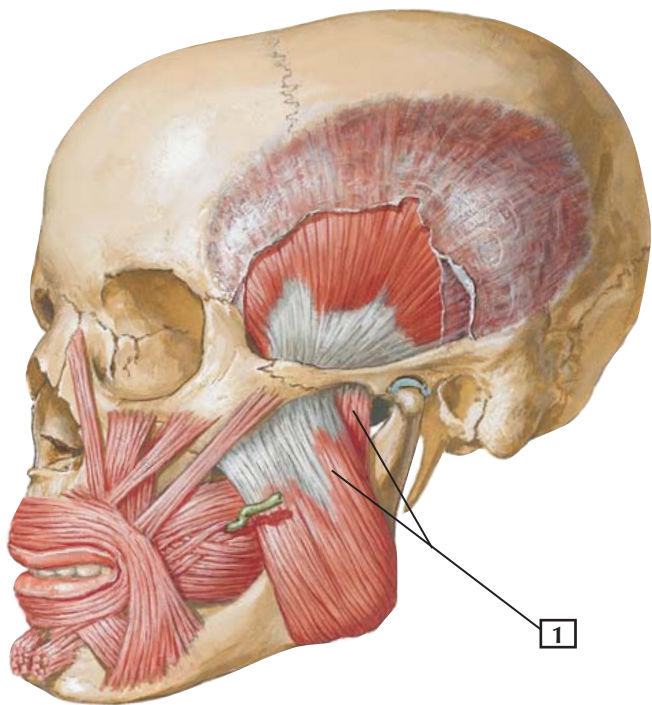
Origin: Floor of the temporal fossa and the deep surface of the temporal fascia.

Insertion: Attaches to the tip and medial surface of the coronoid process and anterior border of the ramus of the mandible.

Action: This muscle elevates the mandible and closes the jaws. Its posterior fibers retract the mandible (retrusion).

Innervation: Mandibular division of the trigeminal nerve.

Comment: The temporalis is 1 of the 4 muscles of mastication. It is a broad, radiating muscle whose contractions can be seen during chewing. The muscles of mastication are derived embryologically from the 1st pharyngeal (branchial) arch and are innervated by the mandibular division of the trigeminal nerve (CN V₃).



1. Masseter

Origin: Arises from the inferior border and medial surface of the zygomatic arch.

Insertion: Attaches to the lateral surface of the mandible and lateral surface of the coronoid process.

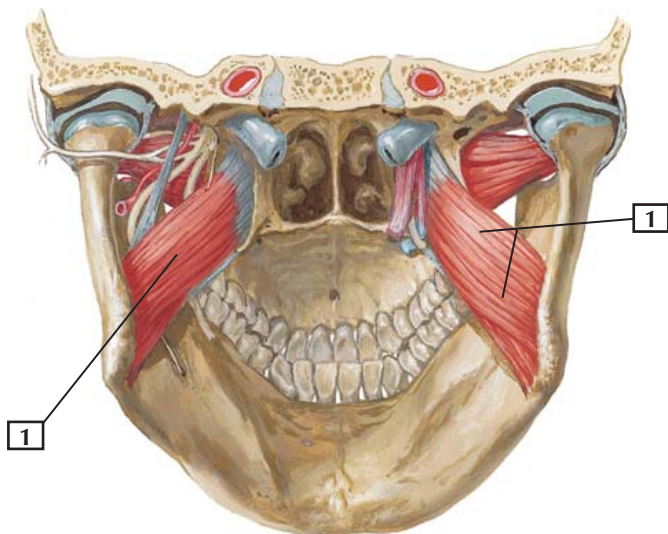
Action: Closes the jaws by elevating the mandible.

Innervation: Mandibular division of the trigeminal nerve.

Comment: The masseter muscle is 1 of the 4 muscles of mastication. Some of its fibers also may protrude the mandible, and its deep fibers retract the mandible.

Clinical: The muscles of mastication are derived embryologically from the 1st pharyngeal (branchial) arch and are innervated by the mandibular division of the trigeminal nerve (CN V₃). The hearty spore of *Clostridium tetani* is commonly found in soil, dust, and feces and can enter the body through wounds, blisters, burns, skin ulcers, insect bites, and surgical procedures. If the individual is infected and unvaccinated, the toxin from the bacteria can destroy the inhibitory neurons of the brainstem and spinal cord and cause nuchal rigidity, trismus (lockjaw, a spasm of the masseter muscle), dysphagia, laryngospasm, and acute muscle spasms that can lead to death.

Posterior view



*F. Netter
M.D.*

1. Medial pterygoid

Origin: This muscle arises from 2 slips. Its deep head arises from the medial surface of the lateral pterygoid plate and pyramidal process of the palatine bone. Its superficial head arises from the tuberosity of the maxilla.

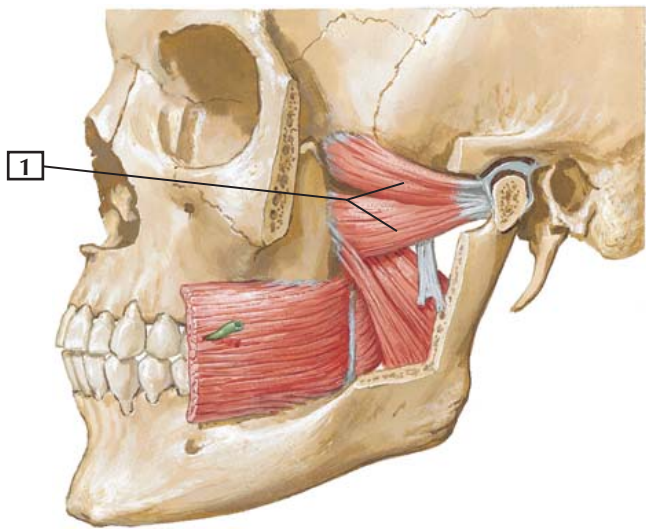
Insertion: The muscle fibers blend to attach to the medial surface of the ramus of the mandible, inferior to the mandibular foramen.

Action: Helps close the jaws by elevating the mandible. With the lateral pterygoids, the 2 medial pterygoids protrude the mandible. When 1 medial and 1 lateral pterygoid on the same side of the head act together, the mandible is protruded forward and to the opposite side. Alternating these movements moves the jaws from side to side in a grinding motion.

Innervation: Mandibular division of the trigeminal nerve.

Comment: The medial pterygoid is 1 of the 4 muscles of mastication. It acts with the temporalis and masseter muscles to close the jaws. The medial pterygoid and masseter muscles are important in biting, but all 3 muscles are necessary for biting and chewing with the molars.

The muscles of mastication are derived embryologically from the 1st pharyngeal (branchial) arch and are innervated by the mandibular division of the trigeminal nerve (CN V₃).



*F. Netter
M.D.*

1. Lateral pterygoid

Origin: This short, thick muscle arises by 2 heads. The superior head arises from the infratemporal surface and infratemporal crest of the greater wing of the sphenoid bone. The inferior head arises from the lateral surface of the lateral pterygoid plate.

Insertion: Its fibers converge to insert on the neck of the mandible, articular disc, and capsule of the temporomandibular joint.

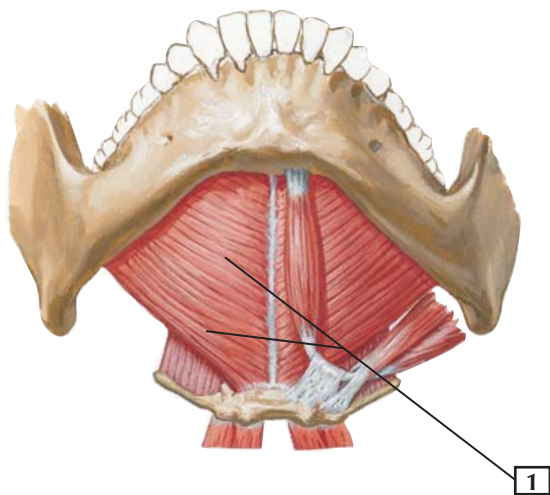
Action: Opens the mouth by drawing the condyle of the mandible and articular disc of the temporomandibular joint forward. With the medial pterygoid of the same side, the lateral pterygoid protrudes the mandible. The jaw is rotated to the opposite side, producing a grinding movement.

Innervation: Mandibular division of the trigeminal nerve.

Comment: The other 3 muscles of mastication help close the jaws, whereas the lateral pterygoid opens the jaws. At the beginning of this action, it is assisted by the mylohyoid, digastric, and geniohyoid muscles.

The muscles of mastication are derived embryologically from the 1st pharyngeal (branchial) arch and are innervated by the mandibular division of the trigeminal nerve (CN V₃).

Anteroinferior view



*F. Netter
M.D.*



1. Mylohyoid

Origin: Arises from the mylohyoid line of the mandible.

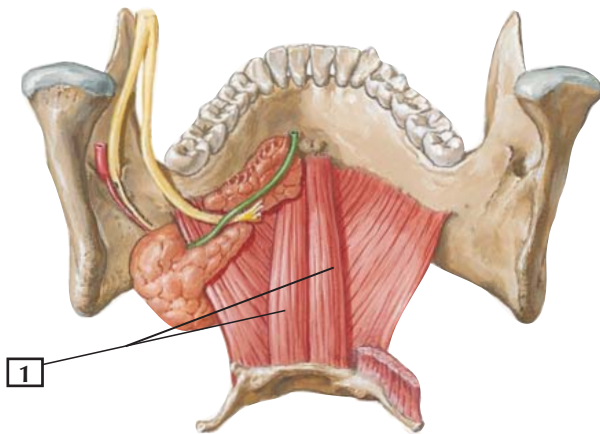
Insertion: Attaches to a median fibrous raphe and the body of the hyoid bone.

Action: Elevates the hyoid bone and raises the floor of the mouth during swallowing, pushing the tongue upward as in swallowing or protrusion of the tongue.

Innervation: By the mylohyoid nerve, a branch of the mandibular division of the trigeminal.

Comment: The mylohyoids also can help depress the mandible or open the mouth. They are active in mastication, swallowing, sucking, and blowing.

Posterosuperior view



*F. Netter
M.D.*

Geniohyoid

1. Geniohyoid

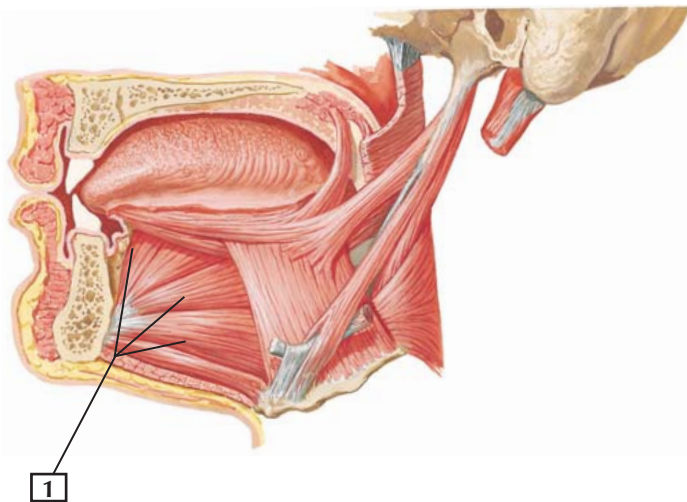
Origin: Inferior mental spine of mandible.

Insertion: Attaches to the body of the hyoid bone.

Action: Slightly elevates and draws the hyoid bone forward, shortening the floor of the mouth. When the hyoid bone remains fixed, this muscle also helps retract and depress the mandible.

Innervation: C1 via the hypoglossal nerve (CN XII).

Comment: The digastric, stylohyoid, mylohyoid, and geniohyoid muscles are considered “suprahyoid” muscles because they lie above the hyoid bone.



*F. Netter
M.D.*

1. Genioglossus

Origin: Arises from the superior part of the mental spine of the mandible.

Insertion: Dorsum of the tongue and body of the hyoid bone.

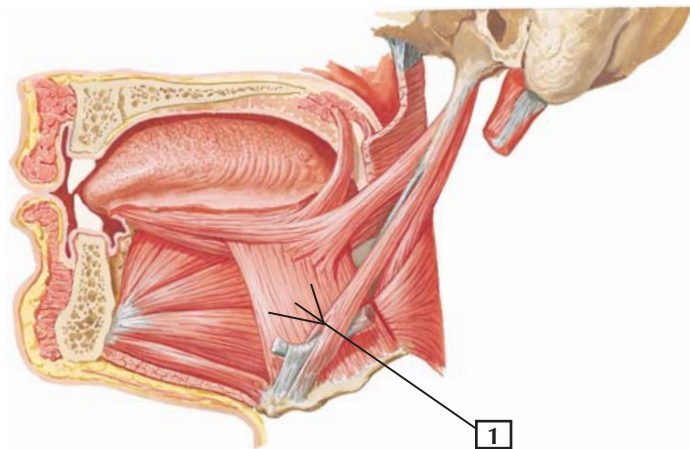
Action: Its central fibers depress the tongue. Its posterior fibers protrude the tongue, as in sticking the tongue out of the mouth.

Innervation: Hypoglossal nerve (CN XII).

Comment: The genioglossus is 1 of the 3 extrinsic muscles of the tongue. These extrinsic muscles move the tongue, whereas the intrinsic muscles change the tongue's shape.

All of the muscles with "glossus" in their name are innervated by the hypoglossal nerve *except* the palatoglossus muscle, which is not a tongue muscle but a muscle of the soft palate.

Clinical: One can easily test the hypoglossal nerve (CN XII) by asking the patient to "stick your tongue out." If ipsilateral damage to the hypoglossal nerve has occurred, the patient's tongue will deviate to the side of the lesion, with the tip of the tongue pointing ipsilaterally. This occurs because of the strong force of pull by the posterior fibers of the contralateral genioglossus, which is unopposed by the paralyzed ipsilateral fibers. This causes the tongue to protrude and then deviate beyond the midline to the unopposed side (side of the nerve lesion).



*F. Netter
M.D.*

1. Hyoglossus

Origin: Arises from the body and greater horn of the hyoid bone.

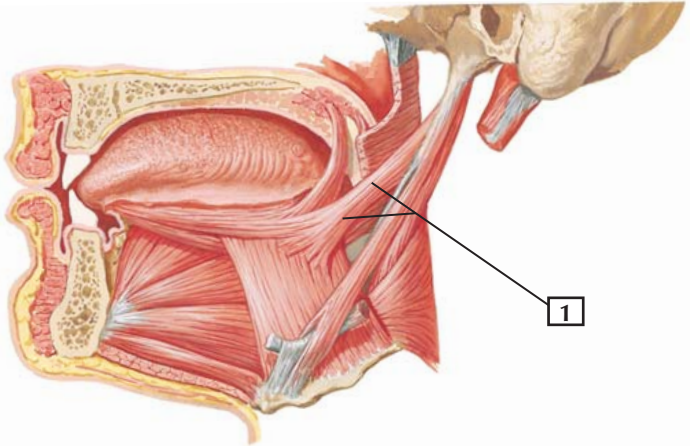
Insertion: Attaches to the lateral and dorsal surface of the tongue.

Action: Depresses, or pulls, the tongue into the floor of the mouth. Also retracts the tongue.

Innervation: Hypoglossal nerve (CN XII).

Comment: The hyoglossus is one of the tongue's extrinsic muscles, which alter the position of the tongue within the mouth. The intrinsic muscles of the tongue change the tongue's shape.

All of the muscles with "glossus" in their name are innervated by the hypoglossal nerve *except* the palatoglossus muscle, which is not a tongue muscle but a muscle of the soft palate.



*F. Netter
M.D.*

1. Styloglossus

Origin: Arises from the styloid process and stylohyoid ligament.

Insertion: Attaches to the lateral side of the tongue. Some fibers interdigitate with fibers of the hyoglossus muscle.

Action: Retracts the tongue and draws it up during swallowing.

Innervation: Hypoglossal nerve (CN XII).

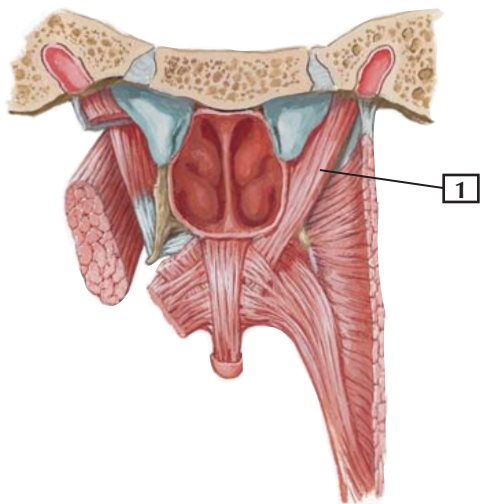
Comment: The styloglossus is 1 of the 3 extrinsic muscles of the tongue. All are innervated by the hypoglossal nerve.

All of the muscles with “glossus” in their name are innervated by the hypoglossal nerve *except* the palatoglossus muscle, which is not a tongue muscle but a muscle of the soft palate.

Three muscles arise from the styloid process: the styloglossus, the stylohyoid, and the stylopharyngeus muscles. Each is innervated by a different cranial nerve.

Clinical: The styloglossus is important in swallowing, because it pushes the bolus of chewed food up against the hard palate and backward into the oropharynx.

Posterior view



*F. Netter
M.D.*

1. Levator veli palatini

Origin: Arises from the cartilage of the auditory tube and the petrous portion of the temporal bone.

Insertion: Attaches to the palatine aponeurosis of the soft palate.

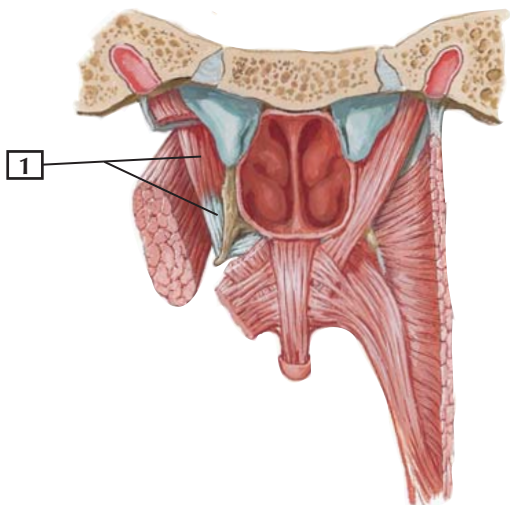
Action: Elevates the soft palate during swallowing and yawning.

Innervation: Vagus nerve (CN X).

Comment: After the soft palate has been tensed by the tensor veli muscle (which hooks around the pterygoid hamulus), the levator elevates the palate. Note the arrangement of these muscles in the figure (posterior view).

Clinical: The levator elevates the soft palate and can be tested clinically by asking a patient to say “ah.” By watching the soft palate elevate as this is done, one can look for even, symmetric elevation, indicating that the vagus nerve (CN X) is functioning properly on both sides. If there is damage to the vagus nerve on one side, the soft palate will deviate contralaterally, that is, to the normal functioning side and away from the abnormal side.

Posterior view



*F. Netter
M.D.*

1. Tensor veli palatini

Origin: Arises from the scaphoid fossa of the medial pterygoid plate, spine of the sphenoid bone, and cartilage of the auditory tube.

Insertion: Attaches to the palatine aponeurosis of the soft palate.

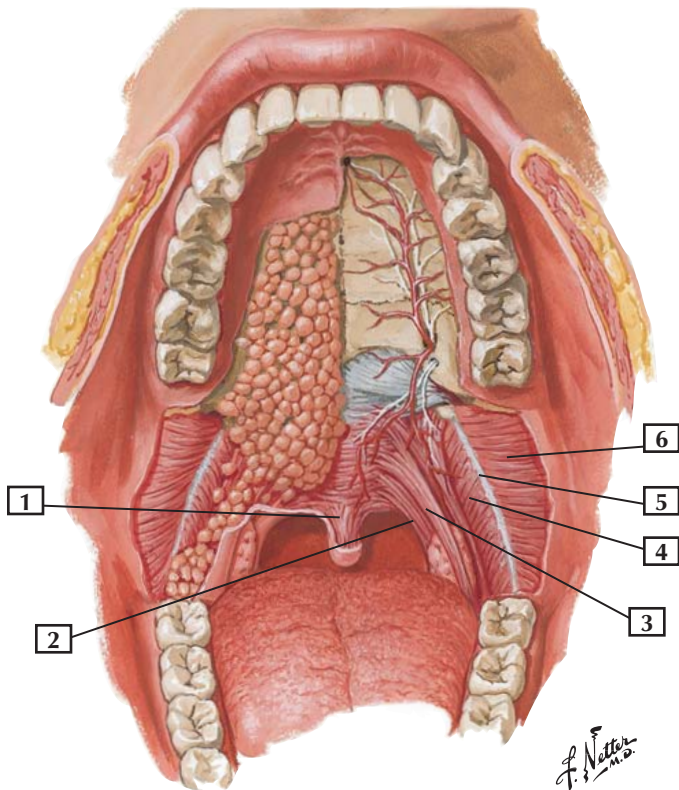
Action: Tenses the soft palate and, by contracting, opens the auditory tube during swallowing and yawning to equalize pressure in the middle ear.

Innervation: Mandibular division of the trigeminal nerve.

Comment: This muscle tenses the fibers of the soft palate so that the levator veli palatini muscle can act on them.

Clinical: The tensor not only tenses the soft palate during elevation by the levator veli palatini but also opens the auditory (pharyngotympanic, eustachian) tube during swallowing and yawning. This helps equalize the pressure in the middle ear and explains why chewing gum, swallowing, or yawning can relieve the pressure and pain in the middle ear when landing in an airplane.

Anterior view



1. Uvular muscle
2. Palatopharyngeus
3. Palatoglossus
4. Superior pharyngeal constrictor
5. Pterygomandibular raphe
6. Buccinator

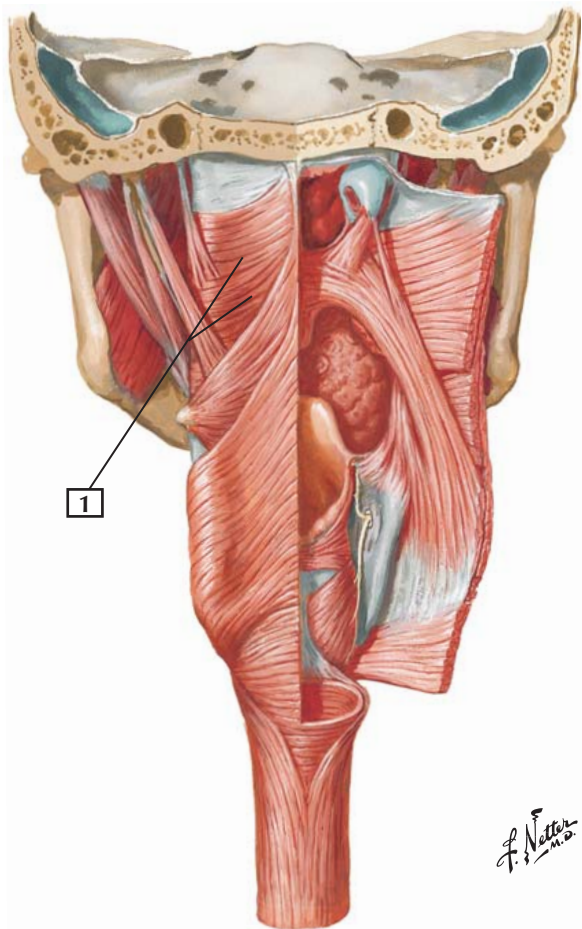
Comment: Interdigitating fibers of the levator veli palatini muscle make up most of the soft palate, along with the little uvular muscle.

The palatoglossal and palatopharyngeal arches contain small slips of muscle (with the same names as the arches) beneath their mucosal surfaces. These thin muscle slips are innervated by the vagus nerve. The palatine tonsil is nestled in the palatine fossa, between these 2 folds.

The buccinator muscle lies deep to the oral mucosa of the cheek and helps keep food between the molars. This muscle of facial expression is innervated by the facial nerve (CN VII).

Numerous minor salivary glands populate the mucosa lining the hard palate.

Clinical: If the facial nerve (CN VII) is damaged or dysfunctional, as in Bell's palsy, the buccinator muscle will be paralyzed and the patient will be unable to suck the cheeks inwardly. If the parasympathetic fibers of the facial nerve are damaged (they travel in the lingual nerve of CN V₃), 2 of the 3 major salivary glands will be denervated (the submandibular and sublingual glands), as will the numerous minor salivary glands, also supplied by facial parasympathetic nerves. Consequently, the oral mucosa will appear drier than normal.



1. Superior pharyngeal constrictor

Origin: This broad muscle arises from the pterygoid hamulus, pterygomandibular raphe, posterior portion of the mylohyoid line of the mandible, and side of the tongue.

Insertion: The muscles from each side meet and attach to the median raphe of the pharynx and pharyngeal tubercle of the occipital bone.

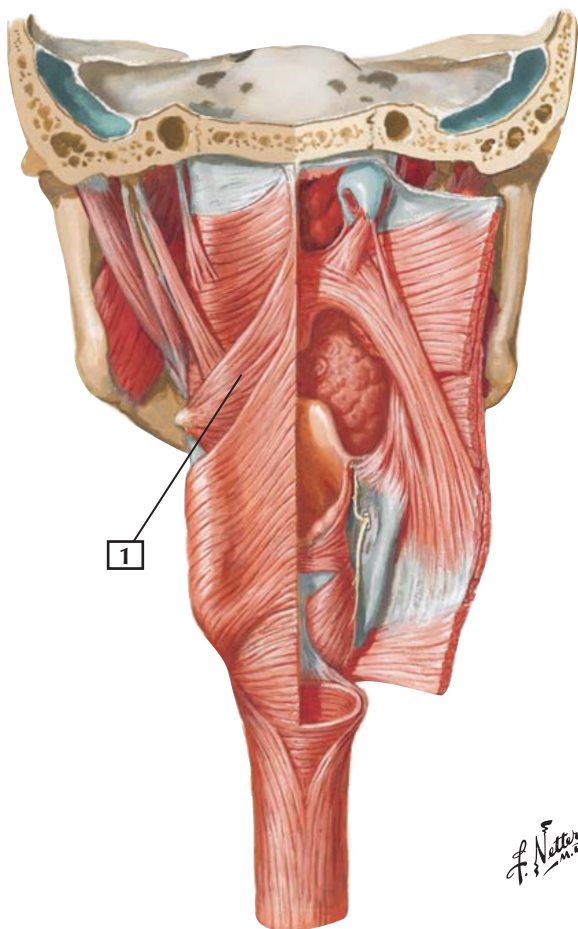
Action: Constricts the wall of the upper pharynx during swallowing.

Innervation: Pharyngeal plexus of the vagus nerve (CN X).

Comment: The 3 pharyngeal constrictors help move food down the pharynx and into the esophagus. To accomplish this, these muscles contract serially from superior to inferior to move a bolus of food from the oropharynx and laryngopharynx into the proximal esophagus.

The superior constrictor lies largely behind the mandible.

Clinical: Whereas the motor innervation of the pharyngeal constrictors is via the vagus nerve (CN X), the sensory innervation of all (the constrictor muscles and the mucosa lining the interior of the pharynx) but the most superior part of the pharynx is via the glossopharyngeal nerve (CN IX). Together, the fibers of CN IX and X form the pharyngeal plexus and function in concert with one another during swallowing.



F. Netter
M.D.

1. Middle pharyngeal constrictor

Origin: Arises from the stylohyoid ligament and the greater and lesser horns of the hyoid bone.

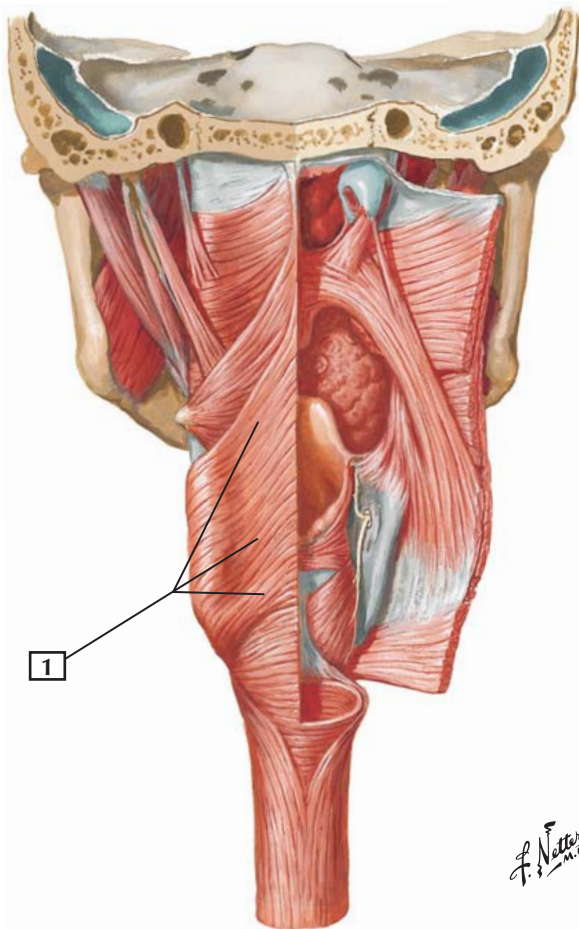
Insertion: The muscles from both sides wrap around and meet to attach to the median raphe of the pharynx.

Action: Constricts the wall of the pharynx during swallowing.

Innervation: Pharyngeal plexus of the vagus nerve (CN X).

Comment: The middle pharyngeal constrictor lies largely behind the hyoid bone. The fibers of the superior and middle pharyngeal constrictors often blend together, but the demarcation point can be seen where the stylopharyngeus muscle intervenes.

Clinical: Whereas the motor innervation of the pharyngeal constrictors is via the vagus nerve (CN X), the sensory innervation of all (the constrictor muscles and the mucosa lining the interior of the pharynx) but the most superior part of the pharynx is via the glossopharyngeal nerve (CN IX). Together, the fibers of CN IX and X form the pharyngeal plexus and function in concert with one another during swallowing.



*F. Netter
M.D.*

1. Inferior pharyngeal constrictor

Origin: Arises from the oblique line of the thyroid cartilage and side of the cricoid cartilage.

Insertion: The 2 inferior pharyngeal constrictor muscles wrap posteriorly to meet and attach to the median raphe of the pharynx.

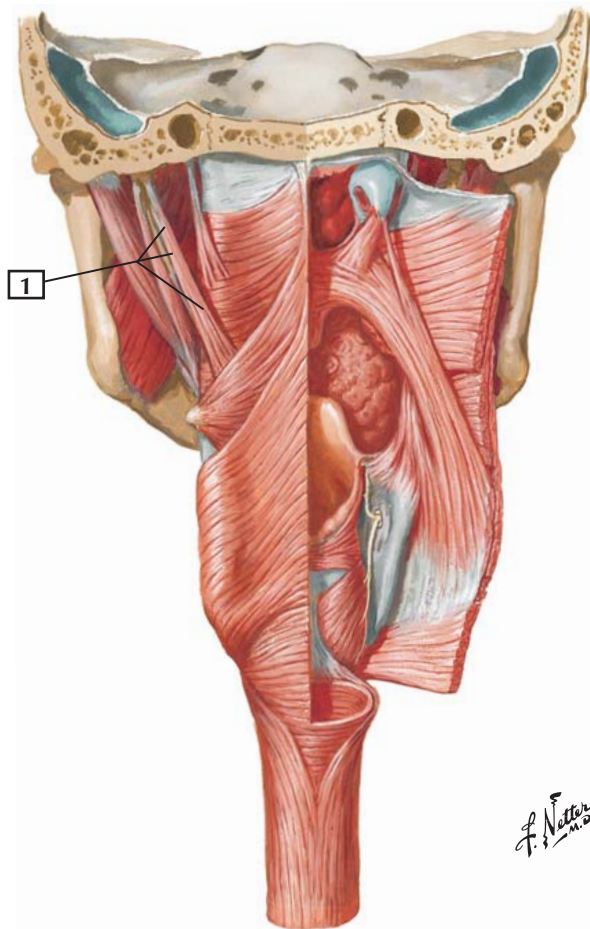
Action: Constricts the wall of the lower pharynx during swallowing.

Innervation: Pharyngeal plexus of the vagus nerve (CN X).

Comment: The inferior pharyngeal constrictor lies largely behind the thyroid and cricoid cartilages. Its lower end is referred to as the cricopharyngeal muscle, which is continuous with the esophageal muscle fibers.

Where the inferior constrictor attaches to the cricoid cartilage represents the narrowest portion of the pharynx.

Clinical: Whereas the motor innervation of the pharyngeal constrictors is via the vagus nerve (CN X), the sensory innervation of all (the constrictor muscles and the mucosa lining the interior of the pharynx) but the most superior part of the pharynx is via the glossopharyngeal nerve (CN IX). Together, the fibers of CN IX and X form the pharyngeal plexus and function in concert with one another during swallowing.



1. Stylopharyngeus

Origin: Arises from the styloid process of the temporal bone.

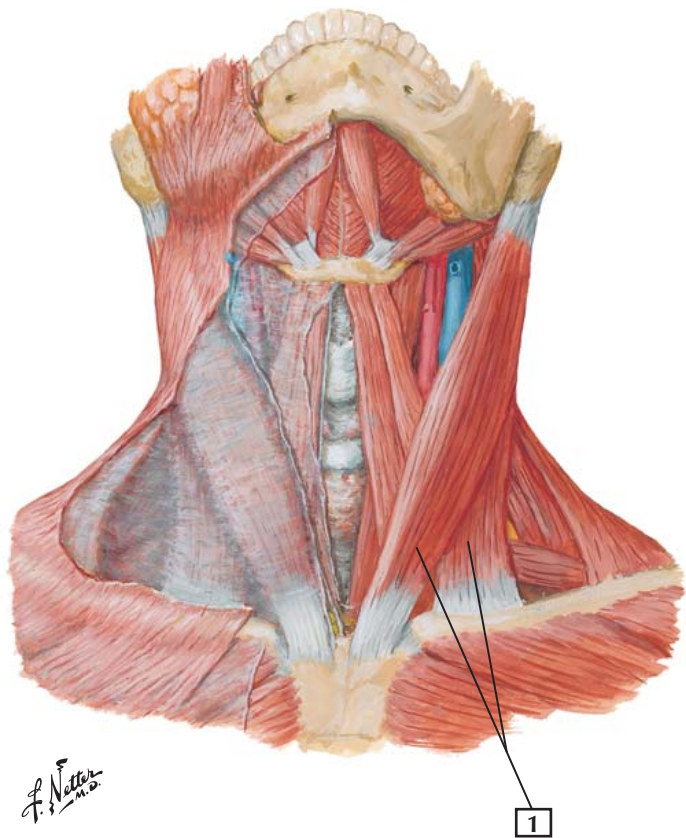
Insertion: Attaches to the posterior and superior margins of the thyroid cartilage.

Action: Elevates the pharynx and larynx during swallowing and speaking.

Innervation: Glossopharyngeal nerve (CN IX).

Comment: This muscle passes between the superior and middle pharyngeal constrictors. The stylopharyngeus is 1 of 3 muscles arising from the styloid process of the temporal bone (the others are the styloglossus and stylohyoid). Each muscle is innervated by a different cranial nerve and arises from a different embryonic branchial arch.

The stylopharyngeus arises embryologically from the 3rd pharyngeal (branchial) arch and is the only muscle innervated by the glossopharyngeal nerve.



1. Sternocleidomastoid

Origin (inferior attachment): This muscle has 2 heads of origin. The sternal head arises from the anterior surface of the manubrium of the sternum. The clavicular head arises from the superior surface of the medial 3rd of the clavicle.

Insertion (superior attachment): Attaches to the lateral surface of the mastoid process of the temporal bone and the lateral half of the superior nuchal line.

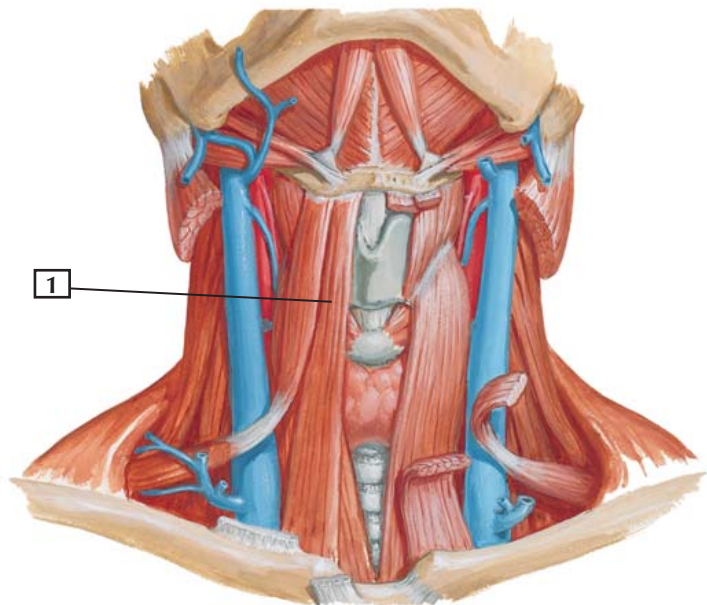
Action: Tilts the head to one side, flexes the neck, and rotates the neck so the face points superiorly to the opposite side. When the muscles of both sides act together, they flex the neck.

Innervation: Spinal root of the accessory nerve (CN XI and C2 and C3).

Comment: When the head is fixed, the 2 muscles acting together can help elevate the thorax during forced inspiration.

Clinical: The SCM is innervated by the spinal accessory nerve (CN XI), and this nerve is susceptible to injury where it crosses the posterior cervical triangle between the SCM and the trapezius. CN XI innervates both of these muscles.

Torticollis is a contraction of the cervical muscles that presents as a twisting of the neck such that the head is tilted toward the lesioned side (ipsilateral) and the face away from the lesioned side (contralateral). Commonly, the SCM is affected unilaterally by this congenital fibrous tissue tumor.



*F. Netter
M.D.*

Sternohyoid

1. Sternohyoid

Origin: Manubrium of the sternum and medial portion of the clavicle.

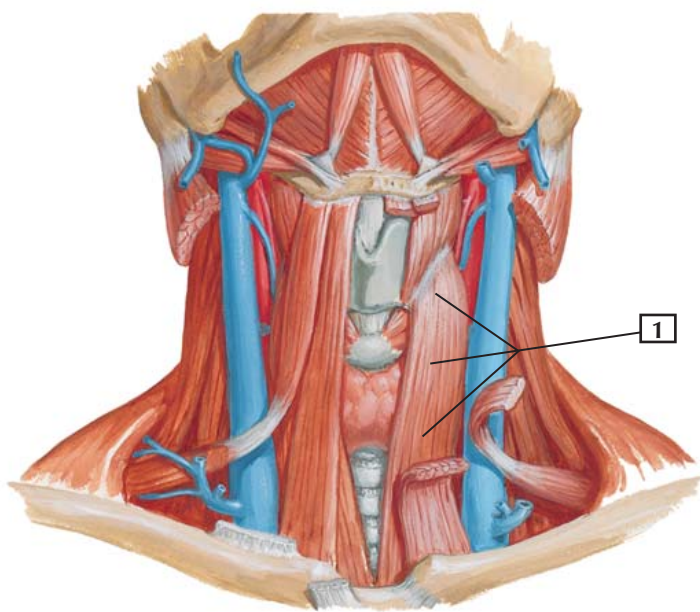
Insertion: Body of the hyoid bone.

Action: Depresses the hyoid bone after swallowing.

Innervation: C1, C2, and C3 from the ansa cervicalis.

Comment: The sternohyoid is part of the group of infrahyoid muscles. These muscles are often referred to as “strap” muscles because they are long and narrow.

Clinical: The infrahyoid or “strap” muscles are surrounded by an investing layer of cervical fascia that binds the neck muscles in a tight fascial sleeve. Swelling within this confined space can be painful and potentially damaging to adjacent structures. Immediately deep to this investing fascia is a “pretracheal space” anterior to the trachea and thyroid gland, which can provide a vertical conduit for the spread of infections.



1. Sternothyroid

Origin: Arises from the posterior surface of the manubrium of the sternum.

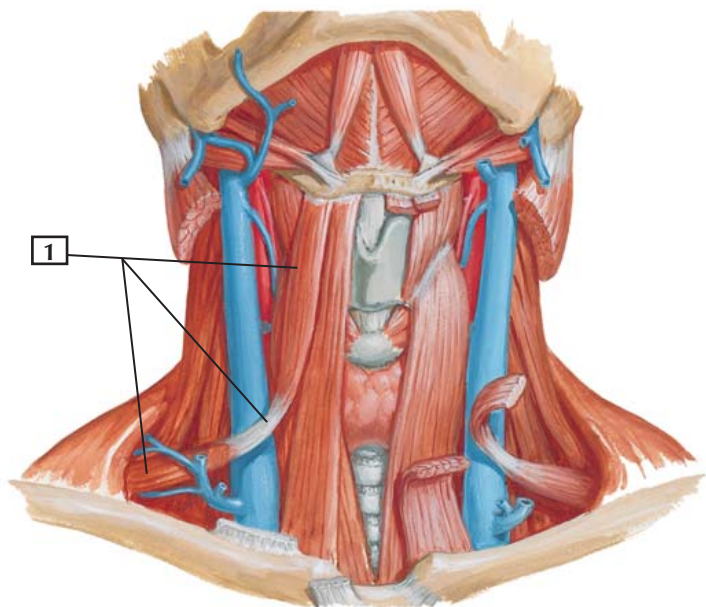
Insertion: Attaches to the oblique line of the thyroid cartilage.

Action: Depresses the larynx after the larynx has been elevated for swallowing.

Innervation: C2 and C3 from the ansa cervicalis.

Comment: The sternothyroid is part of the group of infrahyoid muscles. Because they are long and narrow, these muscles are often referred to as “strap” muscles.

Clinical: The infrahyoid or “strap” muscles are surrounded by an investing layer of cervical fascia that binds the neck muscles in a tight fascial sleeve. Swelling within this confined space can be painful and potentially damaging to adjacent structures. Immediately deep to this investing fascia is a “pretracheal space” anterior to the trachea and thyroid gland, which can provide a vertical conduit for the spread of infections.



1. Omohyoid

Origin: This muscle consists of an inferior and a superior belly. The inferior belly arises from the superior border of the scapula, near the suprascapular notch.

Insertion: The muscle is attached by a fibrous expansion to the clavicle and forms the superior belly, which inserts into the inferior border of the hyoid bone.

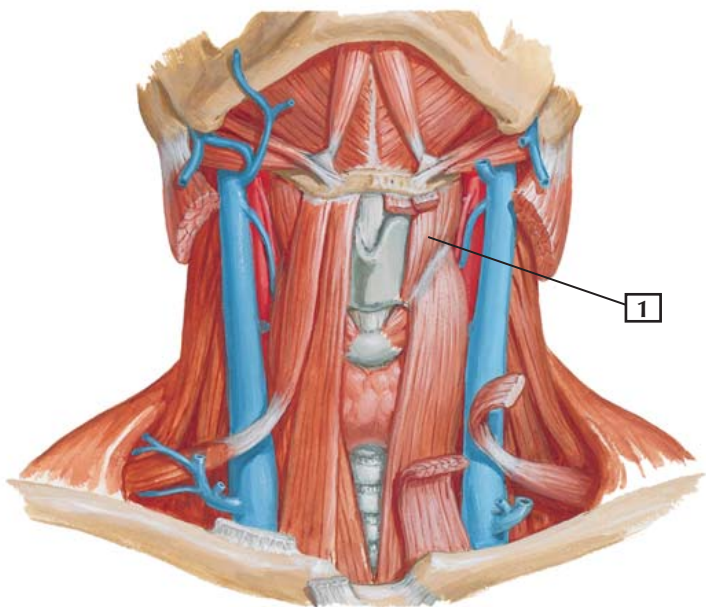
Action: Depresses the hyoid bone after the bone has been elevated. Also retracts and steadies the hyoid bone.

Innervation: C1, C2, and C3 by a branch of the ansa cervicalis.

Comment: The omohyoid acts with the other infrahyoid muscles to depress the larynx and hyoid bone after these structures have been elevated during swallowing.

The omohyoid is an unusual “strap” muscle because it arises from the scapula in the shoulder region.

Clinical: The infrahyoid or “strap” muscles are surrounded by an investing layer of cervical fascia that binds the neck muscles in a tight fascial sleeve. Swelling within this confined space can be painful and potentially damaging to adjacent structures. Immediately deep to this investing fascia is a “pretracheal space” anterior to the trachea and thyroid gland, which can provide a vertical conduit for the spread of infections.



*F. Netter
M.D.*

1. Thyrohyoid

Origin: Arises from the oblique line of the lamina of the thyroid cartilage.

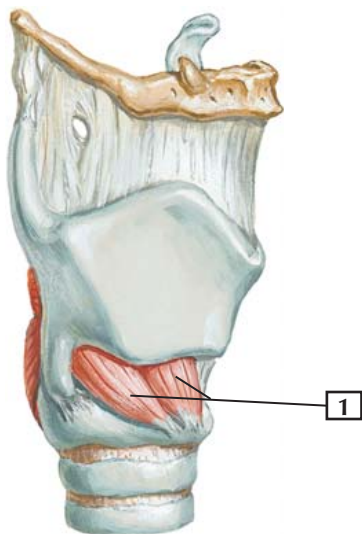
Insertion: Attaches to the inferior border of the body and the greater horn of the hyoid bone.

Action: Depresses the hyoid bone and, if the hyoid bone is fixed, draws the thyroid cartilage superiorly.

Innervation: C1 via the hypoglossal nerve (CN XII).

Comment: The thyrohyoid muscle is supplied by fibers of the 1st cervical nerve that happen to travel with the last, or hypoglossal, cranial nerve (CN XII).

The thyrohyoid muscle is also one of the infrahyoid, or “strap” muscles.



*F. Netter
M.D.*

1. Cricothyroid

Origin: Arises from the anterolateral part of the cricoid cartilage.

Insertion: Inserts into the inferior aspect and inferior horn of the thyroid cartilage.

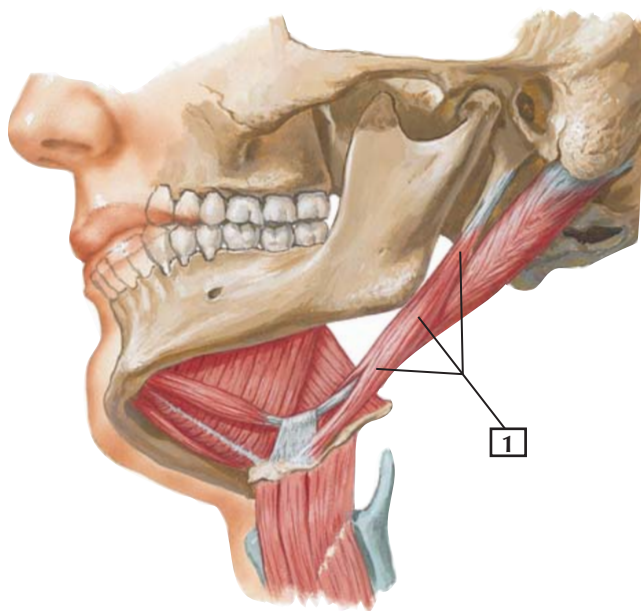
Action: Stretches and tenses the vocal folds.

Innervation: External branch of the superior laryngeal nerve of the vagus.

Comment: This muscle is innervated by the small, external branch of the superior laryngeal nerve of the vagus. Most of the superior laryngeal nerve continues as an internal branch that pierces the thyrohyoid membrane to provide sensory innervation above the vocal folds.

This muscle, similar to the other muscles of the larynx, is derived embryologically from the 4th through 6th pharyngeal (branchial) arches. All of these laryngeal muscles are innervated by the vagus nerve.

Clinical: Damage on one side to the superior laryngeal nerve, a branch of the vagus nerve (CN X), will paralyze the ipsilateral cricothyroid muscle. Consequently, the voice will be affected because the ipsilateral vocal fold cannot be stretched and tensed. Additionally, the ipsilateral laryngeal mucosa above the level of the vocal folds will be anesthetized, somewhat compromising the protective gag reflex that would normally keep foreign objects from being aspirated into the larynx.



*F. Netter
M.D.*

1. Stylohyoid

Origin: Arises from the styloid process of the temporal bone.

Insertion: Attaches to the body of the hyoid bone.

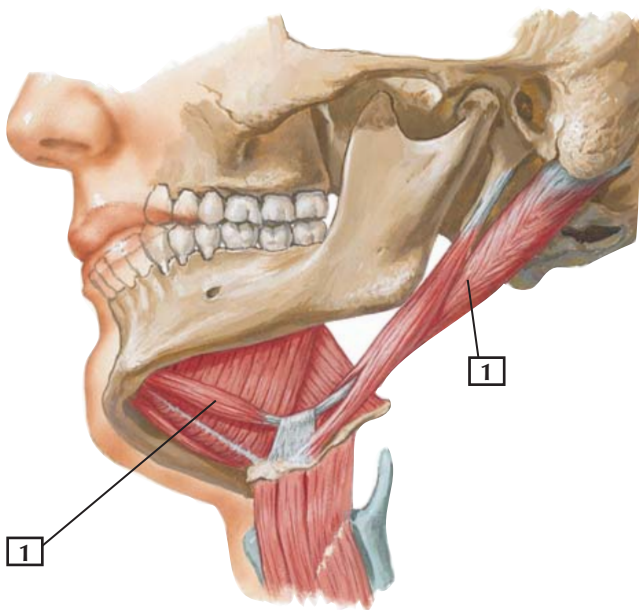
Action: Elevates and retracts the hyoid bone in an action that elongates the floor of the mouth.

Innervation: Facial nerve.

Comment: The stylohyoid muscle is perforated near its insertion by the tendon of the 2 bellies of the digastric muscle.

The stylohyoid is 1 of the 3 muscles arising from the styloid process, each innervated by a different cranial nerve.

Lateral, slightly inferior view



*F. Netter
M.D.*

1. Digastric

Origin: The digastric muscle consists of 2 bellies. The posterior belly is the longest, and it arises from the mastoid notch of the temporal bone. The anterior belly arises from the digastric fossa of the mandible.

Insertion: The 2 bellies end in an intermediate tendon that perforates the stylohyoid muscle and is connected to the body and greater horn of the hyoid bone.

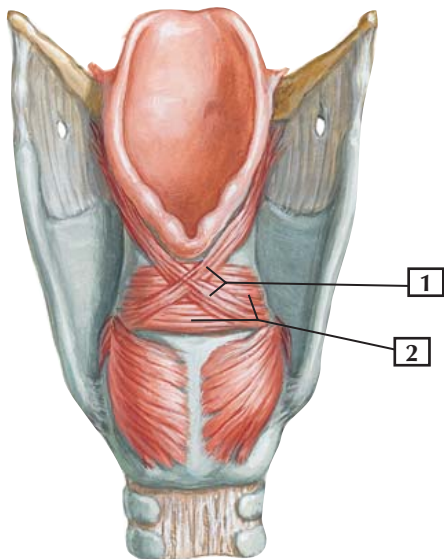
Action: Elevates the hyoid bone and, when both muscles act together, helps the lateral pterygoid muscles open the mouth by depressing the mandible.

Innervation: The anterior belly is innervated by the mylohyoid nerve, a branch of the mandibular division of the trigeminal nerve. The posterior belly is innervated by the facial nerve.

Comment: The 2 bellies of the digastric muscle are unique because they are innervated by different cranial nerves.

Clinical: The digastric muscles are important for opening the mouth symmetrically and are assisted by the lateral pterygoid muscles.

Posterior view



*F. Netter
M.D.*

WWW.YAZDANPRESS.COM

Oblique Arytenoids and Transverse Arytenoids

1. Oblique arytenoids
2. Transverse arytenoids

Origin: Arise from the arytenoid cartilages.

Insertion: Attach to the opposite arytenoid cartilage.

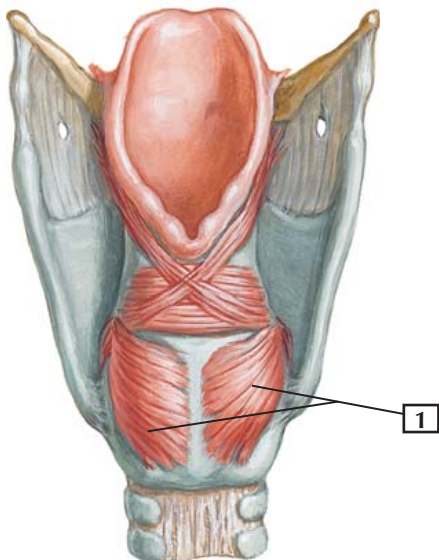
Action: Close the inlet of the larynx by adducting the arytenoid cartilages. This narrows the rima glottidis, the space between the vocal folds.

Innervation: Recurrent laryngeal nerve of the vagus.

Comment: Some muscle fibers of the oblique arytenoid continue superiorly as the aryepiglottic muscle.

Clinical: The vocal folds are controlled by the laryngeal muscles, all of which are innervated by the vagus nerve (CN X). During quiet respiration, the vocal folds are gently abducted to open the rima glottidis (space between the folds). In forced inspiration (taking a rapid, deep breath), the folds are maximally abducted by the posterior cricoarytenoid muscles, further enlarging the rima glottidis. During phonation, the folds are adducted and tensed to create a reed-like effect (similar to a reed instrument), causing vocal fold mucosal vibrations that produce sound that is then modified by the upper airway (pharynx, oral cavity, nose, paranasal sinuses). Closure of the rima glottidis occurs when holding your breath or when lifting something heavy (the Valsalva maneuver), and the folds are completely adducted.

Posterior view



*F. Netter
M.D.*

1. Posterior cricoarytenoid

Origin: Arises from the posterior surface of the laminae of the cricoid cartilage.

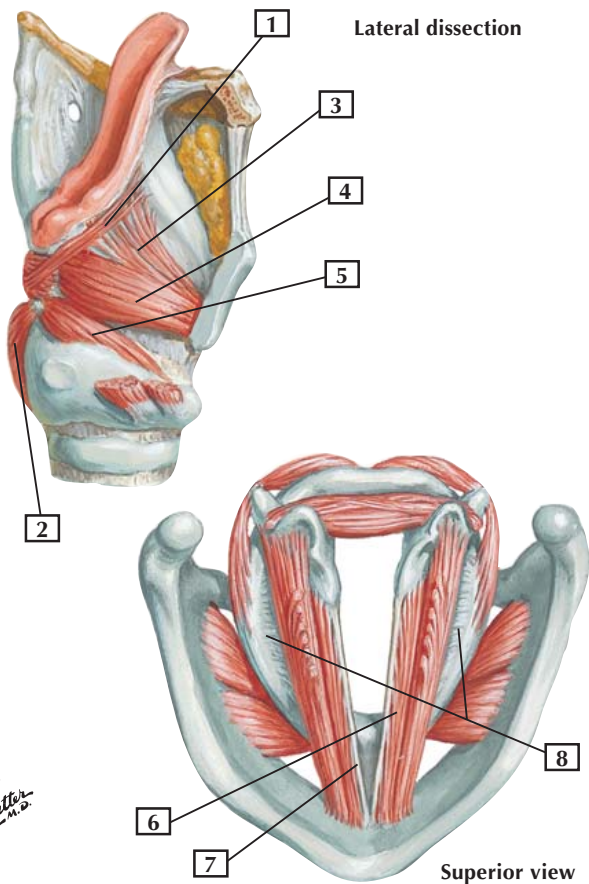
Insertion: Attaches to the muscular process of the arytenoid cartilage.

Action: Abducts the vocal folds and widens the rima glottidis, the space between the vocal folds.

Innervation: Recurrent (inferior) laryngeal nerve of the vagus.

Comment: The posterior cricoarytenoid muscles are extremely important because they are the only muscles that abduct the vocal folds.

Clinical: Damage to the recurrent laryngeal nerve during neck surgery (e.g., resection of the thyroid gland) can cause the vocal folds to adduct, causing hoarseness or closure of the rima glottidis, or both. This occurs because the posterior cricoarytenoid muscles are the only laryngeal muscles that abduct the vocal folds and keep the rima glottidis open.



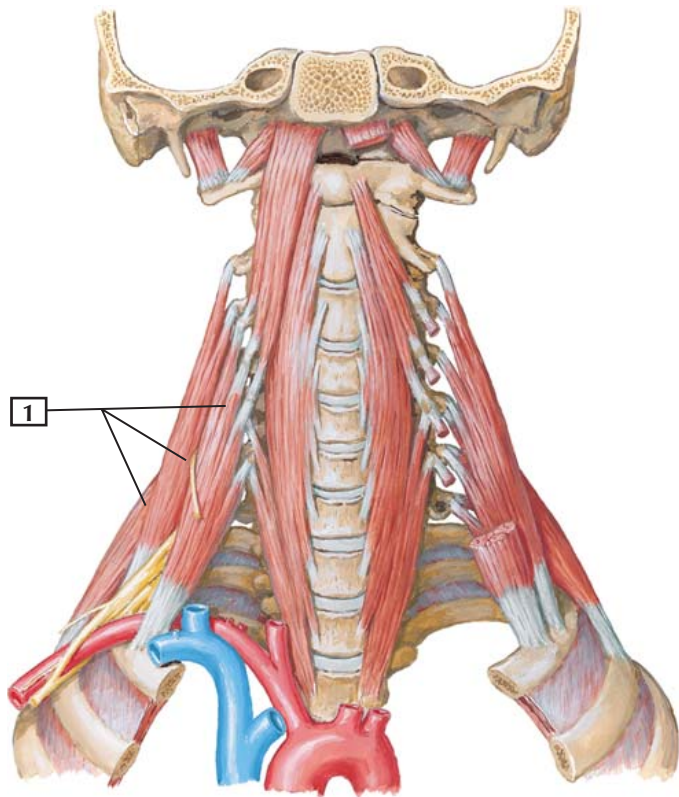
1. Aryepiglottic muscle
2. Posterior cricoarytenoid muscle
3. Thyroepiglottic muscle
4. Thyroarytenoid muscle
5. Lateral cricoarytenoid muscle
6. Vocalis muscle
7. Vocal ligament
8. Conus elasticus

Comment: The muscles of the larynx are small. They act on the laryngeal cartilages.

The most superior portion of the conus elasticus is thickened and forms the vocal ligament. The vocal folds themselves contain a small amount of muscle called the vocalis muscle, which is derived from some of the fibers of the thyroarytenoid muscle.

With the exception of the cricothyroid, all the intrinsic muscles of the larynx are innervated by the recurrent laryngeal nerve of the vagus. All of these muscles are derived embryologically from the 4th through 6th pharyngeal (branchial) arches.

Clinical: During quiet respiration, the vocal folds are gently abducted to open the rima glottidis. In forced inspiration, the folds are maximally abducted by the posterior cricoarytenoid muscles, further enlarging the rima glottidis. During phonation, the folds are adducted and tensed to create a reed-like effect, causing vocal fold mucosal vibrations that produce sound that is then modified by the upper airway (pharynx, oral cavity, tongue, lips, nose, paranasal sinuses). Closure of the rima glottidis occurs when holding your breath or when lifting something heavy, and the folds are completely adducted.



*F. Netter
M.D.*

1. Scalene muscles

Origin (superior attachment): The anterior scalene arises from the anterior tubercles of the transverse processes of C3-6 vertebrae. The middle and posterior scalenes arise from the posterior tubercles of the transverse processes of C2-7 (middle) and C4-6 (posterior).

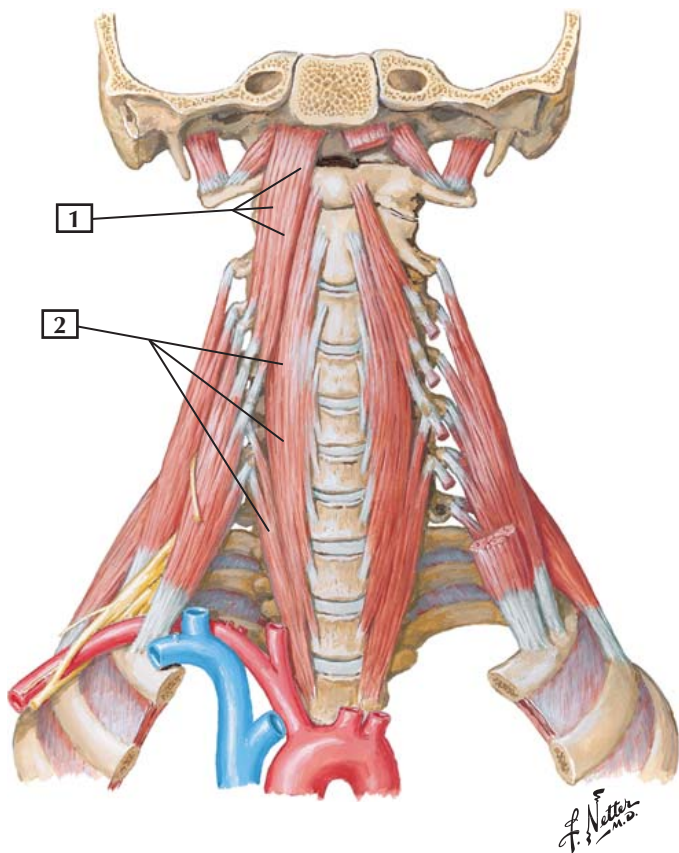
Insertion (inferior attachment): The anterior scalene attaches to the scalene tubercle of the 1st rib. The middle scalene attaches to the superior surface of the 1st rib. The posterior scalene attaches to the external border of the 2nd rib.

Action: The anterior and middle scalenes elevate the 1st rib. When that rib is fixed, they also flex the neck forward and laterally and rotate it to the opposite side. The posterior scalene raises the 2nd rib and flexes and slightly rotates the neck.

Innervation: The anterior scalene is innervated by C5-7 ventral rami; the middle scalene, by C3-8 ventral rami; and the posterior scalene, by ventral rami of C6-8.

Comment: The scalene muscles are often called lateral vertebral muscles. They form a large portion of the floor of the posterior cervical triangle.

Clinical: The scalene muscles are accessory muscles of respiration and help elevate the first two ribs during deep or labored breathing. They are crossed by the spinal accessory nerve (CN XI) as it passes between the sternocleidomastoid and trapezius muscles. The phrenic nerve (C3-5) is observed on the anterior surface of the anterior scalene muscle; it courses inferiorly toward the diaphragm, which it innervates. Trauma to the neck can damage these nerves.



1. Longus capitis
2. Longus colli

Origin: The longus capitis arises from the anterior tubercles of the C3-6 vertebral transverse processes. The longus colli arises from the bodies of the T1-3 vertebrae, the bodies of the C4-7 vertebrae, and transverse processes of the C3-6 vertebrae.

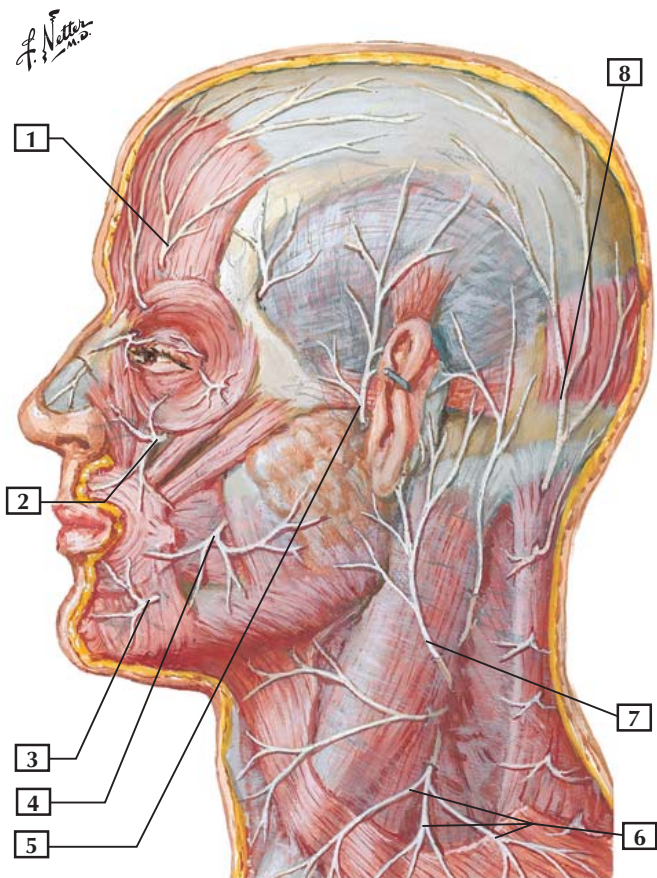
Insertion: The longus capitis attaches to the basilar portion of the occipital bone. The colli portion attaches to the anterior tubercle of the atlas (C1), the bodies of the C2-4 vertebrae, and transverse processes of the C5-6 vertebrae.

Action: Both muscles flex the neck, although the longus colli is weak. The longus colli also slightly rotates and laterally bends the neck.

Innervation: The longus capitis is supplied by the C1-3 ventral rami. The longus colli is supplied by the C2-6 ventral rami.

Comment: The longus capitis and longus colli lie in front of the cervical vertebrae and are often called prevertebral muscles. They help other muscles flex the cervical spine.

Clinical: These muscles and the scalene muscles comprise anterior muscle groups often lumped together as “prevertebral” muscles. They are encased in a strong fascial sleeve called the prevertebral fascia and do not tolerate swelling well because of this tight enclosure. Just anterior to the prevertebral fascia, where it covers the bodies of the cervical vertebrae, lies the retropharyngeal space (this space is between the buccopharyngeal fascia covering the posterior pharynx and esophagus and the prevertebral fascia). Infections in this vertical space may pass superiorly to the base of the skull or inferiorly into the posterior mediastinum of the thorax.

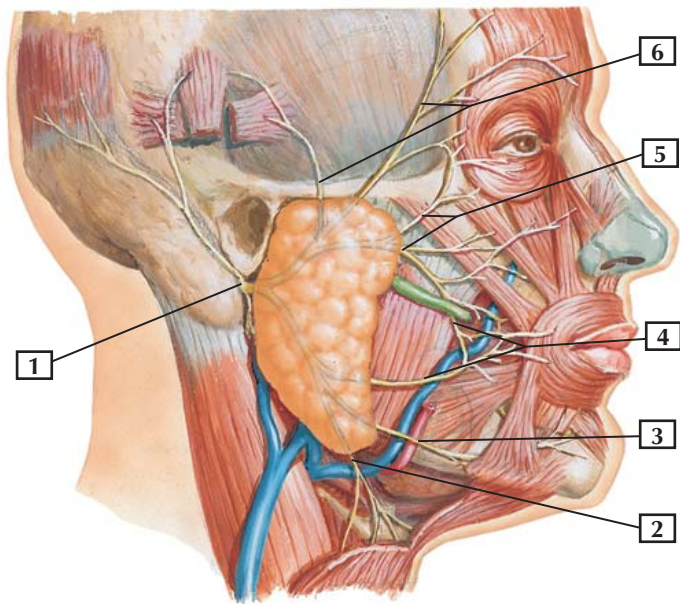


1. Supraorbital nerve
2. Infraorbital nerve
3. Mental nerve
4. Buccal nerve
5. Auriculotemporal nerve
6. Supraclavicular nerves (C3, C4)
7. Great auricular nerve (C2, C3)
8. Greater occipital nerve (C2)

Comment: Cutaneous innervation of the face is by the 3 divisions of the trigeminal nerve (CN V). The ophthalmic division is represented largely by the supraorbital and supratrochlear nerves. The maxillary division is represented by the infraorbital and zygomaticotemporal nerves. The mandibular division is represented largely by the mental, buccal, and auriculotemporal nerves.

The skin on the back of the scalp receives cutaneous innervation from the greater occipital nerve (dorsal ramus of C2); the skin on the back of the neck receives innervation from dorsal rami of cervical nerves.

The 1st cervical nerve (C1) has few if any sensory nerve fibers from the skin, so it is usually not represented on dermatome charts.



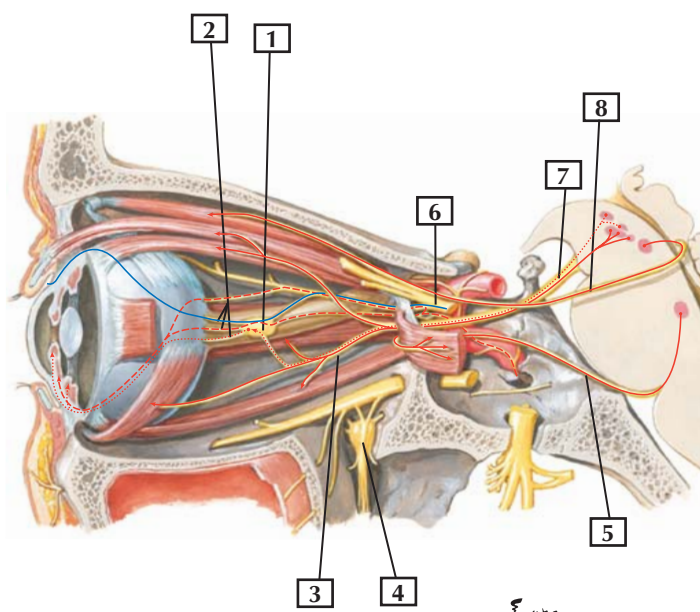
*F. Netter
M.D.*

1. Main trunk of facial nerve emerging from stylomastoid foramen
2. Cervical branch
3. Marginal mandibular branch
4. Buccal branches
5. Zygomatic branches
6. Temporal branches

Comment: The main trunk of the facial nerve exits through the stylomastoid foramen and, after giving off several small branches, courses through the substance of the parotid gland. It ends as a plexus of 5 major terminal branches that innervate the muscles of facial expression.

The 5 groups of terminal branches are the temporal, zygomatic, buccal, marginal mandibular, and cervical branches. A mnemonic—To Zanzibar By Motor Car (named from superior to inferior)—might help in remembering the names of these 5 terminal branches.

Clinical: An infection, usually caused by the herpes simplex virus, of the facial nerve (CN VII) can cause acute unilateral paralysis of the muscles of facial expression, a condition called Bell's palsy. Facial expression on the affected side is minimal. For example, it is difficult to smile or bare one's teeth, the mouth is drawn to the unaffected (contralateral) side, the person cannot wink, close the eyelid, or wrinkle the forehead on the affected side. Often, over time, the symptoms will disappear, but this may take weeks or months to occur.



F. Netter M.D.

- Efferent fibers
- Afferent fibers
- - - Sympathetic fibers
- Parasympathetic fibers

Oculomotor, Trochlear, and Abducens Nerves: Schema

1. Ciliary ganglion
2. Short ciliary nerves
3. Inferior division of oculomotor nerve
4. Pterygopalatine ganglion
5. Abducens nerve (CN VI)
6. Ophthalmic nerve (CN V₁)
7. Oculomotor nerve (CN III)
8. Trochlear nerve (CN IV)

Comment: This schema shows the motor innervation to the extraocular muscles (from CN III, CN IV, and CN VI) and the autonomic fibers. Parasympathetic fibers arise in the brainstem and course with the oculomotor nerve to the ciliary ganglion.

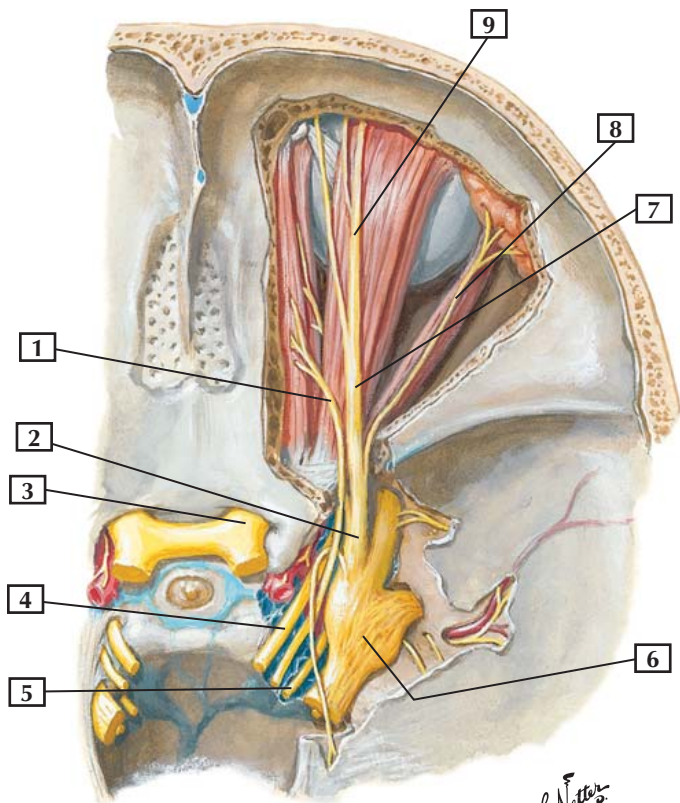
Postganglionic parasympathetics innervate the ciliary muscle (which accommodates the lens) and the sphincter muscle of the pupil.

Sympathetic fibers that synapse in the superior cervical ganglion send postganglionic fibers to the dilator muscle of the pupil.

Sensory innervation to the orbit arises from the ophthalmic division of the trigeminal nerve.

Clinical: Unilateral damage to the oculomotor nerve (CN III) can paralyze the 4 extraocular muscles innervated by this nerve (superior, medial, and inferior rectus muscles and the inferior oblique) and the levator palpebrae superioris muscle of the upper eyelid, causing ophthalmoplegia and ptosis (drooping of the eyelid). Additionally, parasympathetic fibers in CN III will be affected, causing pupillary dilation (unopposed sympathetic innervation of the dilator of the pupil) and an inability to accommodate the lens for close-up vision on the affected (ipsilateral) side.

Superior view



F. Netter M.D.

1. Trochlear nerve (IV)
2. Ophthalmic nerve (V_1)
3. Optic nerve (II)
4. Oculomotor nerve (III)
5. Abducens nerve (VI)
6. Trigeminal (semilunar) ganglion
7. Frontal nerve
8. Lacrimal nerve
9. Supraorbital nerve

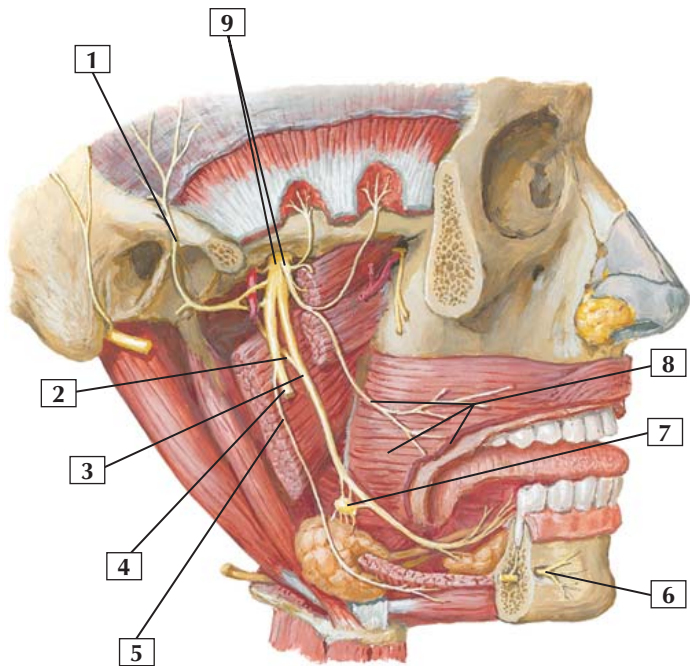
Comment: The sensory innervation to the orbit arises from the ophthalmic division of the trigeminal nerve. The major nerves of this division include the nasociliary, frontal, and lacrimal nerves. The sensory nerve cell bodies reside in the trigeminal (semilunar) ganglion.

The motor innervation of the extraocular muscles comes from the oculomotor, trochlear, and abducens nerves.

The optic nerve leaves the orbit via the optic canal. CN III, CN IV, CN VI, and CN V_1 traverse the superior orbital fissure.

Clinical: The ophthalmic division of the trigeminal nerve (CN V_1) is the smallest division of CN V. In addition to its sensory role and, similar to the other 2 divisions of the trigeminal nerve, this division carries autonomic fibers to the eyeball via its nasociliary nerve and connections to the ciliary ganglion (long and short ciliary nerves). Additionally, it carries parasympathetics from the facial nerve (CN VII) that join the lacrimal branch and innervate the lacrimal glands, which produce tears that moisten the cornea of the eyeball. Orbital trauma or infections in this confined compartment may affect these important autonomic pathways.

Lateral view



F. Netter M.D.

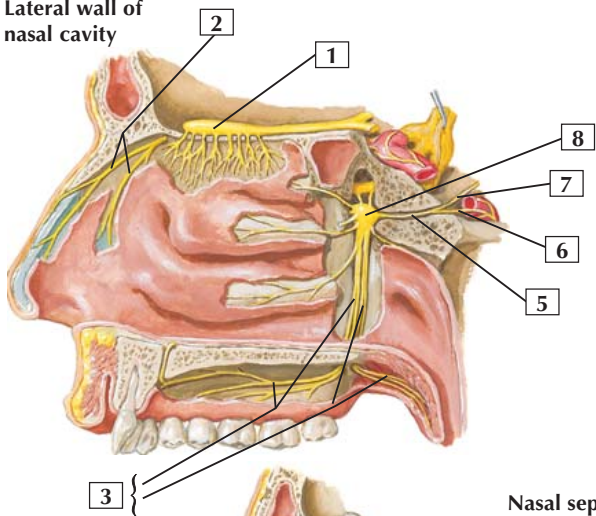
1. Auriculotemporal nerve
2. Chorda tympani nerve
3. Lingual nerve
4. Inferior alveolar nerve (*cut*)
5. Nerve to mylohyoid
6. Mental nerve
7. Submandibular ganglion
8. Buccal nerve and buccinator muscle (*cut*)
9. Mandibular nerve (V₃) (anterior division and posterior division)

Comment: The mandibular division of the trigeminal nerve exits the skull through the foramen ovale and divides into sensory and motor components. This nerve provides motor control to many of the muscles derived from the 1st branchial arch, most notably the muscles of mastication. The sensory components are represented largely by the auriculotemporal, buccal, lingual, and inferior alveolar nerves.

Preganglionic parasympathetic fibers arising from the facial nerve join the lingual nerve via the chorda tympani nerve to synapse in the submandibular ganglion. These postganglionic parasympathetics innervate the sublingual and submandibular salivary glands and the minor salivary glands of the mandibular submucosa.

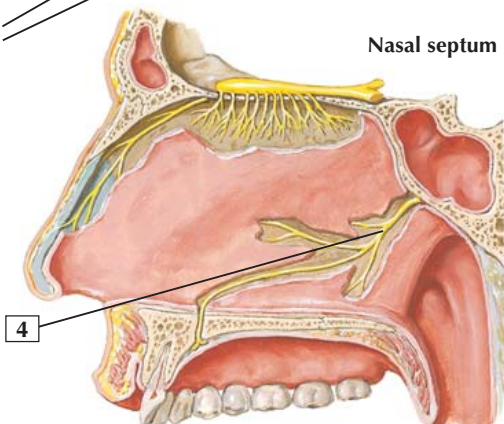
Clinical: Trigeminal neuralgia (*tic douloureux*) is a neurologic condition characterized by episodes of brief, intense facial pain over one of the three regions of distribution of CN V. The pain is so intense that the patient often “winces,” which produces a facial muscle tic. The etiology is uncertain but could be from vascular compression of the CN V sensory ganglion and usually is triggered by touch and drafts of cool air on the face.

Lateral wall of nasal cavity



Nasal septum

F. Netter M.D.



1. Olfactory bulb
2. Lateral internal nasal branch of anterior ethmoidal nerve (CN V₁)
3. Palatine nerves (CN V₂) (Greater and Lesser)
4. Nasopalatine nerve (CN V₂)
5. Nerve (vidian) of pterygoid canal
6. Deep petrosal nerve
7. Greater petrosal nerve
8. Pterygopalatine ganglion

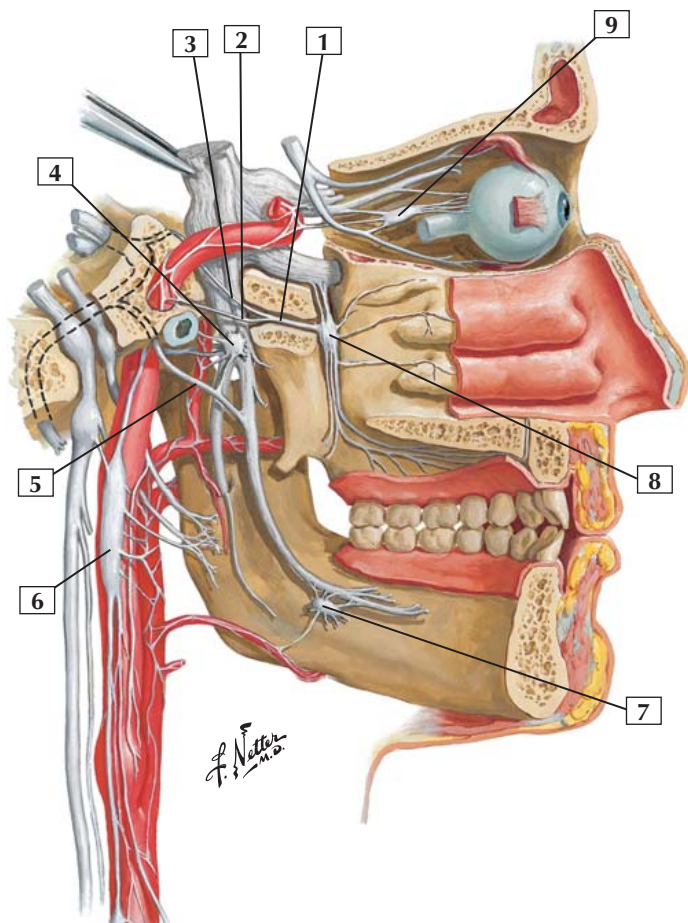
Comment: Vessels of the nasal cavity receive innervation from sympathetic and parasympathetic divisions of the autonomic nervous system.

Sympathetic contributions arise in the deep petrosal nerve as postganglionic fibers that are largely vasomotor in function.

Parasympathetic fibers arise in the facial nerve as preganglionics, course to the pterygopalatine ganglion in the greater petrosal and vidian nerves, and synapse in the pterygopalatine ganglion.

Postganglionic fibers pass to the nasal mucosa, the hard and soft palates, and the mucosa of the paranasal sinuses.

Clinical: Facial fractures may involve a fracture of the cribriform plate, which transmits the axons of the olfactory bipolar neurons. As a brain tract, CN I is covered by the 3 meningeal layers and contains cerebrospinal fluid in its subarachnoid space around the olfactory bulb. A tear of the meninges can cause a leakage of this fluid into the nasal cavity and provide a route of infection from the nose to the brain.

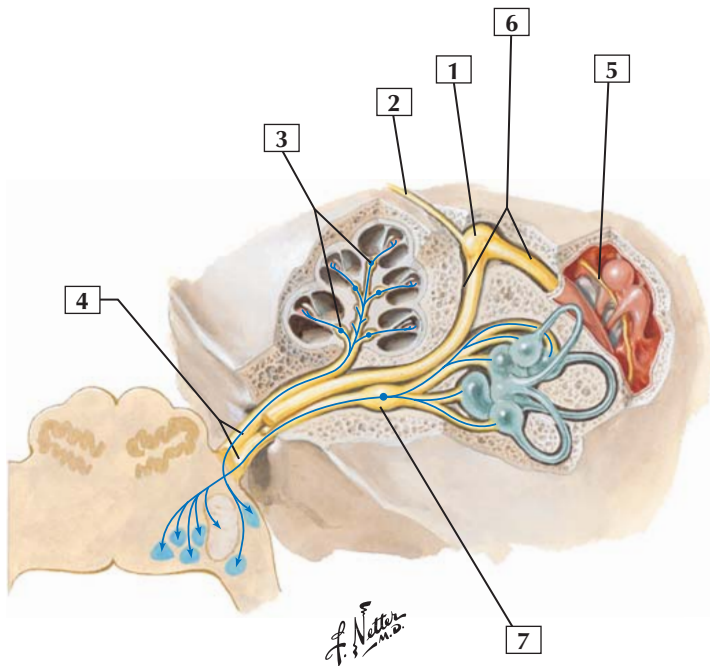


1. Nerve (vidian) of pterygoid canal
2. Deep petrosal nerve
3. Greater petrosal nerve
4. Otic ganglion
5. Chorda tympani nerve
6. Superior cervical sympathetic ganglion
7. Submandibular ganglion
8. Pterygopalatine ganglion
9. Ciliary ganglion

Comment: This schematic shows the 4 parasympathetic ganglia in the head. The ciliary ganglion receives preganglionic parasympathetic fibers from the oculomotor nerve. The otic ganglion receives preganglionic parasympathetic fibers that arise in the glossopharyngeal nerve. The pterygopalatine and submandibular ganglia receive preganglionic parasympathetics that originate in the facial nerve.

Preganglionic sympathetic fibers arise from the upper thoracic spinal cord levels. They ascend the sympathetic trunk to synapse on postganglionic neurons in the superior cervical ganglion. Postganglionic sympathetic fibers travel on blood vessels or adjacent nerves to reach their targets. These sympathetic postganglionic fibers are largely vasomotor in function.

Clinical: A unilateral lesion anywhere along the pathway of the preganglionic sympathetic axons from the upper thoracic spinal cord levels (T1-4) to the superior cervical ganglion (where they synapse), or beyond this ganglion (postganglionic axons), can result in ipsilateral Horner's syndrome. Its cardinal ipsilateral features are miosis (constricted pupil), slight ptosis (drooping of the eyelid due to loss of the superior tarsal muscle), anhydrosis (loss of sweat gland function), and flushing of the face (unopposed vasodilation).



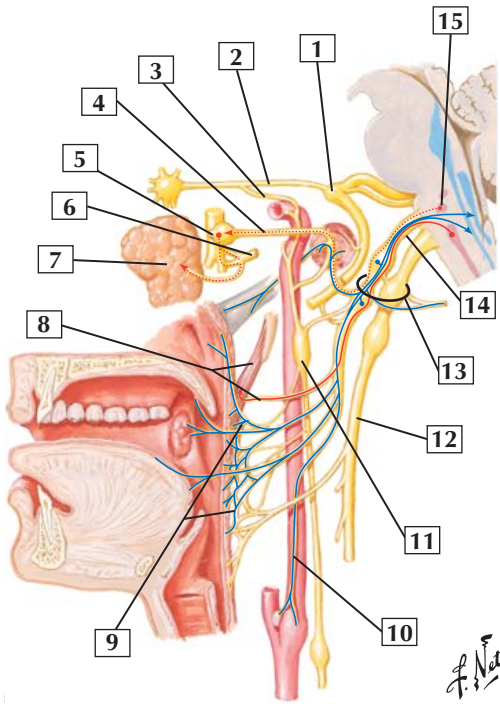
— Afferent fibers

1. Geniculum of facial nerve (site of geniculate ganglion)
2. Greater petrosal nerve
3. Cochlear (spiral) ganglion
4. Vestibulocochlear nerve (CN VIII)
5. Chorda tympani nerve
6. Facial canal and nerve
7. Vestibular ganglion

Comment: The facial and vestibulocochlear nerves traverse the internal acoustic meatus together. The facial nerve makes a sharp bend at the level of the geniculate (sensory) ganglion of the facial nerve before descending and exiting the skull through the stylomastoid foramen. It sends preganglionic parasympathetic fibers to the pterygopalatine ganglion (via the greater petrosal nerve) and to the submandibular ganglion (via the chorda tympani nerve).

The vestibulocochlear nerve carries special sensory fibers from the cochlea via the cochlear nerve (auditory) and from the vestibular apparatus via the vestibular nerve (balance). These 2 branches join and leave the inner ear via the internal acoustic meatus to pass to the brain.

Clinical: Vertigo is a symptom involving the peripheral vestibular system or its central nervous system connections and is characterized by the illusion or perception of motion. Hearing loss can be sensorineural, suggesting a disorder of the inner ear or cochlear division of CN VIII. Conductive hearing loss suggests a disorder of the external or middle ear (tympanic membrane and/or middle ear ossicles).



F. Netter M.D.

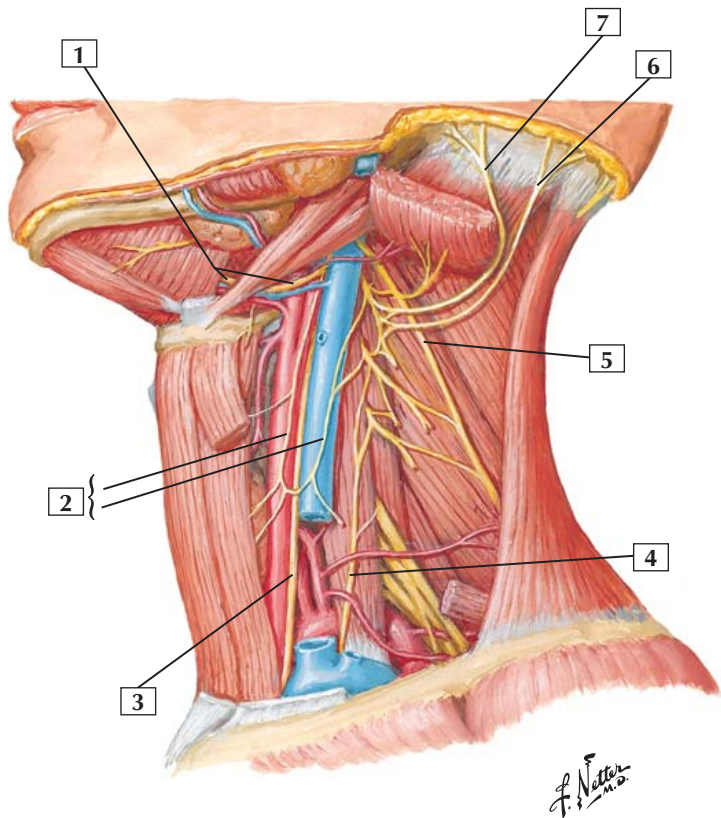
- Efferent fibers
- Afferent fibers
- ⋯ Parasympathetic fibers

1. Geniculate ganglion of facial nerve
2. Greater petrosal nerve
3. Deep petrosal nerve
4. Lesser petrosal nerve
5. Otic ganglion
6. Auriculotemporal nerve (CN V₃)
7. Parotid gland
8. Stylopharyngeus muscle and nerve branch from CN IX
9. Pharyngeal plexus
10. Carotid branch of CN IX
11. Superior cervical ganglion
12. Vagus nerve
13. Jugular foramen
14. Glossopharyngeal nerve
15. Inferior salivatory nucleus

Comment: The glossopharyngeal nerve innervates only 1 muscle (stylopharyngeus) but receives significant general sensory distribution from the pharynx, posterior third of the tongue, middle ear, and auditory tube. CN IX is the nerve of the 3rd pharyngeal (branchial) embryonic arch.

The special sense of taste (posterior third of the tongue) also is conveyed by this nerve. Cardiovascular sensory fibers include those associated with the carotid body (chemoreceptor) and carotid sinus (baroreceptor) region adjacent to the common carotid artery bifurcation.

Clinical: Placing a tongue depressor on the posterior third of the tongue elicits a gag reflex, mediated by the sensory fibers of CN IX on the posterior third of the tongue, which then triggers a gag and elevation of the soft palate, mediated largely by the vagus nerve (CN X).



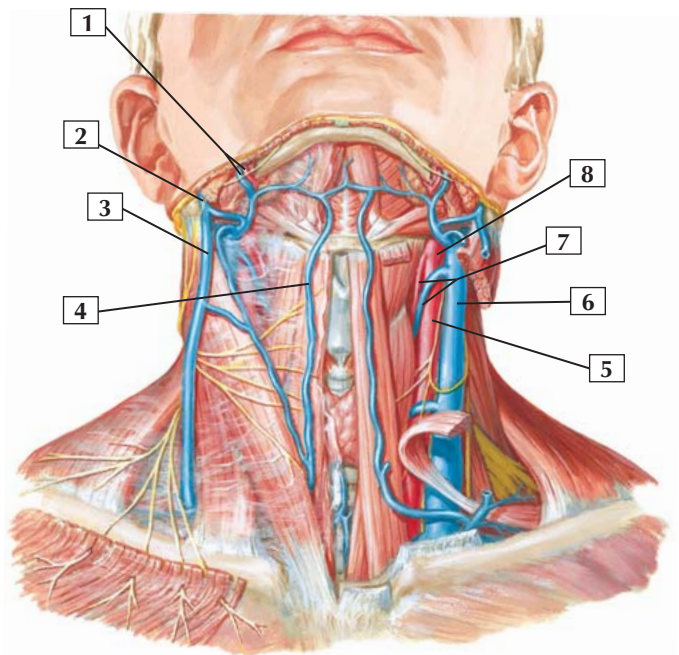
1. Hypoglossal nerve (CN XII)
2. Ansa cervicalis (Superior root; Inferior root)
3. Vagus nerve (CN X)
4. Phrenic nerve
5. Accessory nerve (CN XI)
6. Lesser occipital nerve
7. Great auricular nerve

Comment: The cervical plexus arises from ventral rami of C1-4. It provides motor innervation for many of the muscles of the anterior and lateral compartments of the neck. This plexus also provides cutaneous innervation to the skin of the neck.

Most of the motor contributions to the infrahyoid muscles arise from a nerve loop called the ansa cervicalis (C1-3).

The cervical plexus also gives rise to the first 2 of 3 roots contributing to the phrenic nerve (C3, C4, and C5). The phrenic nerve innervates the abdominal diaphragm.

Clinical: Unilateral trauma to the posterior cervical triangle of the neck may injure the spinal accessory nerve (CN XI) (ipsilateral innervation of the sternocleidomastoid and trapezius muscles), the phrenic nerve (C3-5) (innervates the ipsilateral hemidiaphragm), or the trunks or cords of the brachial plexus. The integrity of each of these nerves should be assessed when trauma is evident.



*F. Netter
M.D.*

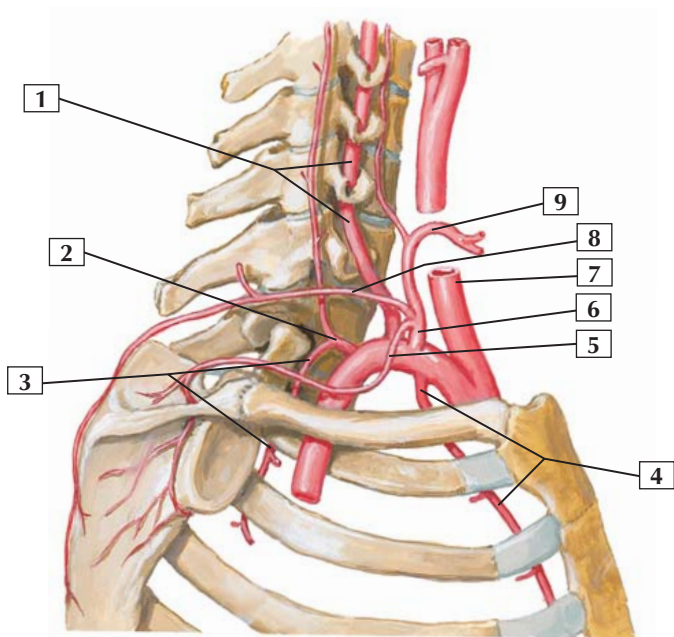
1. Facial artery and vein
2. Retromandibular vein
3. External jugular vein
4. Anterior jugular vein
5. Common carotid artery
6. Internal jugular vein
7. Superior thyroid artery and vein
8. External carotid artery

Comment: Superficial veins of the neck include the external jugular vein and its principal tributaries. The external jugular vein often communicates with the internal jugular vein, which lies deep within the carotid sheath.

The principal arteries of the neck include major branches arising from the subclavian artery (thyrocervical and costocervical trunks) and several branches arising from the external carotid artery.

Clinical: Physicians use the internal jugular vein on the right side to assess the jugular venous pulse, which provides an indication of the venous pressure in the right atrium of the heart. If the waveform pattern of the pulse is abnormal, it may indicate some pathologic process associated with right-sided congestive heart failure, a tricuspid valve problem, or some other abnormality.

Right lateral schematic view



F. Netter M.D.

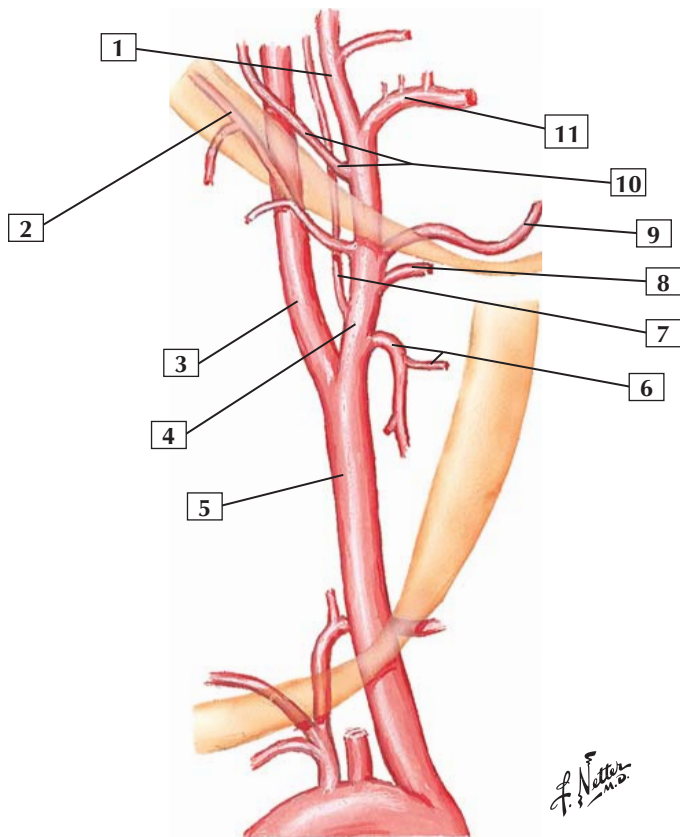
1. Vertebral artery
2. Costocervical trunk
3. Supreme intercostal artery
4. Internal thoracic artery
5. Suprascapular artery
6. Thyrocervical trunk
7. Common carotid artery
8. Transverse cervical artery
9. Inferior thyroid artery

Comment: The subclavian artery is divided into 3 parts relative to the anterior scalene muscle. The 1st part is medial to the muscle, the 2nd is posterior, and the 3rd is lateral. Branches of the subclavian include the vertebral, internal thoracic (mammory), thyrocervical trunk, costocervical trunk, and dorsal scapular arteries.

The vertebral artery ascends through the C6 to C1 transverse foramina and enters the foramen magnum. The internal thoracic descends parasternally. The thyrocervical trunk supplies the thyroid gland (inferior thyroid), the lower region of the neck (transverse cervical), and the dorsal scapula (suprascapular). The costocervical trunk supplies the deep neck (deep cervical) and several intercostal spaces (supreme intercostal). The dorsal scapular branch is inconstant; it may arise from the transverse cervical artery.

Clinical: The branches of the subclavian artery anastomose with branches of the axillary artery around the shoulder joint, with branches of the thoracic aorta (intercostal branches) along the rib cage, across the midline of the neck and face, and with the internal carotid arteries and the vertebral branches (circle of Willis on the brainstem).

External carotid branches: schema



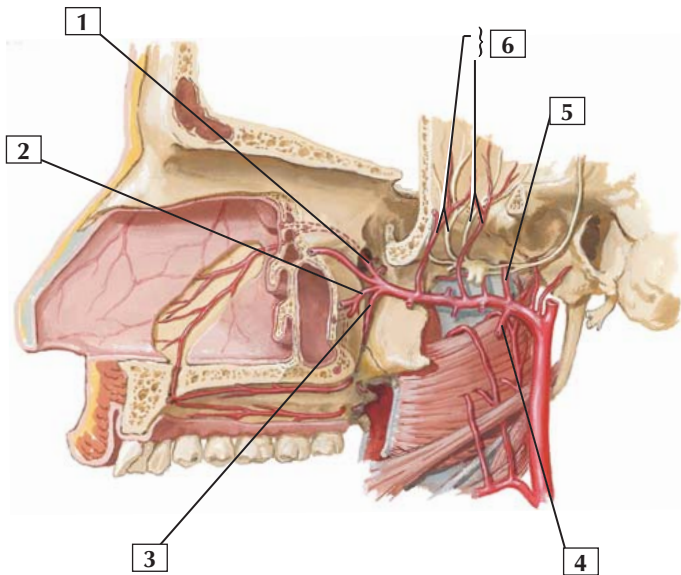
1. Superficial temporal artery
2. Occipital artery
3. Internal carotid artery
4. External carotid artery
5. Common carotid artery
6. Superior thyroid artery and superior laryngeal branch
7. Ascending pharyngeal artery
8. Lingual artery
9. Facial artery
10. Posterior auricular artery
11. Maxillary artery

Comment: The common carotid artery ascends in the neck in the carotid sheath. At about the level of the superior border of the thyroid cartilage it divides into the internal carotid artery, which passes into the cranium, and the external carotid artery, which supplies more superficial structures lying outside the skull. The external carotid artery gives rise to 8 branches.

These 8 branches supply much of the blood to the head outside of the cranium, although several branches also ultimately enter the cranial regions (meningeal and auricular branches of the maxillary artery, one of the terminal branches of the external carotid).

Clinical: The branches of the external carotid arteries anastomose across the midline neck (superior thyroid arteries) and the face to provide collateral circulation should an artery be compromised by occlusion or lacerated in trauma.

The superficial temporal artery supplies the scalp, which bleeds profusely when cut because the small arteries are held open by the tough connective tissue lying just beneath the skin.



*F. Netter
M.D.*

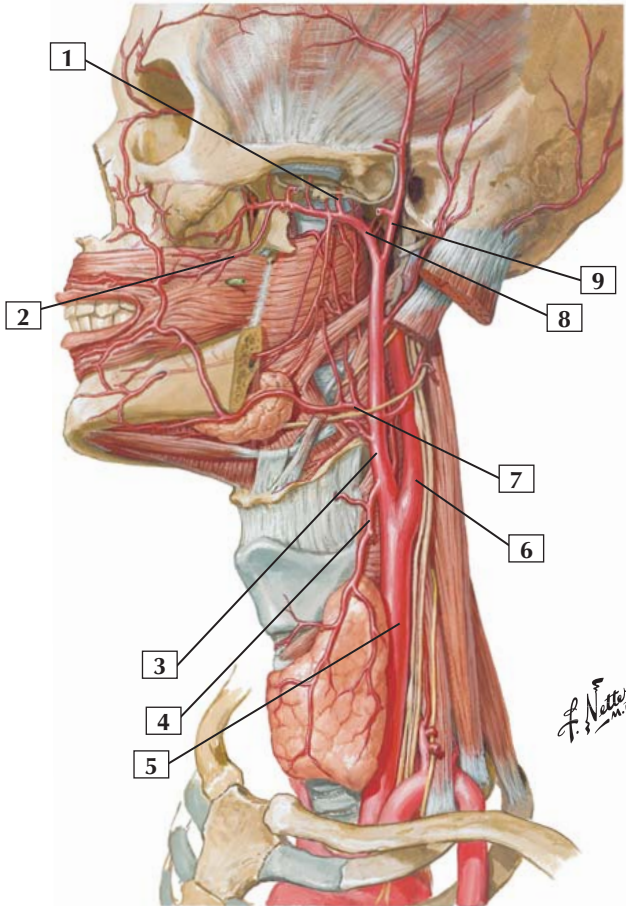
Maxillary Artery

1. Sphenopalatine artery
2. Posterior superior alveolar artery
3. Descending palatine artery in pterygopalatine fossa
4. Inferior alveolar artery
5. Middle meningeal artery
6. Deep temporal arteries and nerves

Comment: The maxillary artery is 1 of the 2 terminal branches of the external carotid artery. It passes superficially or deeply to the lateral pterygoid muscle and courses medially in the infratemporal fossa. Descriptively, it is divided into 3 parts.

The 1st (retromandibular) portion of this artery gives rise to branches supplying the tympanic cavity and membrane, dura, mandibular teeth and gums, ear, and chin. The 2nd (pterygoid) portion supplies the muscles of mastication and the buccinator. The 3rd (pterygopalatine) part supplies the maxillary teeth and gums, portions of the face, orbit, palate, auditory tube, superior pharynx, paranasal sinuses, and nasal cavity.

Clinical: A nosebleed, or epistaxis, is a common occurrence and often involves the richly vascularized region of the vestibule and the anteroinferior aspect of the nasal septum (Kiesselbach's area). Many of these small nasal arteries and arterioles are branches of the maxillary artery and facial artery (lateral nasal and septal branches).



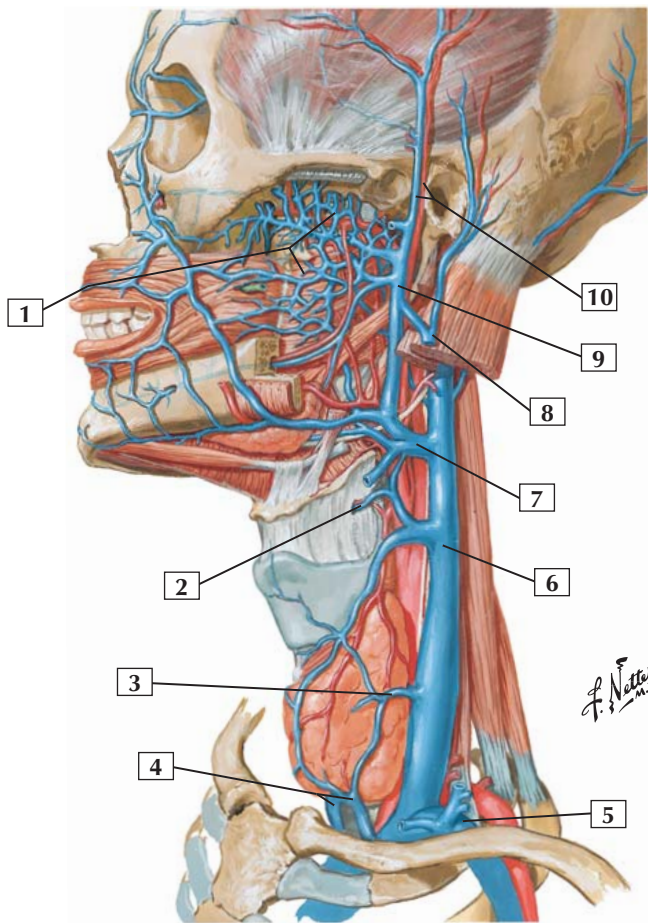
1. Middle meningeal artery
2. Buccal artery
3. External carotid artery
4. Superior thyroid artery
5. Common carotid artery
6. Internal carotid artery
7. Facial artery
8. Maxillary artery
9. Superficial temporal artery

Comment: Arteries of the oral and pharyngeal regions arise principally from branches of the external carotid artery. The external carotid gives rise to 8 branches: the superior thyroid artery, lingual artery, facial artery, ascending pharyngeal artery, occipital artery, posterior auricular artery, maxillary artery, and superficial temporal artery.

The maxillary artery contributes many branches to the infratemporal region, nasal cavities, and muscles of mastication. Descriptively, the maxillary artery is divided into 3 parts (some of its branches are shown in this figure).

The 1st (retromandibular) portion of this artery gives rise to branches supplying the tympanic cavity and membrane, dura, mandibular teeth and gums, ear, and chin. The 2nd (pterygoid) portion supplies the muscles of mastication and the buccinator. The 3rd (pterygopalatine) part supplies the maxillary teeth and gums, portions of the face, orbit, palate, auditory tube, superior pharynx, paranasal sinuses, and nasal cavity.

Anastomoses among the branches of the facial and maxillary artery are common.

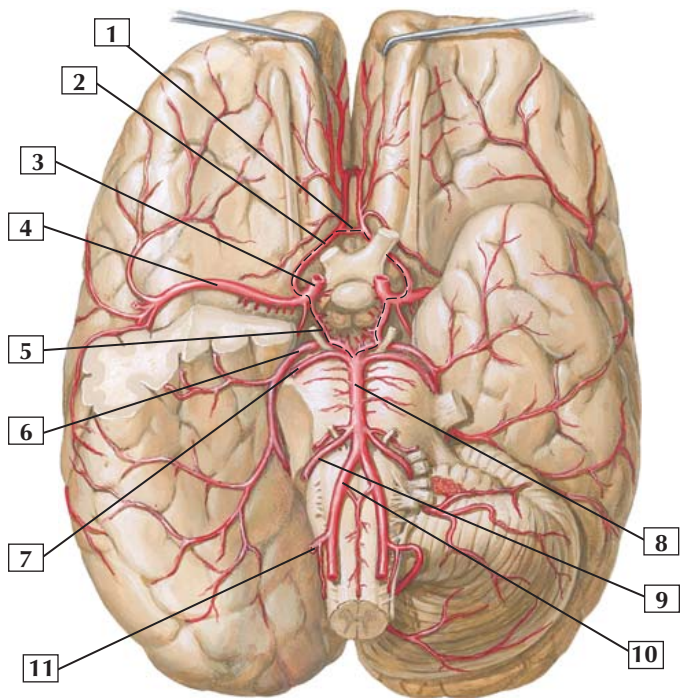


1. Pterygoid plexus
2. Superior laryngeal vein
3. Middle thyroid vein
4. Inferior thyroid veins
5. Subclavian vein
6. Internal jugular vein
7. Common trunk for facial, retromandibular, and lingual veins
8. External jugular vein (*cut*)
9. Retromandibular vein
10. Superficial temporal vein and artery

Comment: Veins of the facial, oral, and pharyngeal regions are largely tributaries that ultimately collect in the internal jugular vein. In the infratemporal region, a pterygoid plexus of veins communicates with the cavernous sinus and veins of the orbit and oral cavity. Many of the veins of this region have the same names as their corresponding arteries.

Key veins are as follows: The retromandibular vein receives tributaries from the temporal and infratemporal regions (pterygoid plexus), nasal cavity, pharynx, and oral cavity. The internal jugular vein drains the brain, face, thyroid gland, and neck. The external jugular vein drains the superficial neck, lower neck and shoulder, and upper back (often communicates with the retromandibular vein).

Clinical: These veins do not possess valves and provide avenues for the spread of infection throughout the head and neck region. The pterygoid plexus of veins has connections with the ophthalmic veins (and to the cavernous sinus via these veins), facial veins, and the superficial temporal veins and their small tributaries, which also pass through the skull as emissary veins to drain into the dural venous sinuses.



*F. Netter
M.D.*

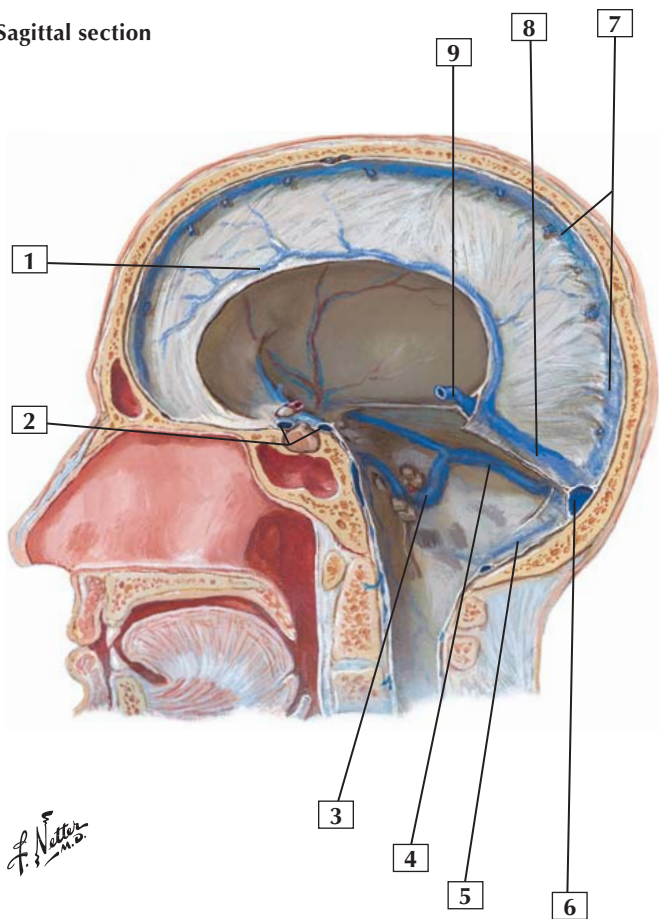
1. Anterior communicating artery
2. Anterior cerebral artery
3. Internal carotid artery
4. Middle cerebral artery
5. Posterior communicating artery
6. Posterior cerebral artery
7. Superior cerebellar artery
8. Basilar artery
9. Anterior inferior cerebellar artery
10. Vertebral artery (*cut*)
11. Posterior inferior cerebellar artery

Comment: Branches of the internal carotid and vertebral arteries supply the brain. After entering the foramen magnum, the 2 vertebral arteries join to form the basilar artery. The latter continues forward on the anterior aspect of the brainstem, and its branches anastomose with the branches of the internal carotid artery to form the cerebral arterial circle of Willis (*dashed line*).

The anterior circulation to the brain encompasses the anterior and middle cerebral arteries. The posterior circulation encompasses the vertebrobasilar system and the posterior cerebral artery. Generally, the arteries supplying the brain are end arteries, with insufficient anastomotic connections to compensate for occlusion of an artery.

Clinical: The most common cause of subarachnoid hemorrhage (bleeding into the subarachnoid space) is the rupture of a saccular, or berry, aneurysm of one of the arteries of the cerebral and brainstem circulation. Berry aneurysms commonly occur at artery branch points with about 85% occurring between the anterior cerebral, internal carotid, and middle cerebral branches.

Sagittal section



F. Netter M.D.

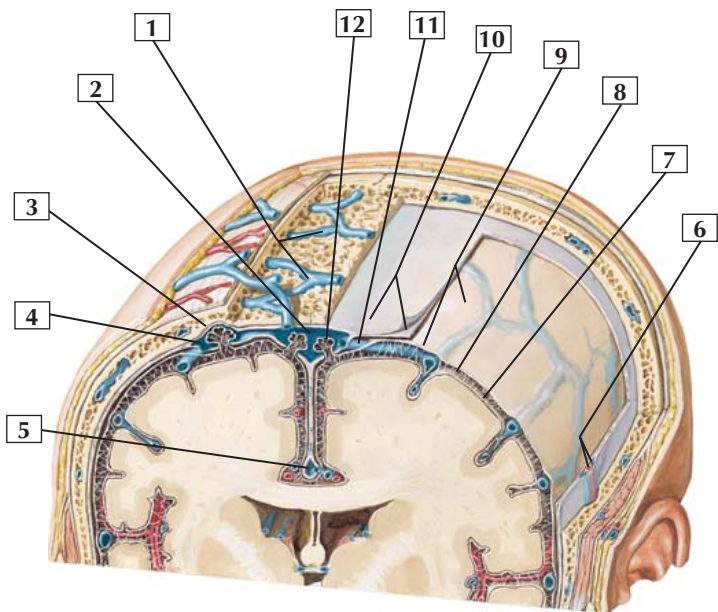
1. Inferior sagittal sinus
2. Anterior and posterior intercavernous sinuses
3. Sigmoid sinus
4. Transverse sinus
5. Occipital sinus
6. Confluence of sinuses
7. Superior sagittal sinus
8. Straight sinus
9. Great cerebral vein (Galen)

Comment: The dural venous sinuses form between the periosteal (endosteal) and meningeal layers of the dura mater. The superficial and deep regions of the brain are drained by the superior sagittal and inferior sagittal venous sinuses. Most of the venous blood from the brain collects in these dural venous sinuses and ultimately drains into the internal jugular veins.

Infections can gain access to these dural venous sinuses and spread to other regions of the head.

Clinical: Much of the blood returning from the cerebral cortical areas passes from the cortical surface across the subarachnoid space, pierces the arachnoid and meningeal dural layer, and empties into the superior sagittal dural venous sinus. With aging, the brain volume decreases and sudden motion of this smaller brain in the cranial vault, typically from falls and a bump on the head by elderly individuals, can cause a tearing of the bridging veins. When this happens, bleeding can occur between the arachnoid and meningeal dural layer, causing a subdural hematoma.

Coronal dissection



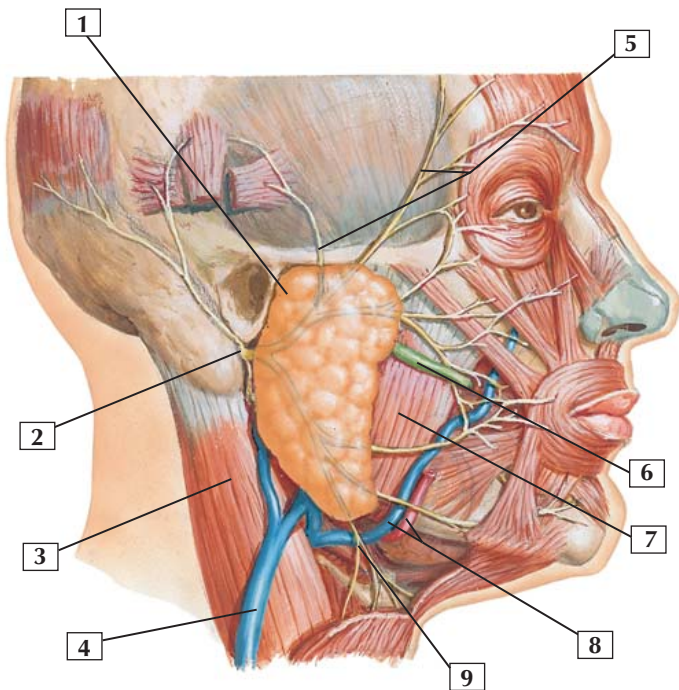
*F. Netter
M.D.*

1. Diploic veins
2. Superior sagittal sinus
3. Granular foveola (indentation of skull by arachnoid granulation)
4. Lateral (venous) lacuna
5. Inferior sagittal sinus
6. Middle meningeal vessels
7. Pia mater
8. Subarachnoid space
9. Arachnoid mater
10. Dura mater (periosteal and meningeal layers)
11. Cerebral vein penetrating subdural space to enter sinus
12. Arachnoid granulation

Comment: The meninges include the dura (periosteal and meningeal layers) mater, the arachnoid mater, and the pia mater. In the subarachnoid space, cerebral veins draining the cortex are bathed in the cerebrospinal fluid. These cerebral veins ultimately drain venous blood into the dural venous sinuses.

The arachnoid granulations are tufts of arachnoid villi that project into the superior sagittal sinus and return circulating cerebrospinal fluid to the venous system. About 500-700 mL of cerebrospinal fluid is produced daily by the choroid plexus.

Clinical: Veins of the scalp communicate with the dural venous sinuses via emissary veins. Because these veins are valveless, infections from the scalp can gain access to the cranial cavity. Therefore, scalp wounds should be cleansed thoroughly to prevent infection. Diploic veins (veins in the diploë or spongy bone of the skull) also connect to emissary veins and may drain into the dural venous sinuses.



F. Netter M.D.

1. Parotid gland
2. Main trunk of facial nerve emerging from stylomastoid foramen
3. Sternocleidomastoid muscle
4. External jugular vein
5. Temporal branches of facial nerve
6. Parotid duct
7. Masseter muscle
8. Facial artery and vein
9. Cervical branch of facial nerve

Comment: The parotid salivary gland is the largest of the 3 paired salivary glands.

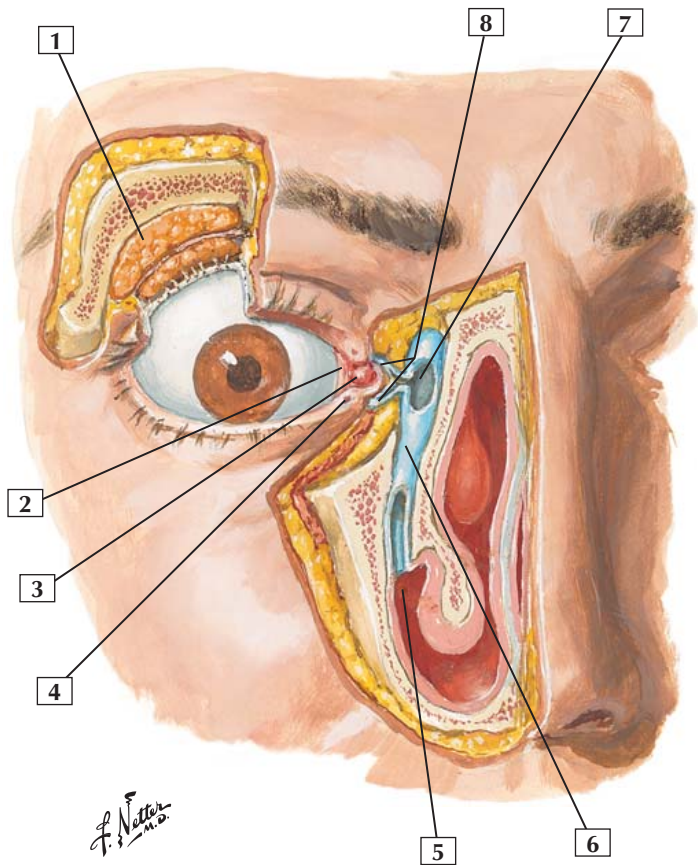
The parotid duct passes from the gland, pierces the buccinator muscle, and enters the oral cavity opposite the 2nd maxillary molar tooth.

The facial nerve (CN VII) exits through the stylomastoid foramen, passes through the parotid gland, and distributes its 5 terminal branches over the face.

Clinical: Surgery involving the parotid gland (tumor resection) places the terminal motor branches of the facial nerve (CN VII) in jeopardy, which could result in paralysis or weakness to the facial muscles.

A stone (calculus) may occlude the parotid (Stensen's) duct, requiring its removal.

The parotid gland is innervated by the glossopharyngeal nerve, via preganglionic parasympathetic fibers that course to the otic ganglion via the lesser petrosal nerve, synapse there, and send postganglionic fibers to the gland via the auriculotemporal branch of CN V₃.



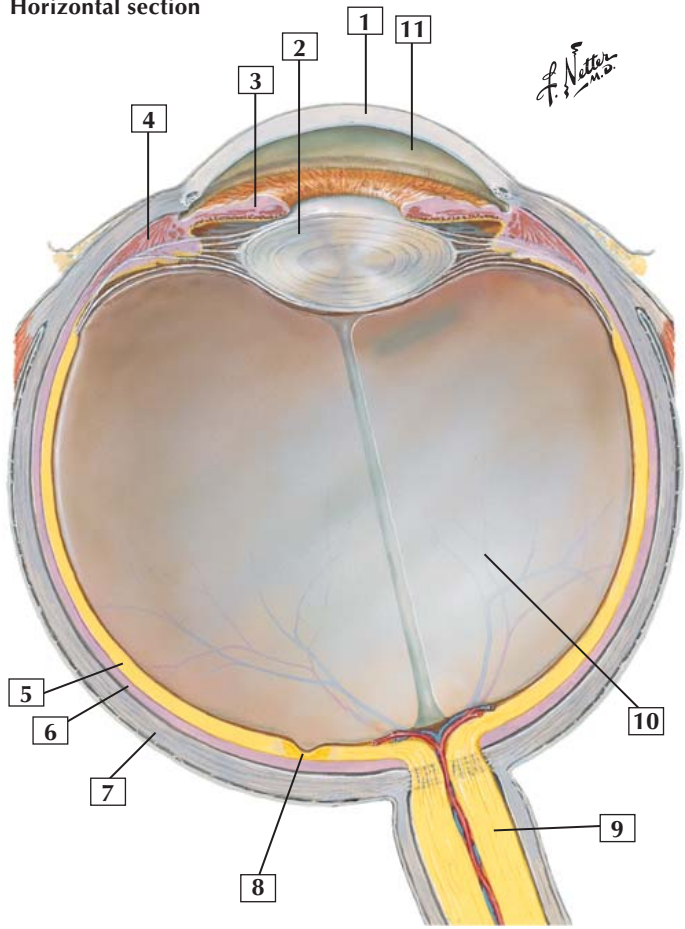
1. Orbital part of lacrimal gland
2. Plica semilunaris and lacrimal lake
3. Lacrimal caruncle
4. Inferior lacrimal papilla and punctum
5. Inferior nasal meatus
6. Nasolacrimal duct
7. Lacrimal sac
8. Lacrimal canaliculi

Comment: The lacrimal apparatus consists of the lacrimal glands, which secrete tears, and a system of collection ducts. Lacrimal ducts convey tears from the glands to the conjunctival sac, and the lacrimal canaliculi drain them into the lacrimal sac. Next, tears drain down the nasolacrimal duct and empty into the inferior nasal meatus behind the inferior nasal concha.

Production of tears is under parasympathetic autonomic control exerted by nerve fibers that originate in the facial nerve (CN VII) and ultimately reach the glands via the lacrimal nerve, a branch of the ophthalmic division of the trigeminal nerve.

Clinical: The tears contain albumins, lactoferrin, lysozyme, lipids, metabolites, and electrolytes and provide a protective layer of fluid that helps keep the cornea moist and protected from infection. Dry eye (insufficient tear production) is not uncommon and can be treated with lubricating moisturizing eyedrops or systemically with prescription medications.

Horizontal section





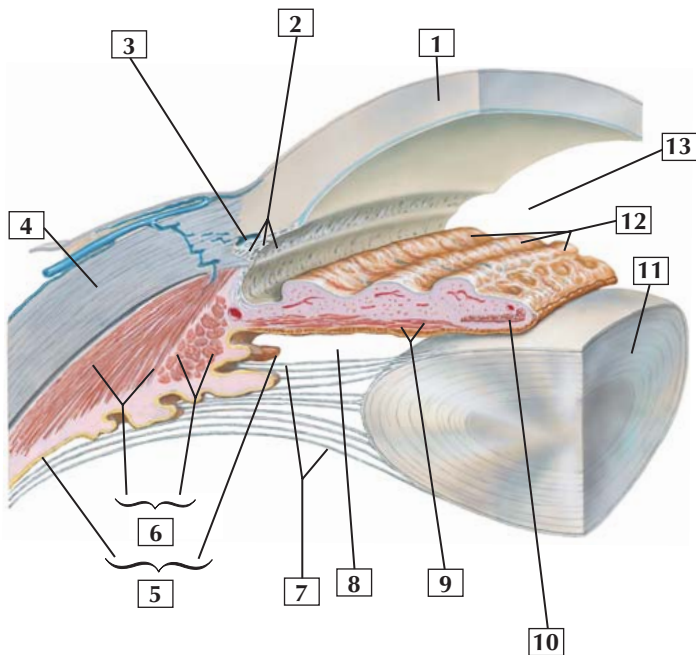
1. Cornea
2. Lens
3. Iris
4. Ciliary body and ciliary muscle
5. Optic (visual) part of retina
6. Choroid
7. Sclera
8. Fovea centralis in macula
9. Optic nerve (CN II)
10. Vitreous body
11. Anterior chamber

Comment: The eyeball has 3 layers: an external fibrous layer consisting of the sclera and cornea; a middle vascular pigmented layer consisting of the choroid, ciliary body, and iris; and an internal neural layer, the retina.

The fovea centralis, a central depression in the macula, is an avascular region that contains cones but no rods. This area provides the most acute vision.

Light passes to the retina through the refractive media of the eye, which consists of the cornea, aqueous humor, lens, and vitreous humor.

Clinical: An opacity of the lens is called a cataract. Treatment often involves surgically removing the lens and implanting a plastic lens and then correcting the vision with glasses.



*F. Netter
M.D.*

Anterior and Posterior Chambers of the Eye

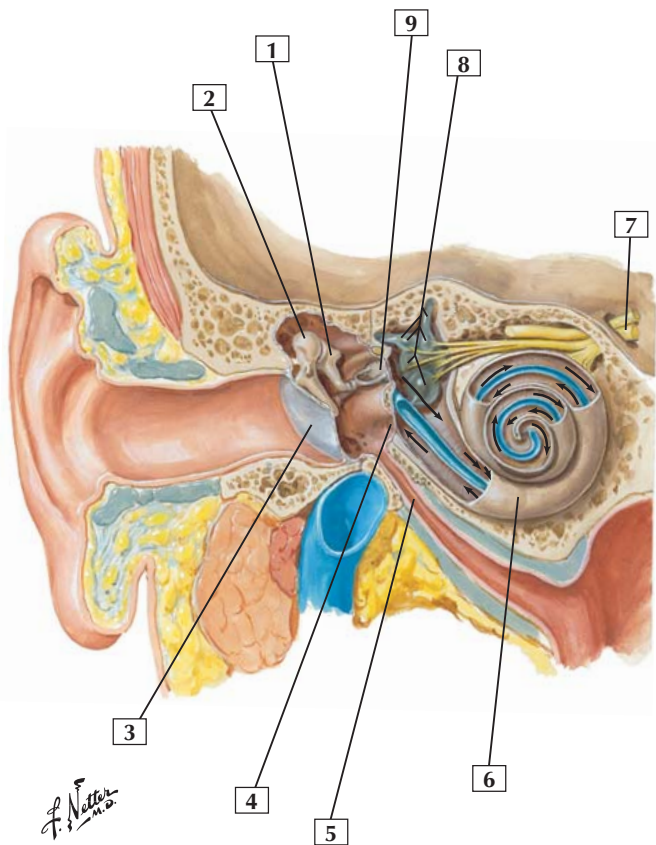
1. Cornea
2. Trabecular meshwork
3. Scleral venous sinus (Schlemm's canal)
4. Sclera
5. Ciliary body (and process)
6. Ciliary muscle (meridional and circular fibers)
7. Zonular fibers
8. Posterior chamber
9. Dilator muscle of pupil
10. Sphincter muscle of pupil
11. Lens
12. Iris (folds)
13. Anterior chamber

Comment: The region of the eyeball between the zonular fibers and the iris is the posterior chamber. It communicates, by an opening in the iris (the pupil), with the anterior chamber lying between the iris and the cornea. Aqueous humor, produced by the ciliary process, fills these 2 chambers and is absorbed into the trabecular meshwork and scleral venous sinus.

The dilator and sphincter smooth muscles of the iris account for the dilation and constriction of the pupillary opening.

Contraction of the ciliary muscle (circular fibers) has a sphincteric action on the ciliary body such that the zonular fibers relax and the elastic lens becomes more rounded, leading to accommodation.

Clinical: An increase in ocular pressure above normal can lead to glaucoma. This condition usually results from increased resistance to outflow of the aqueous humor via the scleral venous sinus. This pressure can damage the optic disc where axons are passing from retinal ganglion cells to the optic nerve.



Note: Arrows indicate course of sound waves

1. Incus
2. Malleus (head)
3. Tympanic membrane
4. Round (cochlear) window
5. Pharyngotympanic (auditory) tube
6. Cochlea
7. Vestibulocochlear nerve (CN VIII)
8. Semicircular ducts, ampullae, utricle, and saccule
9. Stapes in oval (vestibular) window

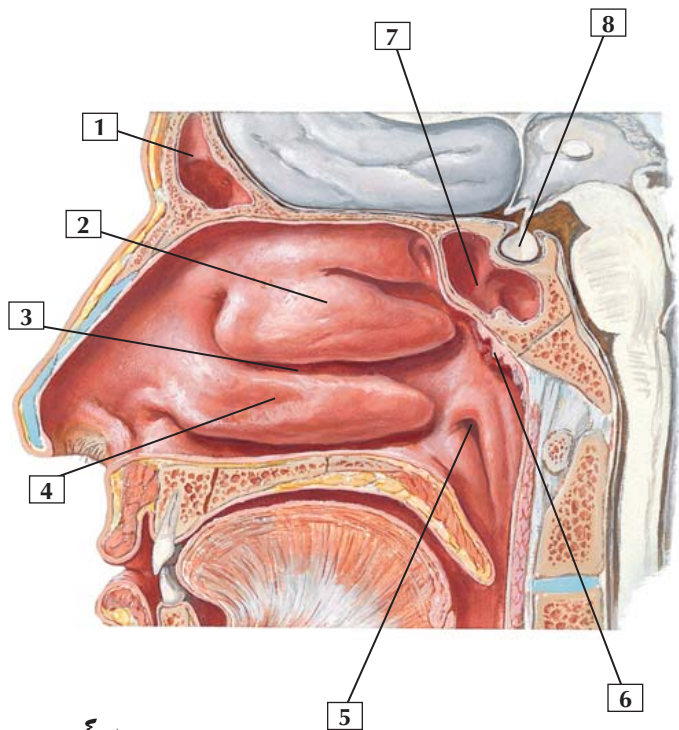
Comment: The external ear consists of the auricle and the external acoustic meatus.

The middle ear consists of the tympanic cavity and its 3 ossicles. The lateral wall of the tympanic cavity is formed by the tympanic membrane (eardrum). The medial wall contains the oval and round windows. The auditory ossicles include the malleus (hammer), incus (anvil), and stapes (stirrup). The middle ear connects to the nasopharynx by the auditory (eustachian) tube. Via the auditory tube, air may enter or leave the middle ear cavity and equalize middle ear pressure with atmospheric pressure.

The inner ear consists of the cochlea and the vestibular apparatus. The acoustic apparatus and vestibular apparatus are innervated by CN VIII, the vestibulocochlear nerve.

The external ear is innervated by branches from CN V₃, CN VII, and CN X. The middle ear is innervated by the glossopharyngeal nerve (CN IX).

Clinical: Acute otitis externa, better known as swimmer's ear, is an inflammation or infection of the external ear. Acute otitis media (earache) is an inflammation of the middle ear and is common in children younger than age 15.



F. Netter M.D.

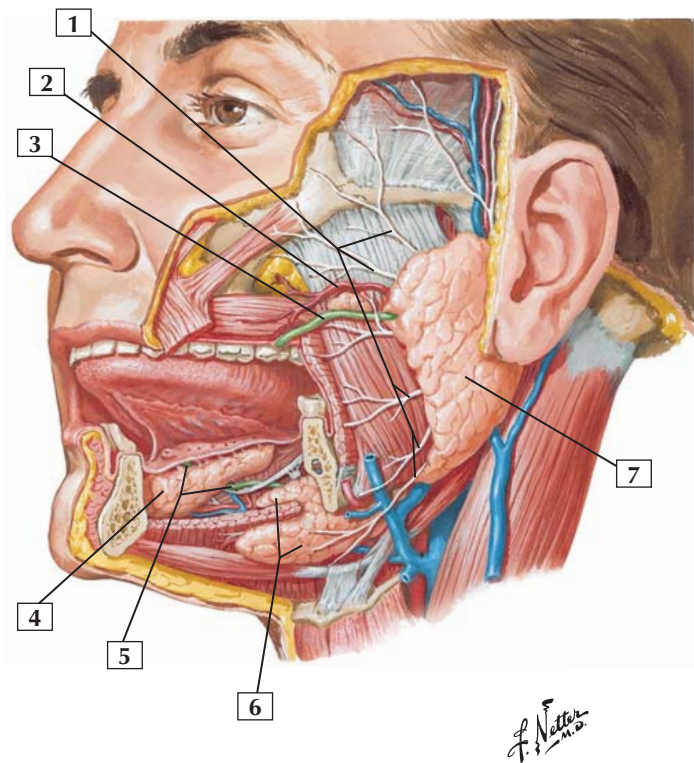
1. Frontal sinus
2. Middle nasal concha
3. Middle nasal meatus
4. Inferior nasal concha (turbinate)
5. Opening of pharyngotympanic (auditory) tube
6. Pharyngeal tonsil (adenoid if enlarged)
7. Sphenoidal sinus
8. Hypophysis (pituitary gland) in sella turcica

Comment: The lateral nasal wall is characterized by 3 nasal conchae or turbinates. The space beneath each concha is the meatus.

The nasolacrimal duct opens into the inferior nasal meatus. The frontal sinus and maxillary sinus open into the middle nasal meatus. Additionally, the anterior and middle ethmoidal sinuses open on the ethmoidal bulla, beneath the middle nasal concha. The posterior ethmoidal sinus opens in the superior meatus, and the sphenoidal sinus opens in the sphenothmoidal recess.

The vascular supply of this region is via branches of the sphenopalatine artery (from the maxillary artery), and the innervation is from the maxillary nerve or CN V₂ (general sensation), CN I (olfaction), and CN VII (secretomotor fibers to the mucous glands via the pterygopalatine ganglion).

Clinical: Rhinosinusitis is an inflammation of the paranasal sinuses, especially the ethmoidal and maxillary sinuses, and nasal cavity. This infection usually results from a respiratory virus or secondary bacterial infection. Nasal and sinus congestion, facial pain and pressure, discharge, fever, headache, painful maxillary teeth, and halitosis are some of the signs and symptoms.

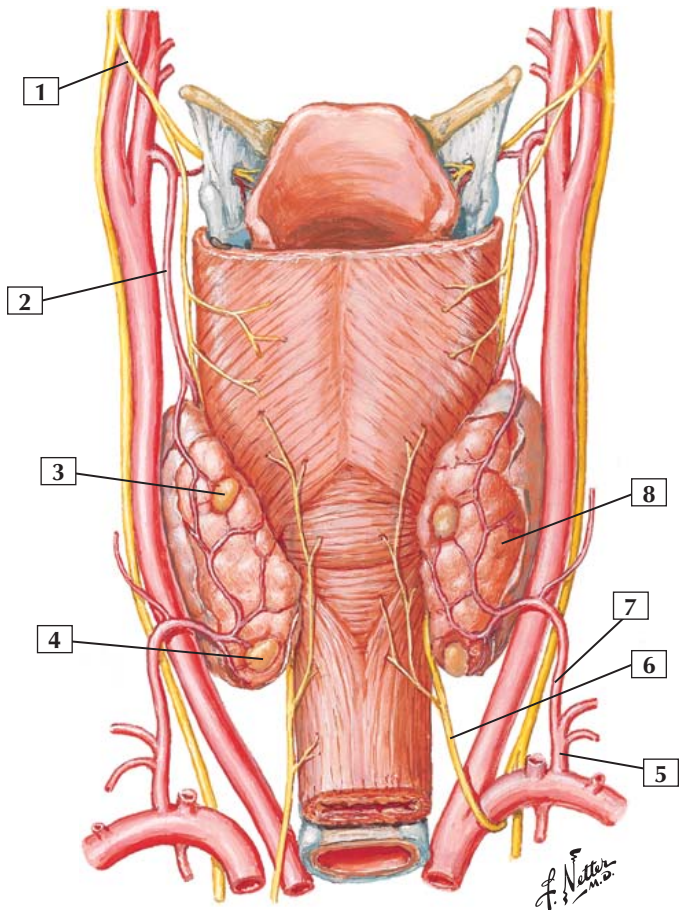


1. Branches of facial nerve
2. Transverse facial artery
3. Parotid duct
4. Sublingual gland
5. Submandibular duct
6. Submandibular gland
7. Parotid gland

Comment: The parotid gland empties into the oral cavity via the parotid duct. The submandibular gland empties into the floor of the mouth via the submandibular duct, which lies beneath the oral mucosa in close relationship to the lingual nerve. The sublingual salivary gland opens through several small ducts beneath the tongue.

The parotid gland is a totally serous gland, whereas the submandibular salivary gland is mostly serous and partially mucous. The sublingual salivary gland is almost completely mucous.

Minor salivary glands exist in the mucosa of the hard palate, cheeks, tongue, and lips.



Parathyroid and Thyroid Glands: Posterior View

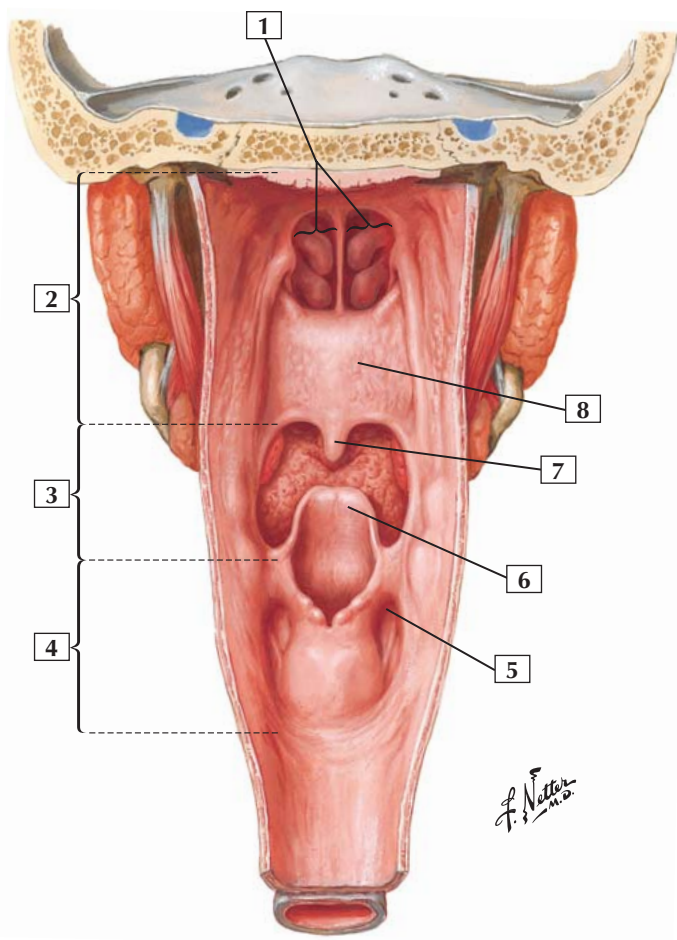
1. Superior laryngeal nerve
2. Superior thyroid artery
3. Superior parathyroid gland
4. Inferior parathyroid gland
5. Thyrocervical trunk
6. Recurrent laryngeal nerve
7. Inferior thyroid artery
8. Right lobe of thyroid gland

Comment: Because of their embryonic development, the parathyroid glands, especially the inferior pair, may vary in location. Although most people have 4 parathyroid glands, it is common to have more than 4.

During neck surgery, it is important to note the location of the recurrent laryngeal nerves. Both recurrent nerves typically ascend in the tracheoesophageal groove and are in close relationship to the right and left lobes of the thyroid gland. The right recurrent laryngeal nerve loops around the right subclavian artery, whereas the left recurrent laryngeal nerve loops around the arch of the aorta.

Clinical: The most common type of hyperthyroidism in patients younger than 40 years old is Graves' disease. The excess release of thyroid hormone upregulates tissue metabolism and leads to symptoms indicating increased metabolism (excitability, flushing, warm skin, increased heart rate, shortness of breath, tremor, exophthalmos, myxedema, goiter).

Primary hyperparathyroidism leads to the secretion of excess parathyroid hormone that increases plasma calcium levels at the expense of calcium deposition in the bones (weakens the bones).



1. Choanae
2. Nasopharynx
3. Oropharynx
4. Laryngopharynx
5. Piriform fossa
6. Epiglottis
7. Uvula
8. Soft palate

Comment: The pharynx consists of the nasopharynx, oropharynx, and laryngopharynx. The nasopharynx lies directly behind the nasal cavities, or choanae. The oropharynx lies between the soft palate and epiglottis, directly behind the oral cavity. The laryngopharynx (also called the hypopharynx) is the lower portion of the pharynx; it lies between the epiglottis and the beginning of the esophagus.

During swallowing, food moves from the oral cavity into the oropharynx, prompting the soft palate to rise and seal off the nasopharynx. The epiglottis bends downward, while the laryngeal apparatus moves upward, closing off the laryngeal inlet (aditus). The bolus of food cascades around the epiglottis and passes through the piriform fossae to enter the upper esophagus.

Clinical: Small bones (fish bones) can become lodged in the piriform fossae, causing great pain and a feeling of choking or gagging. Caution must be exercised when removing the bone so as not to damage the underlying mucosa because the internal branch of the superior laryngeal nerve (sensory to the laryngopharynx and larynx above the vocal folds) lies just beneath this mucosa.

Bones and Joints

- 2-1** Vertebral Column
- 2-2** Cervical Vertebrae
- 2-3** Thoracic Vertebrae
- 2-4** Lumbar Vertebra
- 2-5** Lumbar Vertebrae
- 2-6** Vertebral Ligaments: Lumbar Region
- 2-7** Sacrum and Coccyx

Muscles

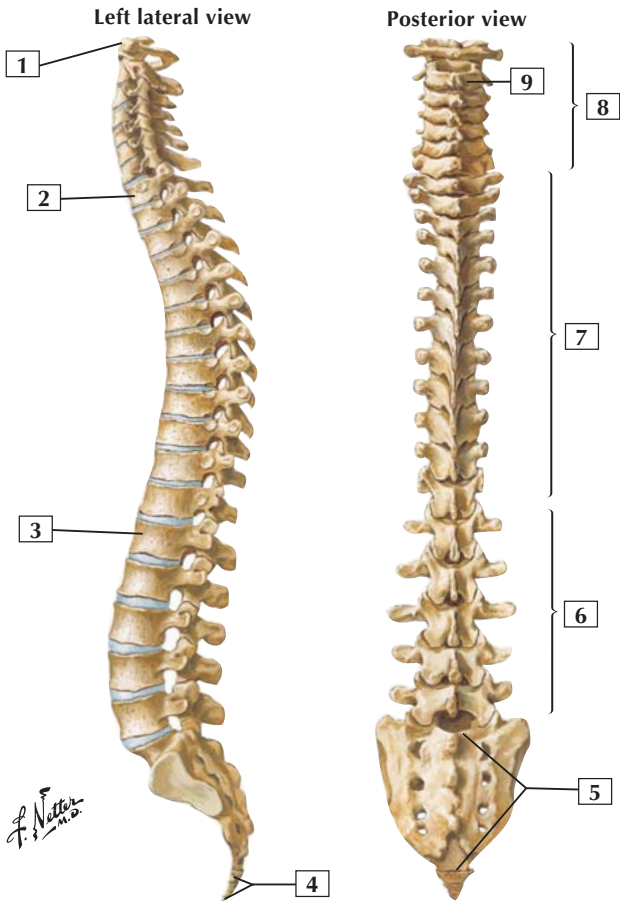
- 2-8** Rhomboid Minor and Rhomboid Major
- 2-9** Serratus Posterior Superior and Serratus Posterior Inferior
- 2-10** Muscles of Back: Intermediate Layers
- 2-11** Erector Spinae
- 2-12** Muscles of Back: Deep Layers
- 2-13** Splenius Capitis and Splenius Cervicis
- 2-14** Semispinalis Capitis
- 2-15** Obliquus Capitis Superior
- 2-16** Obliquus Capitis Inferior
- 2-17** Rectus Capitis Posterior Minor and Rectus Capitis Posterior Major

Nerves

- 2-18** Spinal Cord and Ventral Rami In Situ
- 2-19** Meninges and Nerve Roots
- 2-20** Spinal Nerve Origin: Cross Section
- 2-21** Thoracic Spinal Nerve and Connections to Sympathetic Trunk
- 2-22** Suboccipital Triangle

Vessels

- 2-23** Arteries of Spinal Cord: Intrinsic Distribution
- 2-24** Veins of Vertebral Venous Plexus and Spinal Cord



1. Atlas (C1)
2. T1
3. L1
4. Coccyx
5. Sacrum (S1-5)
6. Lumbar vertebrae
7. Thoracic vertebrae
8. Cervical vertebrae
9. Axis (C2)

Comment: Typically, the vertebral column comprises 7 cervical, 12 thoracic, 5 lumbar, 5 sacral (fused), and 4 coccygeal (last 3 fused) vertebrae.

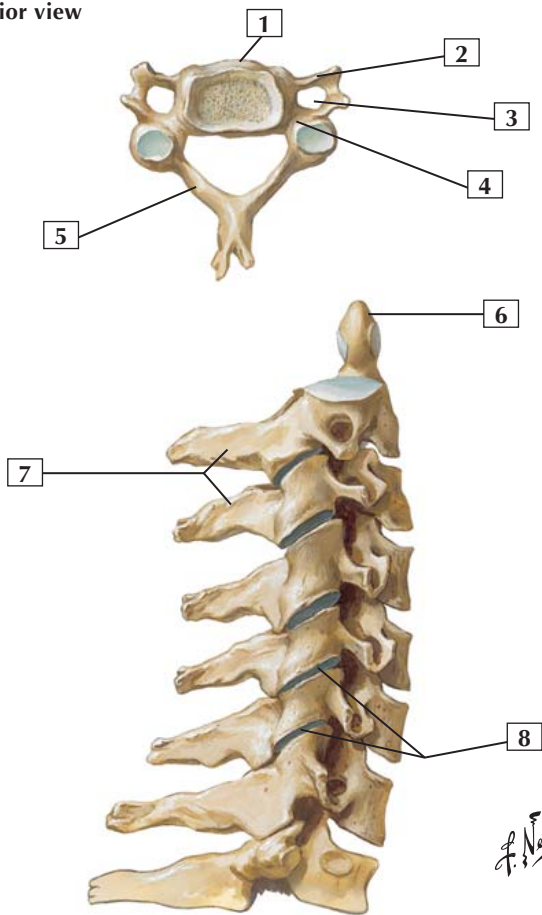
Primary curvatures of the vertebral column include the thoracic curvature and sacral curvature. Secondary curvatures include the cervical curvature and lumbar curvature. Secondary curvatures develop during infancy as children begin to bear the weight of the head, sit up, stand, and support their own weight.

The cervical and lumbar spine allow for greater movement than the other regions of the vertebral column.

Note from the illustration that intervertebral discs separate individual bodies of the adjacent vertebrae (except between the first 2 cervical vertebrae, atlas and axis, and the fused sacrum and coccyx).

Clinical: An accentuated lateral and rotational curvature of the thoracic or lumbar spine is called scoliosis. An accentuated flexion of the thoracic spine is kyphosis (hunchback), and an accentuated extension of the lumbar spine is lordosis (swayback).

Superior view



1. Body
2. Transverse process
3. Transverse foramen
4. Pedicle
5. Lamina
6. Dens
7. Spinous processes
8. Zygapophyseal joints

Comment: The first 2 cervical vertebrae are the atlas and axis (see Section 1, Head and Neck for a description).

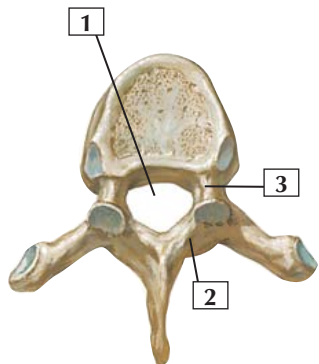
The cervical spine allows for considerable movement.

A typical cervical vertebra has a body, pedicle, lamina, and spinous process.

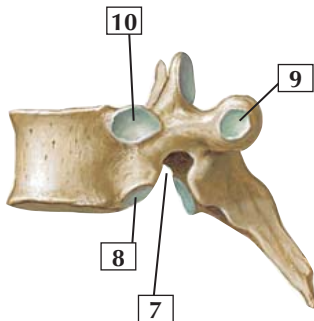
The transverse processes of the cervical vertebrae contain the transverse foramen, which allows for passage of the vertebral vessels.

The lower illustration shows the articulated cervical vertebrae from C2 to C7 and the 1st thoracic vertebra. The 7th cervical vertebra is called the vertebra prominens because of its long spinous process. The intervertebral discs between adjacent vertebrae have been removed.

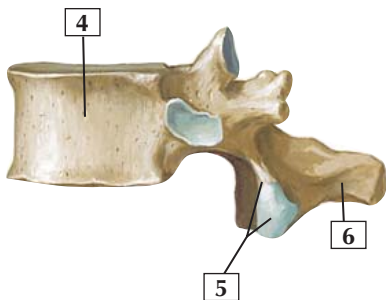
Clinical: Cervical disc herniation (a herniation of the nucleus pulposus) usually occurs in the absence of trauma and is often related to dehydration of the nucleus pulposus. Motor and sensory loss may occur if the herniation compresses a nerve root or the spinal nerve. Common sites include the C5-6 or C6-7 intervertebral discs.



Superior view



Lateral view



Lateral view

*F. Netter
M.D.*

1. Vertebral foramen
2. Lamina
3. Pedicle
4. Body
5. Inferior articular process and facet
6. Spinous process
7. Inferior vertebral notch
8. Inferior costal facet
9. Transverse costal facet
10. Superior costal facet

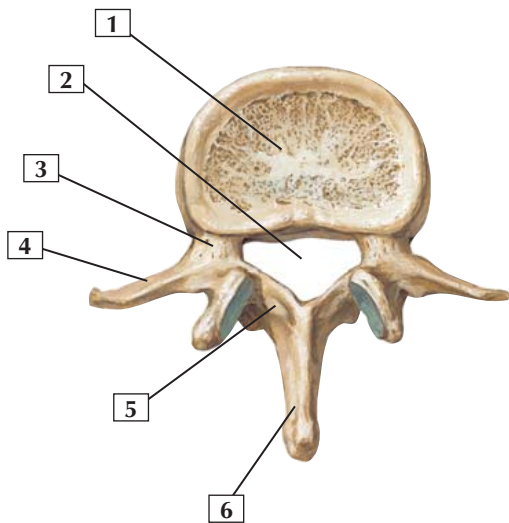
Comment: Typical thoracic vertebrae have costal facets. The superior costal facet articulates with the head of the corresponding rib, the inferior facet articulates with the rib below, and the transverse costal facet articulates with the tubercle of the corresponding rib.

The body, pedicle, and lamina enclose the vertebral foramen, which houses the spinal cord and its meningeal coverings.

The spinous processes of the thoracic vertebrae are long and oriented posteriorly.

The thoracic region of the spine allows for some movement but is constrained by the articulation of the ribs to the vertebrae posteriorly and the sternum anteriorly.

Clinical: The thoracic vertebrae articulate with the ribs and provide a stout “thoracic cage” that protects the thoracic viscera. Movement of the thoracic spine is limited compared with the lumbar and cervical spine.



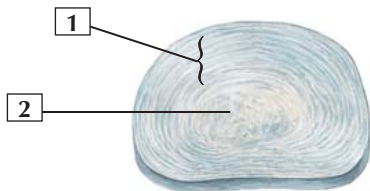
F. Netter
M.D.

1. Vertebral body
2. Vertebral foramen
3. Pedicle
4. Transverse process
5. Lamina
6. Spinous process

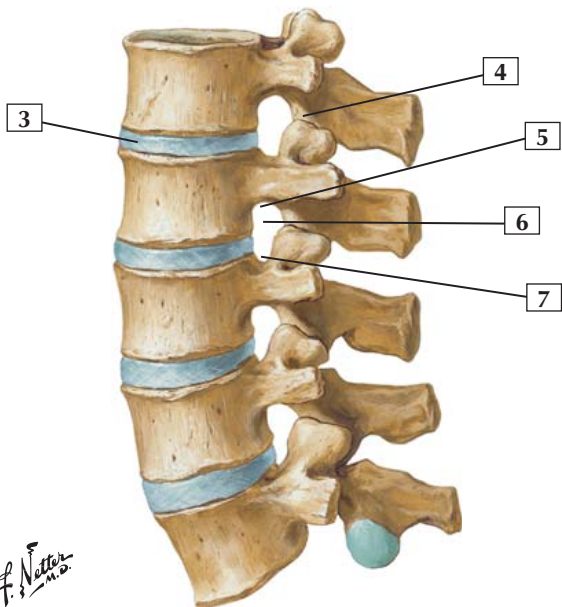
Comment: Typical lumbar vertebrae have large bodies and massive transverse processes. They support the weight of the trunk and provide attachment sites for muscles of the trunk and back.

The lumbar region of the spine allows for considerable movement (flexion, extension, lateral bending, and rotation). Although lumbar vertebrae have long transverse processes for muscle attachment, they do not articulate with ribs.

Clinical: The lumbar spine is designed both for support and movement. Lumbar spinal pain is common and often is due to muscle pain (extensor muscles), ligament pain, or disc-related pain, often affecting a spinal nerve.



Intervertebral disc



Lumbar vertebrae, assembled:
left lateral view

*F. Netter
M.D.*

1. Anulus fibrosus
2. Nucleus pulposus
3. Intervertebral disc
4. Inferior articular process
5. Inferior vertebral notch
6. Intervertebral foramen
7. Superior vertebral notch

Comment: Intervertebral discs form secondary cartilaginous joints (symphyses) between the bodies of 2 adjacent vertebrae. They are present from the axis to the sacrum, but there are no discs between the atlas and axis (C1 and C2). They serve as shock absorbers. A disc consists of a central nucleus pulposus surrounded by a fibrocartilaginous anulus fibrosus.

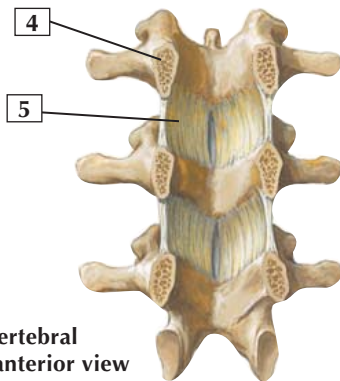
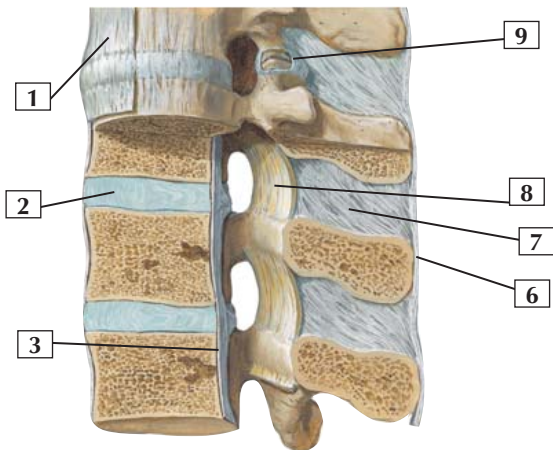
Adjacent inferior and superior vertebral notches form an intervertebral foramen that allows a spinal nerve to exit.

The joints of the vertebral arches are plane synovial joints between the superior and inferior articular processes (facets) that allow for some gliding or sliding movement.

Clinical: An accentuated lumbar lordosis is an abnormal extension of the lumbar spine (swayback) and is common in women during the third trimester of pregnancy when the weight of the fetus places stress on the lower lumbar region.

Disc herniation also is common in the lumbar spine, especially between L4-5 and L5-S1 intervertebral discs.

Left lateral view (*partially sectioned in median plane*)



Posterior vertebral segments: anterior view

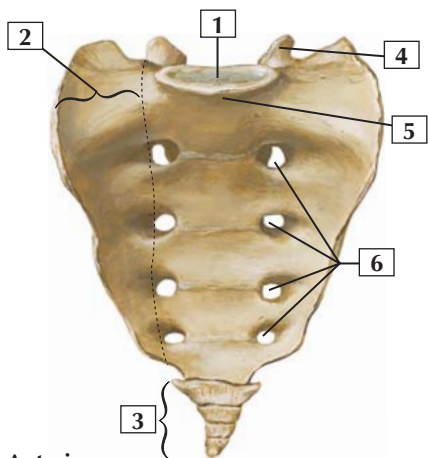
F. Netter M.D.

1. Anterior longitudinal ligament
2. Intervertebral disc
3. Posterior longitudinal ligament
4. Pedicle (*cut surface*)
5. Ligamentum flavum
6. Supraspinous ligament
7. Interspinous ligament
8. Ligamentum flavum
9. Capsule of zygapophyseal joint (*partially opened*)

Comment: Intervertebral discs form secondary cartilaginous joints (symphyses) between the bodies of adjacent vertebrae. They are secured by the anterior and posterior longitudinal ligaments. There is no disc between the atlas and axis.

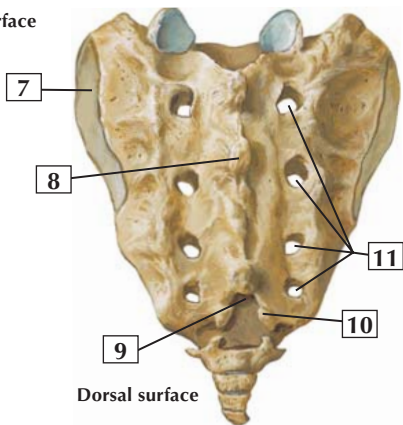
Ligaments of the vertebral column include the anterior and posterior longitudinal ligaments. The former run along the anterior surfaces of the vertebral bodies. The latter run along the posterior surfaces. The ligamentum flavum connects adjacent laminae and limits flexion. Supraspinous (limit flexion) and interspinous (weak ligaments) ligaments run between adjacent spinous processes.

The anterior longitudinal ligaments limit extension of the vertebral column; the posterior longitudinal ligaments limit flexion. The anterior longitudinal ligament is stronger than the posterior longitudinal ligament. The ligamenta flava help support an upright posture.



Anterior
inferior view

Pelvic surface



Dorsal surface

Posterior superior view

F. Netter M.D.

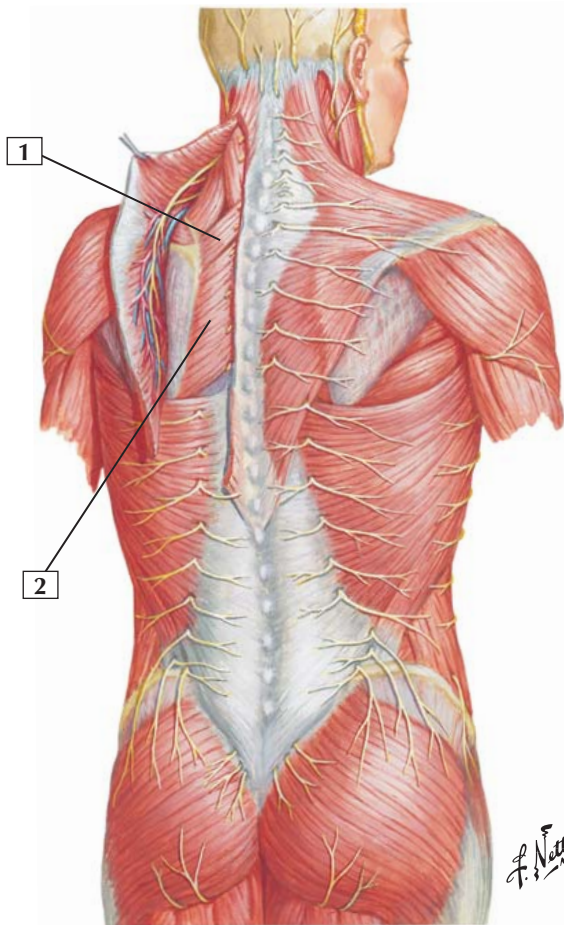
1. Lumbosacral articular surface
2. Ala (lateral part)
3. Coccyx
4. Superior articular process
5. Promontory
6. Anterior (pelvic) sacral foramina
7. Auricular articular surface
8. Median sacral crest
9. Sacral hiatus
10. Sacral cornu (horn)
11. Posterior sacral foramina

Comment: The wedge-shaped sacrum represents the 5 fused sacral vertebrae. Because it forms the posterior aspect of the pelvis, it provides stability and strength to the pelvic architecture.

Four pairs of anterior and posterior sacral foramina provide exits for the ventral and dorsal rami of spinal nerves.

The coccyx is also a wedge-shaped bone; the 1st coccygeal segment is not fused, but the remaining 3 vertebrae are fused.

Clinical: Falling on your “tail bone” can actually fracture the coccyx. The coccyx is a remnant of our embryonic tail, which is present in early development but is largely absorbed leaving no indication of our tail except for the small subcutaneous coccyx. If the remnant persists, it can be cosmetically corrected.



1. Rhomboid minor
2. Rhomboid major

Origin: The rhomboid minor arises from the ligamentum nuchae and the spinous processes of the C7 and T1 vertebrae. The rhomboid major arises from the spinous processes of the T2-5 vertebrae.

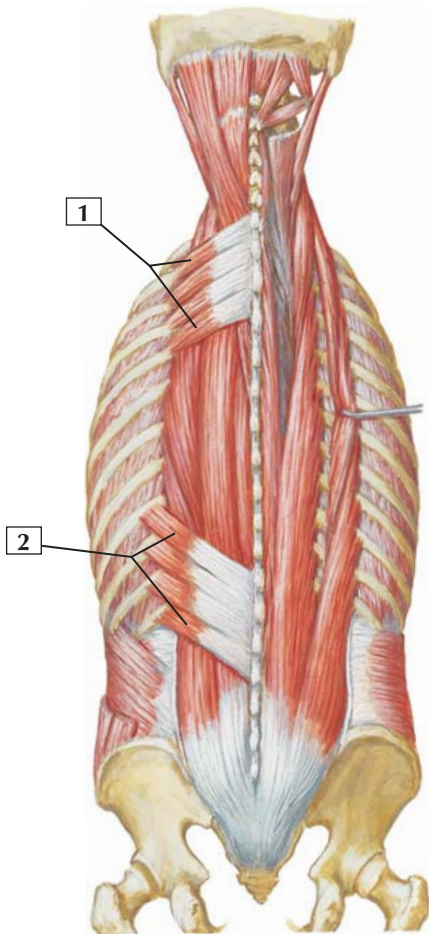
Insertion: The fibers of these 2 muscles often blend together and attach to the medial border of the scapula from about the level of the spine to the inferior angle.

Action: These muscles retract the scapula and rotate it to depress the glenoid cavity. They also fix the scapula to the thoracic wall.

Innervation: Dorsal scapular nerve (C4 and C5).

Comment: The rhomboid minor and rhomboid major muscles are superficial back muscles. Most superficial back muscles have attachments to the scapula and are involved with movements of the upper limb.

Clinical: Damage to the dorsal scapular nerve can weaken the rhomboid muscles, resulting in an ipsilateral lateral shift of the scapula as the pull of the other scapular muscles draws the bone toward the shoulder.



WWW.YAZDANPRESS.COM

Serratus Posterior Superior and Serratus Posterior Inferior

1. Serratus posterior superior
2. Serratus posterior inferior

Origin: The serratus posterior superior attaches to the ligamentum nuchae and the spinous processes of the C7-T3 vertebrae. The serratus posterior inferior attaches to the spinous processes of the T11-L2 vertebrae.

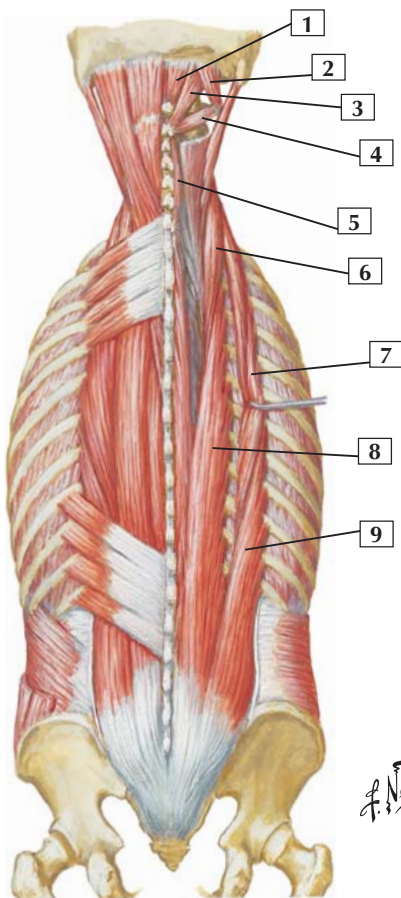
Insertion: Four fleshy digitations attach the serratus posterior superior to the 2nd to 5th ribs. The serratus posterior inferior divides into 4 flat digitations that insert into the inferior borders of the last 4 ribs.

Action: The serratus posterior superior elevates the ribs, whereas the serratus posterior inferior pulls the ribs outward and downward, counteracting the inward pull of the diaphragm.

Innervation: The serratus posterior superior is innervated by the ventral rami of the T1-4 spinal nerves. The serratus posterior inferior is supplied by the ventral rami of the T9-12 spinal nerves.

Comment: These 2 muscles have attachments to the ribs, are considered muscles of the thoracic wall, and act on the ribs during respiration. These 2 muscles are often thin and may be fused to overlying musculature.

Clinical: These 2 sets of muscles are accessory muscles of respiration and may be well developed in athletes. In the elderly, however, they are often thin and even difficult to discern.

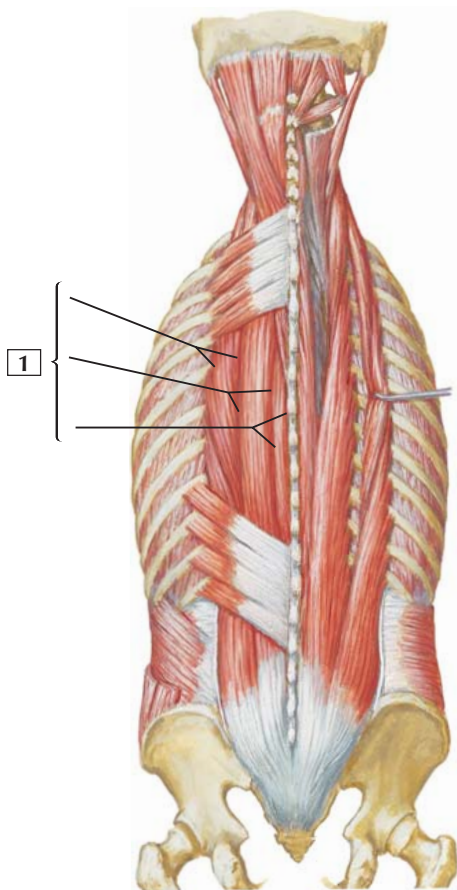


1. Rectus capitis posterior minor
2. Obliquus capitis superior
3. Rectus capitis posterior major
4. Obliquus capitis inferior
5. Spinalis cervicis
6. Longissimus cervicis
7. Iliocostalis thoracis
8. Longissimus thoracis
9. Iliocostalis lumborum

Comment: This plate shows selected muscles of the cervical region (suboccipital region) and back. Subdivisions of the various erector spinae muscles (iliocostalis, longissimus, and spinalis) are shown.

As intrinsic back muscles, all of these muscles are innervated by dorsal rami of the respective spinal nerves.

Clinical: Myofascial back pain is a syndrome that is common but poorly understood. It involves localized musculoskeletal pain (deep aching or burning pain) associated with specific trigger points, usually over the erector spinae muscles that maintain posture, especially in the neck and lower back.



1. Erector spinae

Origin (inferior attachment): The erector spinae comprise the iliocostalis, longissimus, and spinalis. They arise by a broad tendon from the posterior aspect of the iliac crest, the posterior aspect of the sacrum, the sacral and inferior lumbar spinous processes, and the supraspinous ligament.

Insertion (superior attachment): The iliocostalis muscles attach to the angles of lower ribs and the cervical transverse processes.

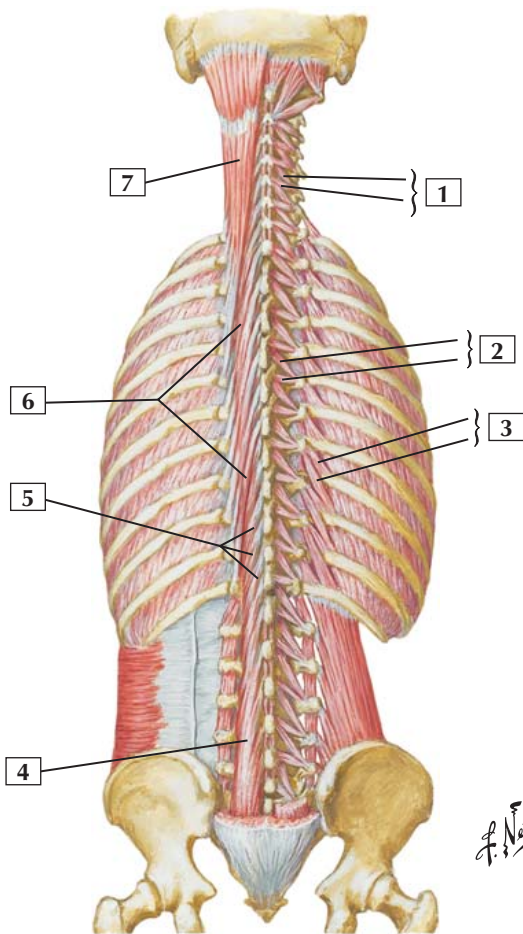
The longissimus muscles attach to the ribs between the tubercles and angles, to the transverse processes in the thoracic and cervical vertebral regions, and to the mastoid process of the temporal bone.

The spinalis muscles attach to the spinous processes in the upper thoracic region and midcervical region and to the skull.

Action: Together, these muscles extend the vertebral column and head. Unilaterally, they bend the vertebral column laterally.

Innervation: By dorsal rami of the respective spinal nerves in each region.

Comment: Because of their locations, the iliocostalis are classified into lumborum, thoracis, and cervicis groups; the longissimus, into thoracis, cervicis, and capitis groups; and the spinalis, into thoracis, cervicis, and capitis groups.

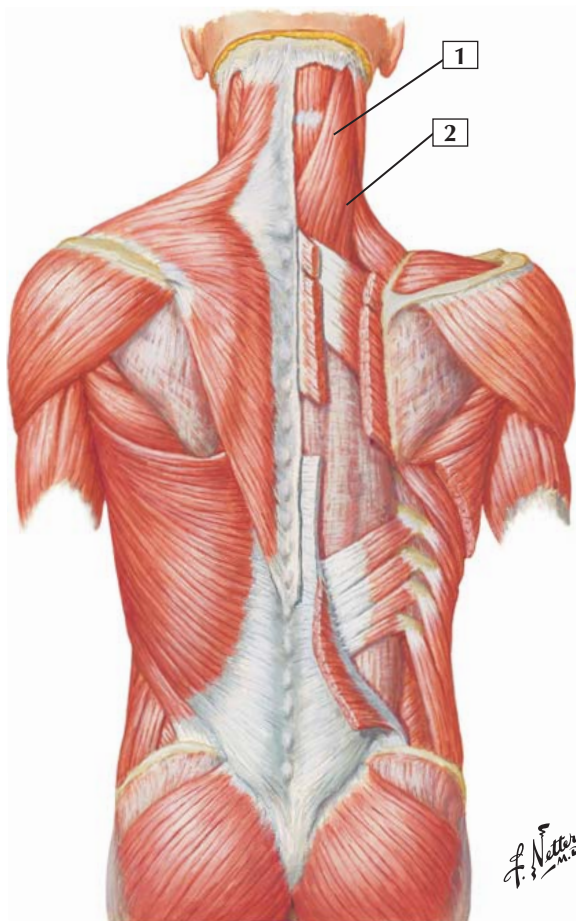


1. Rotatores cervicis (Longus; Brevis)
2. Rotatores thoracis (Longus; Brevis)
3. Levatores costarum (Brevis; Longus)
4. Multifidi
5. Multifidi
6. Semispinalis thoracis
7. Semispinalis capitis

Comment: This plate shows the deepest layer of back muscles, which includes the transversospinal, or paravertebral, muscles. The transversospinal muscles include the semispinalis, multifidi, and rotatores. Most of these muscles arise from the transverse processes of adjacent vertebrae. They pass superiorly to attach to spinous or transverse processes of vertebrae above.

The transversospinal muscles are important for stabilizing the vertebrae during movements of the vertebral column, and they can assist in extension and rotary movements of the vertebrae.

Clinical: Clinicians often refer to the transversospinal muscles simply as the paravertebral muscles because they form a solid mass of muscle tissue interposed between the transverse and spinous processes.



1. Splenius capitis
2. Splenius cervicis

Origin: These muscles blend together and arise from the ligamentum nuchae and the spinous processes of the C7-T6 vertebrae.

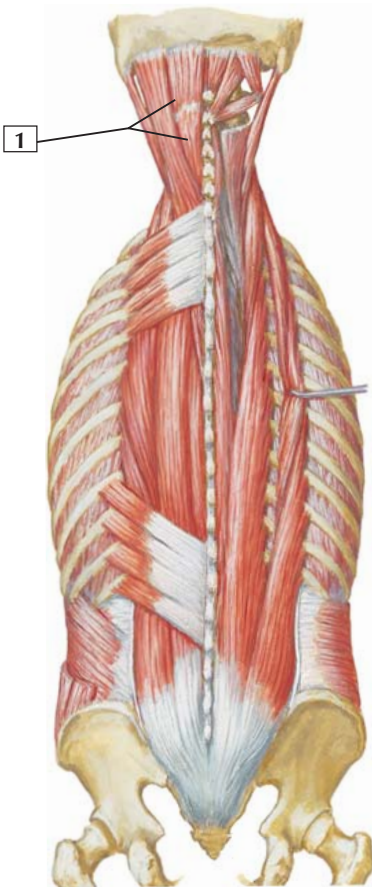
Insertion: Capitis fibers insert into the mastoid process of the temporal bone and the lateral third of the superior nuchal line of the occipital bone. The cervicis fibers ascend to attach to the posterior tubercles of the transverse processes of the C1-3 vertebrae.

Action: Acting with their opposite partners, the splenius capitis and splenius cervicis extend the head and neck. Acting unilaterally, they laterally bend the head and neck to the side of the contraction.

Innervation: The capitis is innervated by the dorsal rami of the middle cervical spinal nerves. The cervicis is innervated by the dorsal rami of the lower cervical spinal nerves.

Comment: The splenius capitis and splenius cervicis form the superficial layer of intrinsic back muscles. Generally, intrinsic back muscles are innervated by dorsal rami of spinal nerves.

Clinical: As intrinsic muscles that extend the neck, these muscles can be involved in neck pain. This pain may be a result of simple muscle tension, holding one's neck in an unusual fixed position for a long period of time (awake or in sleeping), or from hyperextension.



1. Semispinalis capitis

Origin (inferior attachment): Arises by a series of tendons from the transverse processes of the first 6 or 7 thoracic vertebrae and the 7th cervical vertebra.

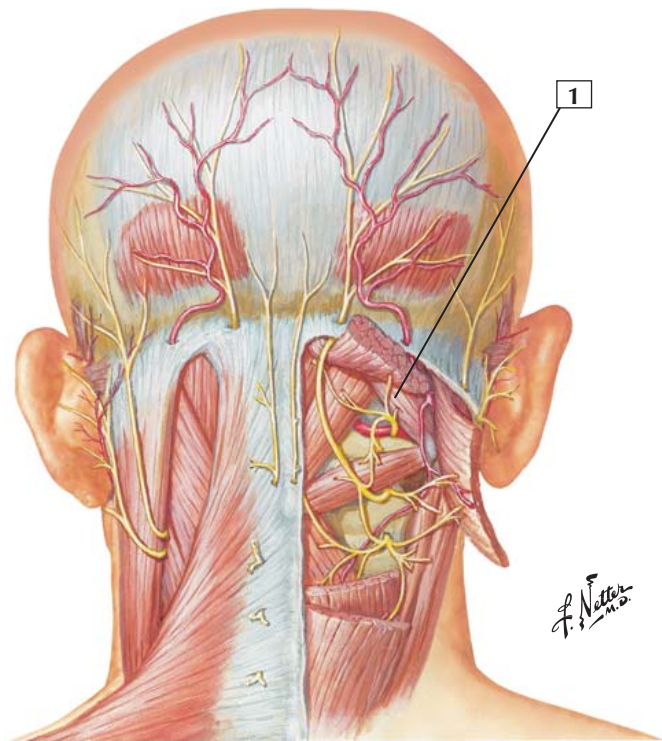
Insertion (superior attachment): This broad muscle inserts between the superior and inferior nuchal lines of the occipital bone.

Action: Extends the head and rotates it so that the face turns toward the opposite side.

Innervation: Dorsal rami of cervical spinal nerves.

Comment: The semispinalis capitis is 1 of 3 groups of semispinalis muscles. The other 2 are the cervicis and thoracis groups.

The semispinalis muscles are part of the transversospinal muscle group, which is situated deep to the erector spinae and fills the concave region between the transverse and spinous processes of the vertebrae. This group of muscles sometimes is referred to as the paravertebral muscles.



1. Obliquus capitis superior

Origin: Arises from the transverse process of the atlas.

Insertion: Attaches to the occipital bone between the superior and inferior nuchal lines.

Action: Extends the head and bends it laterally.

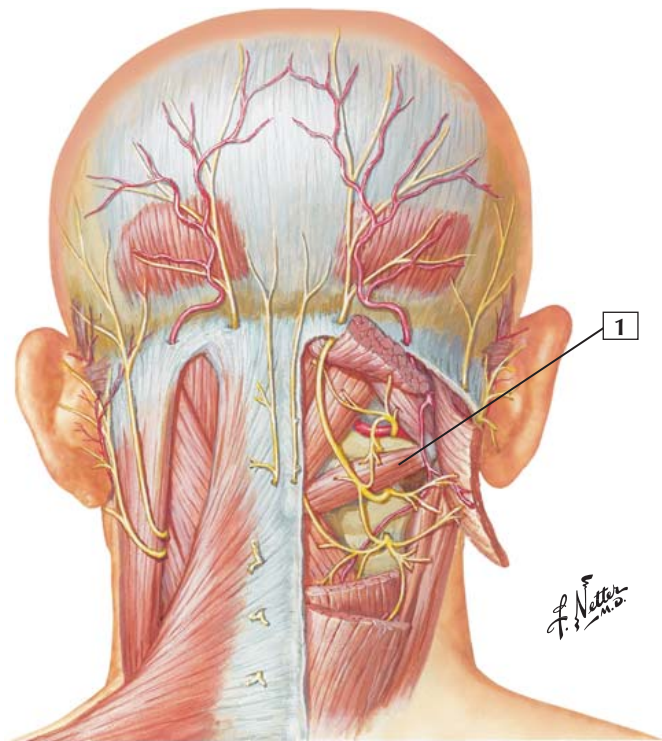
Innervation: Suboccipital nerve (dorsal ramus of C1).

Comment: This muscle helps form the suboccipital triangle. The triangle is bounded by the rectus capitis posterior major, the obliquus capitis superior, and the obliquus capitis inferior. It is located deep to the semispinalis capitis muscle.

Deep within this suboccipital triangle, the vertebral artery (a branch of the subclavian artery in the lower neck) passes through the transverse foramen of the atlas and loops medially to enter the foramen magnum of the skull to supply the brainstem.

The first 3 pairs of the cervical spinal nerves (dorsal rami) are found in this region.

Clinical: The suboccipital nerve (dorsal ramus of C1) is thought to lack a cutaneous sensory component, so when looking at a dermatome map you will notice that the dermatome at the top of the head begins with C2. However, C1 does possess proprioceptive sensory fibers in addition to its somatic and postganglionic sympathetic efferent fibers.



1. Obliquus capitis inferior

Origin: Arises from the spinous process of the axis.

Insertion: Attaches to the inferior and dorsal portions of the transverse process of the atlas.

Action: Rotates the atlas, turning the face toward the same side.

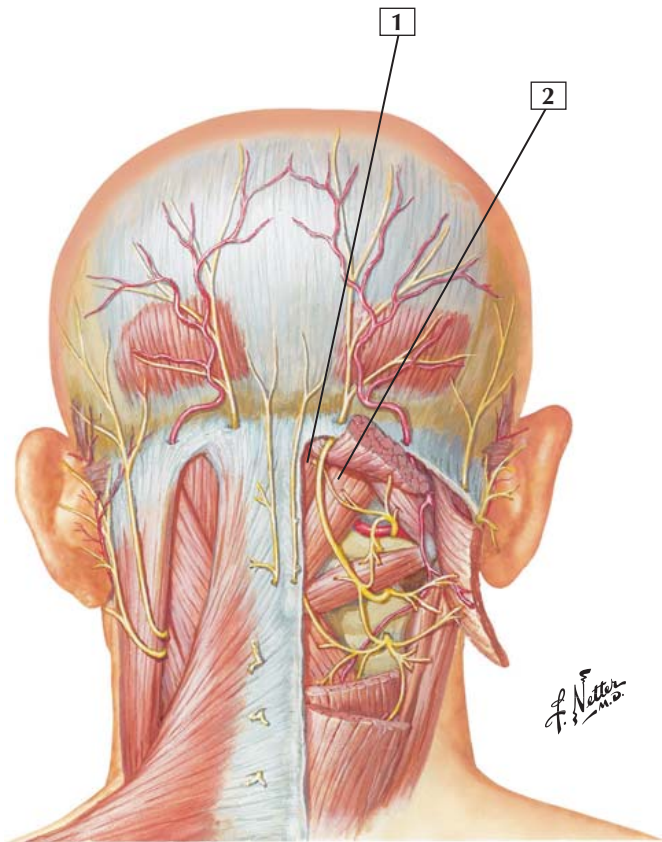
Innervation: Suboccipital nerve (dorsal ramus of C1).

Comment: This muscle of the suboccipital group forms the base of the suboccipital triangle. Deep within the triangle, on the groove on the posterior arch of the atlas, one can see the vertebral artery and the dorsal ramus of the 1st cervical, or suboccipital, nerve.

Deep within this suboccipital triangle, the vertebral artery (a branch of the subclavian artery in the lower neck) passes through the transverse foramen of the atlas and loops medially to enter the foramen magnum of the skull to supply the brainstem.

The first 3 pairs of the cervical spinal nerves (dorsal rami) are found in this region.

**Rectus Capitis Posterior Minor and
Rectus Capitis Posterior Major**



WWW.YAZDANPRESS.COM

Rectus Capitis Posterior Minor and Rectus Capitis Posterior Major

1. Rectus capitis posterior minor
2. Rectus capitis posterior major

Origin: The rectus capitis posterior minor arises from the tubercle of the posterior arch of the atlas. The rectus capitis posterior major arises from the spinous process of the axis.

Insertion: The rectus capitis posterior minor is inserted into the medial part of the inferior nuchal line of the occipital bone. The rectus capitis posterior major is inserted into the lateral portion of the inferior nuchal line of the occipital bone.

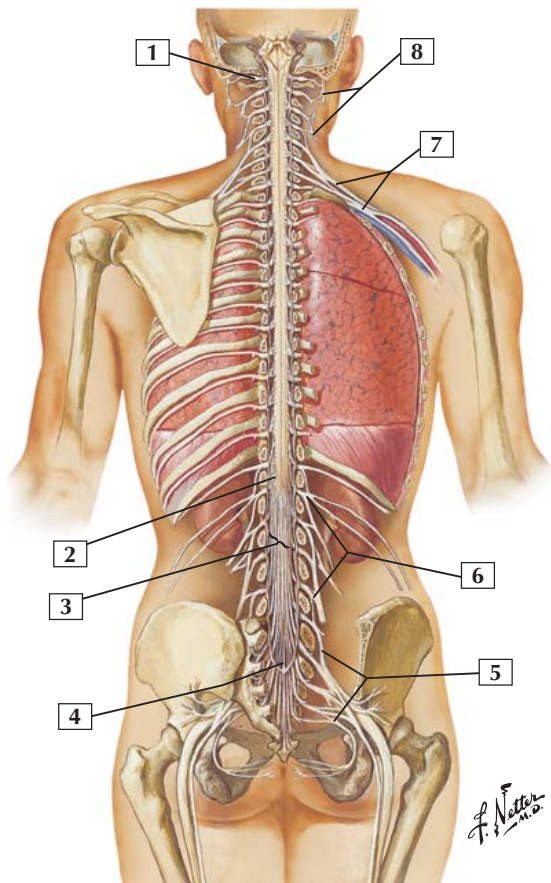
Action: The rectus capitis posterior minor extends the head, whereas the rectus capitis posterior major extends the head and rotates it to the same side.

Innervation: Suboccipital nerve (dorsal ramus of the 1st cervical nerve).

Comment: These 2 muscles are part of the suboccipital muscle group. There are 4 suboccipital muscles on each side of the posterior neck.

Deep within this suboccipital triangle, the vertebral artery (a branch of the subclavian artery in the lower neck) passes through the transverse foramen of the atlas and loops medially to enter the foramen magnum of the skull to supply the brainstem.

The first 3 pairs of the cervical spinal nerves (dorsal rami) are found in this region.



1. C1 spinal nerve
2. Conus medullaris
3. Cauda equina
4. Internal terminal filum (pial part)
5. Sacral plexus
6. Lumbar plexus
7. Brachial plexus
8. Cervical plexus

Comment: The spinal cord is the inferior extension of the brainstem; the cord and the brain make up the central nervous system.

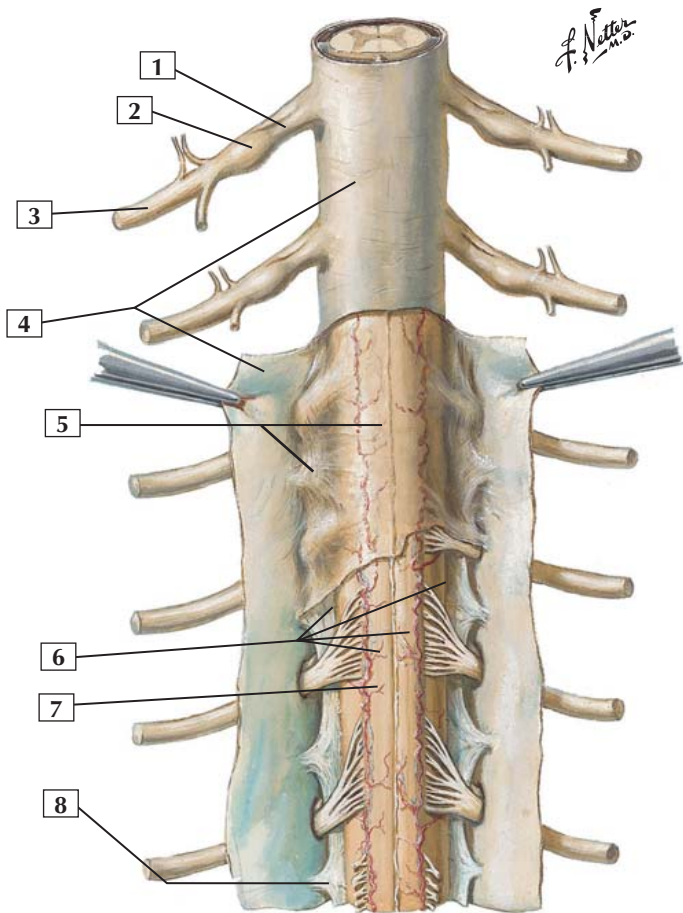
Thirty-one pairs of spinal nerves (8 cervical, 12 thoracic, 5 lumbar, 5 sacral, and 1 coccygeal) course from the spinal cord.

The spinal cord, similar to the brain, is surrounded by 3 meningeal layers. The innermost layer is the pia mater, which is closely applied to the spinal cord. The middle layer is the arachnoid mater. The tough, outer fibrous meningeal layer is the dura mater.

Dorsal and ventral roots of the lumbar and sacral spinal nerves form the cauda equina (horse's tail).

The terminal filum is an extension of pia mater from the tip (conus medullaris) of the spinal cord. It blends with dura at the apex of the dural sac and attaches to the dorsum of the coccyx. It helps anchor the distal spinal cord.

Clinical: A spinal needle may be used to sample the cerebrospinal fluid in the subarachnoid space, and this procedure is done in the lower lumbar region where the needle will not penetrate the spinal cord (the cord ends at the L1 vertebral level). The roots of the cauda equina, bathed and floating in cerebrospinal fluid, will part and allow the needle to enter the subarachnoid space without puncturing a root.



1. Dorsal root of spinal nerve
2. Spinal sensory (dorsal root) ganglion
3. Ventral ramus of spinal nerve
4. Dura mater
5. Arachnoid mater
6. Subarachnoid space
7. Pia mater overlying spinal cord
8. Denticulate ligament

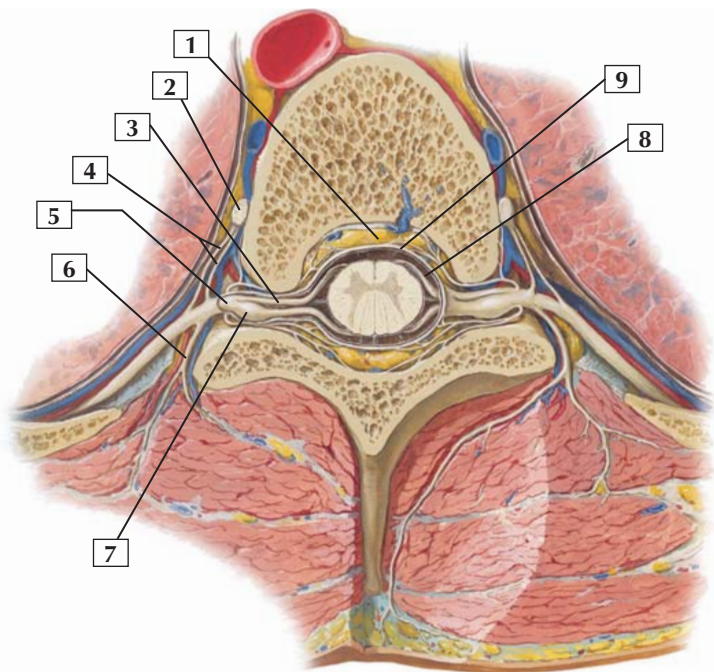
Comment: Dorsal and ventral filaments combine in the intervertebral foramen to form the dorsal and ventral roots of the spinal nerve. Just distal to this point lies the spinal sensory, or dorsal root, ganglion. The dorsal root ganglion contains the sensory nerve cell bodies. Each spinal nerve divides into a very large ventral ramus and a much smaller dorsal ramus.

About 20 pairs of denticulate ligaments anchor the spinal cord to the dura. Denticulate ligaments are pial extensions that pass laterally between the dorsal and ventral roots of spinal nerves to attach to the dura.

The spinal cord is surrounded by 3 meningeal layers: the fibrous, tough outer dura mater, the middle arachnoid mater, and the investing pia mater. Cerebrospinal fluid is found in the space between the arachnoid mater and pia mater (subarachnoid space).

Clinical: The subarachnoid space (brain and spinal cord) contains about 150 mL of cerebrospinal fluid. The pressure of this fluid can be measured or sampled for laboratory analysis to determine if an infection is present somewhere in the central nervous system.

Section through thoracic vertebra



*F. Netter
M.D.*

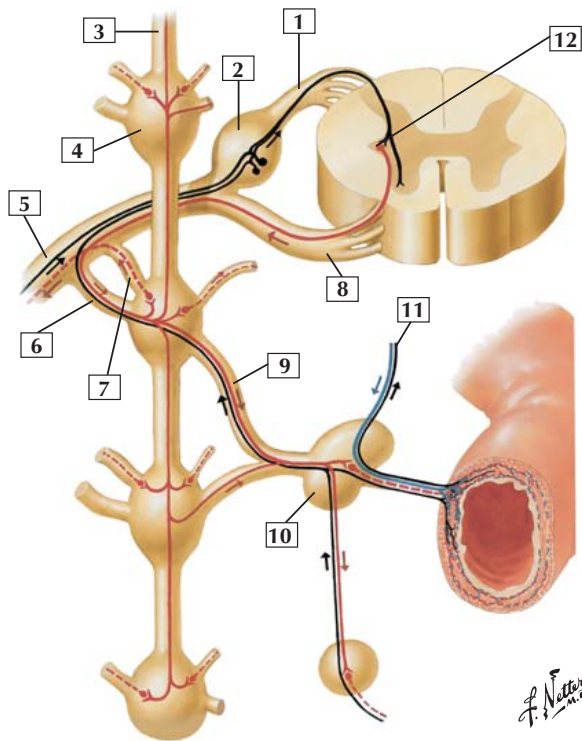
1. Fat in epidural space
2. Sympathetic ganglion
3. Ventral root
4. White and gray rami communicantes
5. Spinal nerve
6. Dorsal ramus
7. Spinal sensory (dorsal root) ganglion
8. Subarachnoid space
9. Dura mater

Comment: The ventral ramus connects to the sympathetic chain ganglia by rami communicantes. White and gray rami communicantes are found between T1 and L2 spinal cord levels, but only gray ramus communicans is found at the other levels.

Ventral and dorsal roots join to form the spinal nerve in the intervertebral foramen. The spinal nerve immediately divides into a small dorsal ramus, which supplies the skin and intrinsic back muscles, and a much larger ventral ramus.

The epidural space (between the dura mater and the bony vertebral canal) is filled with fat and a rich vertebral venous plexus. The subarachnoid space (between the arachnoid and pia mater) contains cerebrospinal fluid.

Clinical: Any pathologic process that narrows the size of the intervertebral foramen (excessive growth of adjacent bone, a tumor, an abscess) can impinge on the dorsal or ventral roots or spinal nerve and cause symptoms related to the nerve fibers carried in those roots or nerve.



F. Netter M.D.

- | | | |
|----------------------|------------------------|----------------------------------|
| Sympathetic fibers | Parasympathetic fibers | — Afferent fibers to spinal cord |
| — Preganglionic | — Preganglionic | |
| - - - Postganglionic | - - - Postganglionic | |

WWW.YAZDANPRESS.COM

Thoracic Spinal Nerve and Connections to Sympathetic Trunk

1. Dorsal root
2. Dorsal root ganglion
3. Sympathetic trunk
4. Sympathetic chain ganglion
5. Ventral ramus (dorsal ramus not shown)
6. White ramus communicans
7. Gray ramus communicans
8. Ventral root
9. Thoracic splanchnic nerve
10. Celiac ganglion
11. Vagus nerve (CN X)
12. Intermediolateral cell column

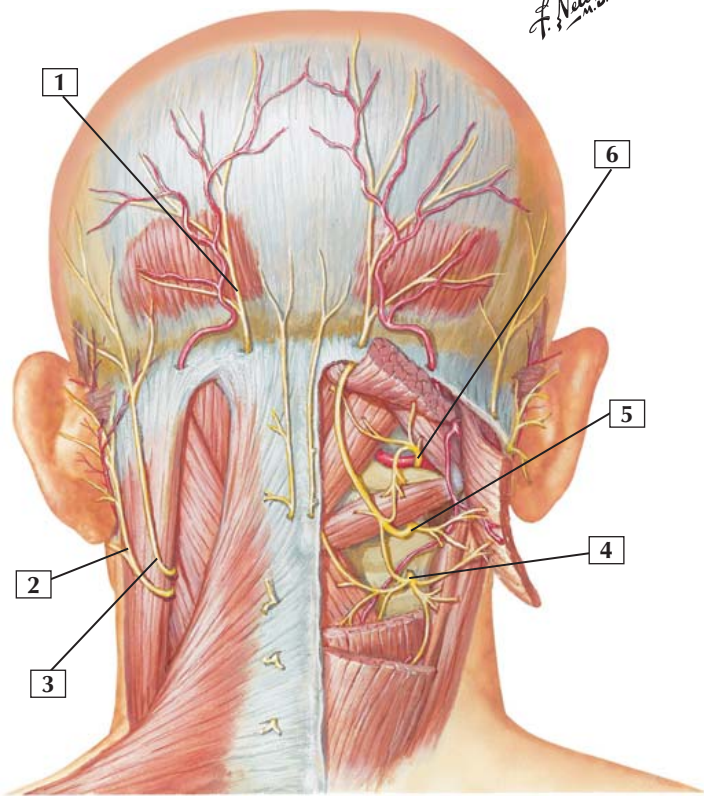
Comment: Afferent (sensory) nerve fibers (*shown in black*) return to the spinal cord via the thoracic splanchnic nerve (pain sensation from viscera) and via the spinal nerve. The cell bodies of these sensory nerve fibers reside in the dorsal root ganglion.

Preganglionic sympathetic efferent (motor) nerve fibers (*shown in red*) originate from neurons in the intermediolateral cell column of the thoracic spinal cord, leave the cord via the ventral root, and enter the sympathetic chain via a white ramus communicans. Here the nerve may continue via a thoracic splanchnic nerve to the celiac ganglion to synapse, pass up or down the sympathetic chain to synapse at a higher or lower level chain ganglion, or synapse in the chain ganglion at the spinal cord level where it exited the cord.

When the preganglionic fiber has synapsed on the postganglionic neuron (in a chain ganglion or the celiac ganglion), postganglionic fibers course to innervate viscera, smooth muscle, glands, or arrector pili muscles of the skin (attached to hair follicles).

Parasympathetic efferent fibers in this schematic illustration course to the viscera via the vagus nerve. Reflex afferents from the viscera return to the brainstem also via the vagus nerve.

*F. Netter
M.D.*



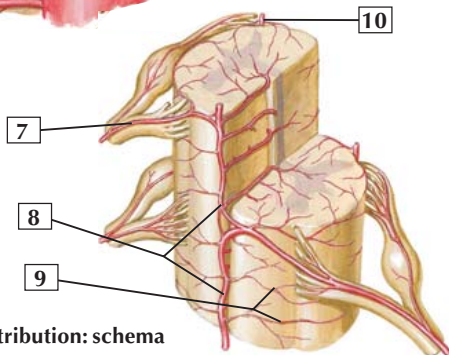
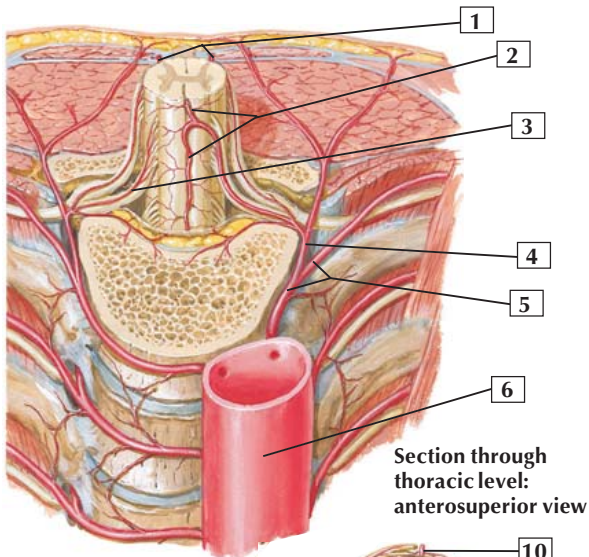
1. Greater occipital nerve (dorsal ramus of C2 spinal nerve)
2. Great auricular nerve (cervical plexus C2 and C3)
3. Lesser occipital nerve (cervical plexus C2 and C3)
4. 3rd (least) occipital nerve (dorsal ramus of C3 spinal nerve)
5. Greater occipital nerve (dorsal ramus of C2 spinal nerve)
6. Suboccipital nerve (dorsal ramus of C1 spinal nerve)

Comment: The suboccipital region comprises muscles in the deep, posterior aspect of the neck, and these muscles are associated with the atlas and axis (C1 and C2 vertebrae).

These muscles are largely postural, but they also assist with head movements. The muscles of the suboccipital region are innervated by the dorsal ramus of C1, the suboccipital nerve.

The first 3 pairs of cervical spinal nerves (dorsal rami) are found in this region. Generally, the suboccipital nerve (dorsal ramus of C1) does not possess cutaneous sensory nerve fibers, so dermatome charts showing the back and top of the head begin with C2, rather than depicting a C1 dermatome.

Arteries of Spinal Cord:
Intrinsic Distribution



F. Netter M.D.

WWW.YAZDANPRESS.COM

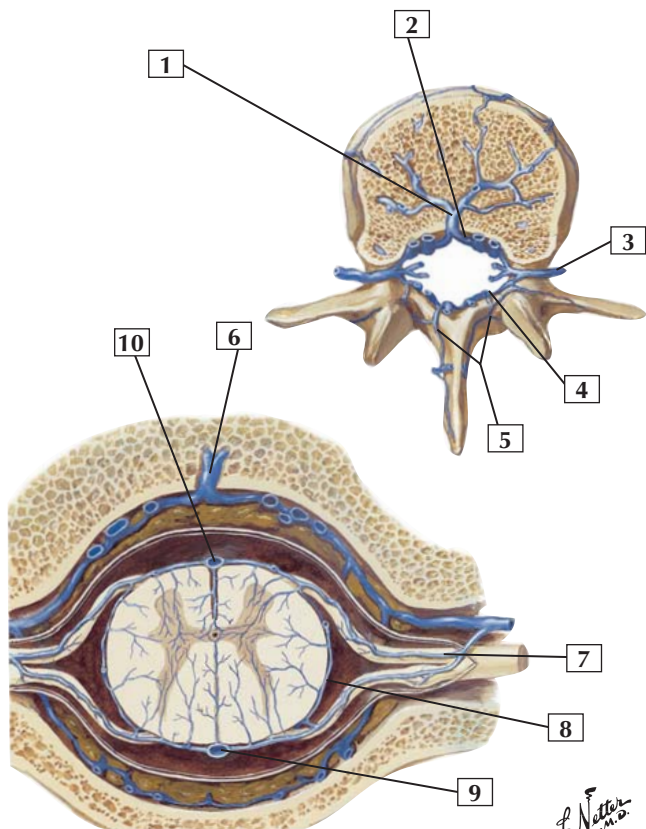
Arteries of Spinal Cord: Intrinsic Distribution

1. Posterior spinal arteries
2. Anterior spinal artery
3. Anterior radicular artery
4. Dorsal branch of posterior intercostal artery
5. Posterior intercostal artery
6. Thoracic (descending) aorta
7. Anterior segmental medullary artery
8. Anterior spinal artery
9. Pial arterial plexus
10. Right posterior spinal artery

Comment: Arteries supplying the spinal cord are derived from branches of the vertebral, deep cervical, intercostal, and lumbar arteries. Generally, a single longitudinal anterior spinal artery and 2 longitudinal posterior spinal arteries course the length of the spinal cord.

Segmental radicular arteries accompany the dorsal and ventral roots of the spinal nerves. Anastomoses between the anterior and posterior spinal arteries and the segmental medullary branches form a pial arterial plexus.

Clinical: The anterior spinal artery and paired dorsal spinal arteries provide the main blood supply to the spinal cord. However, this supply is supplemented by radicular arteries from the aorta. If the blood flow through these radicular arteries is impaired, such as during surgery, a spinal infarct can result.



F. Netter
M.D.

WWW.YAZDANPRESS.COM

Veins of Vertebral Venous Plexus and Spinal Cord

1. Basivertebral vein
2. Anterior internal vertebral (epidural) venous plexus
3. Intervertebral vein
4. Posterior internal vertebral (epidural) venous plexus
5. Posterior external vertebral venous plexus
6. Basivertebral vein
7. Anterior segmental medullary/radicular vein
8. Pial venous plexus
9. Posterior spinal vein
10. Anterior spinal vein

Comment: Usually, there are 3 anterior and 3 posterior spinal veins. These veins communicate freely with one another and drain into segmental radicular veins.

Veins of the spinal cord and vertebrae form an internal vertebral plexus of veins. These veins communicate with an external vertebral venous plexus surrounding the bony vertebrae. This vertebral venous plexus ultimately drains into intervertebral veins and then into the vertebral veins, ascending lumbar veins, azygos venous system, and inferior vena cava.

The veins of the vertebral venous plexus do not possess valves, and as a result of the large region that they drain (entire spine), they provide a conduit for the spread of cancer cells (metastasis) from one region (e.g., the pelvic region) to distant sites.

Clinical: The vertebral venous plexus (of Batson) is a network of valveless veins that course along the spine and provide a route for venous metastases of cancer cells from distal locations (e.g., the pelvis) to seed the spine and other organs located more proximal (e.g., lungs, brain).

Bones and Joints

- 3-1** Bony Framework of Thorax
- 3-2** Costovertebral Joints

Muscles

- 3-3** External Intercostals
- 3-4** Internal Intercostals
- 3-5** Innermost Intercostals and Transversus Thoracis
- 3-6** Serratus Anterior
- 3-7** Muscles of Respiration
- 3-8** Musculature of Esophagus

Nerves

- 3-9** Typical Thoracic Spinal Nerve
- 3-10** Nerves of Heart
- 3-11** Nerves of Esophagus and Posterior Thoracic Wall

Vessels

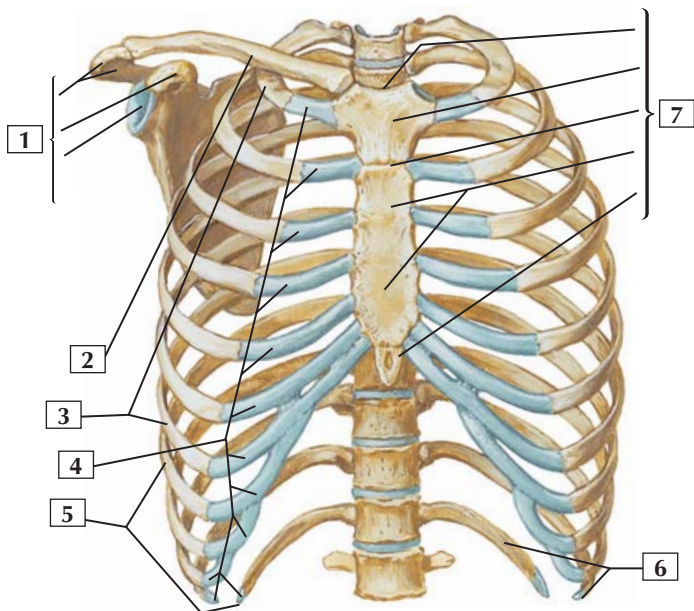
- 3-12** Intercostal Arteries
- 3-13** Heart: Anterior Exposure
- 3-14** Coronary Arteries and Cardiac Veins
- 3-15** Arteries of Thoracic Aorta
- 3-16** Azygos Venous System



Viscera

- 3-17** Mammary Gland
- 3-18** Lungs in Situ: Anterior View
- 3-19** Lungs: Medial Views
- 3-20** Heart In Situ
- 3-21** Pericardial Sac
- 3-22** Right Atrium
- 3-23** Right Ventricle
- 3-24** Left Atrium and Ventricle: Flap Opened in Posterolateral Wall of Left Ventricle
- 3-25** Left Atrium and Ventricle: Section with Mitral Valve Cut Away
- 3-26** Valves and Fibrous Skeleton of Heart
- 3-27** Mediastinum: Cross Section at Level of T8 Vertebra

Anterior View



1. Scapula (Acromion; Coracoid process; Glenoid cavity)
2. Clavicle
3. True ribs (1-7)
4. Costal cartilages
5. False ribs (8-12)
6. Floating ribs (11-12)
7. Sternum (Jugular notch; Manubrium; Angle; Body; Xiphoid process)

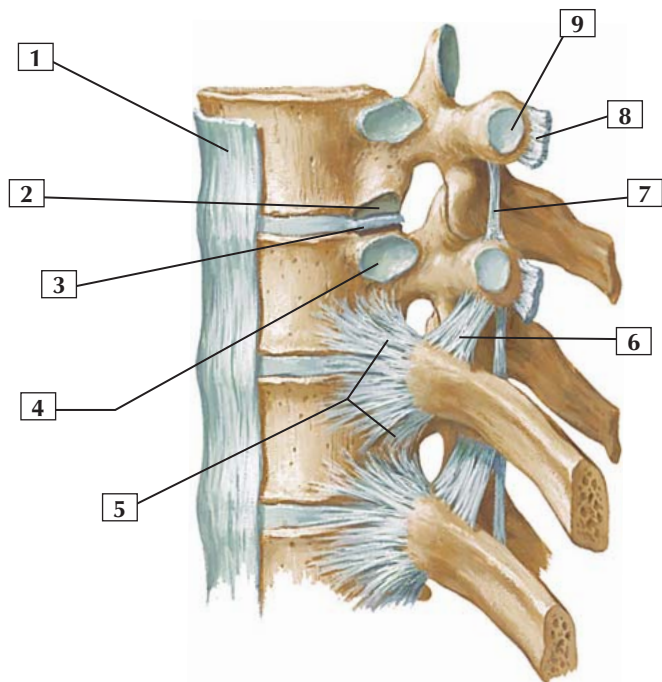
Comment: The thoracic cage is part of the axial skeleton, which also includes the skull and vertebral column. Bones of the thorax include the sternum, the 12 pairs of ribs, and their respective articulations. The clavicle and scapula are part of the pectoral girdle, which is associated with the upper limb.

The articulations of the thorax include the sternoclavicular joint (a saddle-type synovial joint with an articular disc), the sternocostal joints (which are synchondroses), and the costochondral joints (primary cartilaginous).

The opening at the top of the thoracic cage is the superior thoracic aperture, and the opening at the bottom of the cage is the inferior thoracic aperture, which is closed by the abdominal diaphragm.

Clinical: Thoracic cage injuries result from trauma and often involve rib fractures. Ribs 1, 11, and 12 are the least fractured ribs. Rib fractures may occur in a transverse plane or an oblique plane or at multiple sites on the same rib, resulting in a free-floating segment (stove-in or flail chest injury). The pain is intense because of the continued expansion and contraction of the rib cage necessary during respiration.

Left lateral view



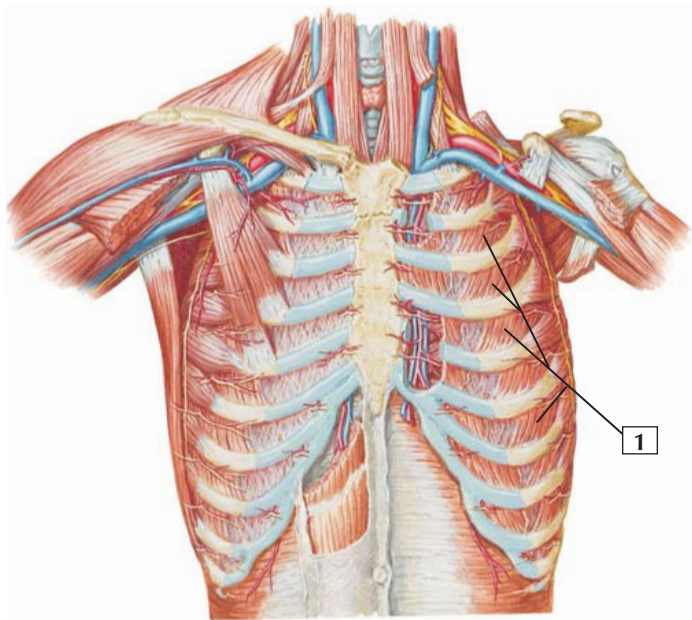
*F. Netter
M.D.*

1. Anterior longitudinal ligament
2. Inferior costal facet (for head of rib 1 number higher than vertebrae)
3. Interarticular ligament of head of rib
4. Superior costal facet (for head of rib of same number)
5. Radiate ligament of head of rib
6. Superior costotransverse ligament
7. Intertransverse ligament
8. Lateral costotransverse ligament
9. Transverse costal facet (for tubercle of rib of same number as vertebra)

Comment: The superior and inferior articular processes (facets) articulate and form plane synovial joints (zygapophyseal joints). Each articulation is surrounded by a thin capsule. Accessory ligaments unite the laminae, transverse processes, and spinous processes. These articulations permit some gliding movements between adjacent vertebrae during flexion, extension, and limited lateral bending.

Costovertebral joints are plane synovial joints between the head of the rib and the costal facets of the vertebrae. Costotransverse plane synovial joints (ribs 1-10) occur between the tubercle of the rib and the transverse process. Gliding movements occur at these joints.

Clinical: Osteoarthritis is the most common type of arthritis and often involves erosion of the articular cartilage of weight-bearing joints, including the facet (zygapophyseal) joints.



*F. Netter
M.D.*

1. External intercostals

Origin (superior attachment): Arises from the lower border of a rib.

Insertion (inferior attachment): Attaches to the upper border of the rib below.

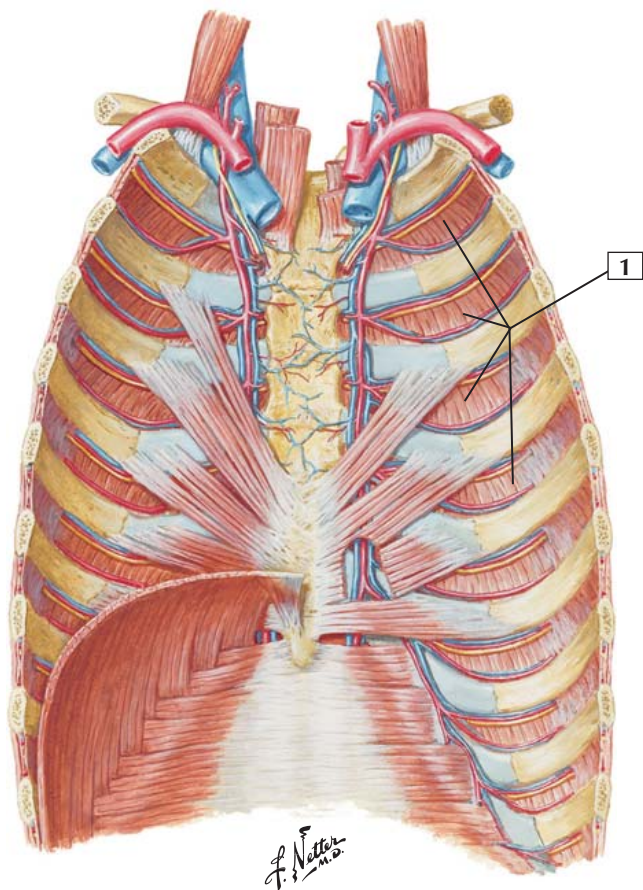
Action: It is generally accepted that the external intercostal muscles are active during inspiration and that they elevate the ribs.

Innervation: These muscles are innervated by intercostal nerves, which are numbered sequentially according to the intercostal interspace. The 4th intercostal nerve supplies muscles that occupy the 4th intercostal space, between the 4th and 5th ribs.

Comment: Because these muscles fill the intercostal spaces, there are 11 external intercostal muscles on each side of the thorax.

All of the intercostal muscles keep the intercostal spaces rigid, preventing them from bulging out during expiration and being drawn in during inspiration.

Clinical: Whereas the diaphragm is the primary muscle of respiration (used almost exclusively in neonates and during quiet respiration), the intercostals do assist the diaphragm and, along with other accessory muscles of respiration (e.g., the scalene muscles), can become hypertrophied if a respiratory pathologic process occurs (e.g., chronic obstructive pulmonary disease).



1. Internal intercostals

Origin (superior attachment): These muscles arise from a ridge on the inner surface of the inferior aspect of each rib and from the corresponding costal cartilage.

Insertion (inferior attachment): They attach to the upper border of the rib below.

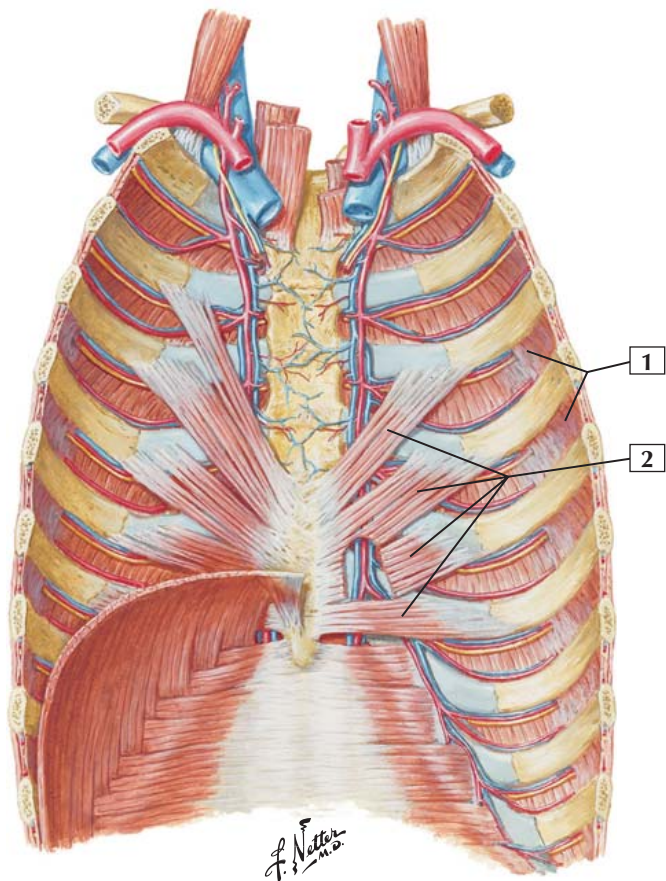
Action: The portions of the upper 4 or 5 internal intercostal muscles that interconnect with the costal cartilages elevate the ribs. The more lateral and posterior portions of the muscles, where the fibers run more obliquely, depress the ribs and are active during expiration.

Innervation: Intercostal nerves.

Comment: In general, the fibers of the internal intercostals are roughly perpendicular to those of the external intercostal muscles.

All of the intercostal muscles keep the intercostal spaces rigid, preventing them from bulging out during expiration and being drawn in during inspiration.

Clinical: The intercostal muscles assist in respiration and can hypertrophy if a respiratory pathologic process develops (e.g., chronic obstructive pulmonary disease such as asthma or emphysema).



Innermost Intercostals and Transversus Thoracis

1. Innermost intercostals
2. Transversus thoracis

Origin: The innermost intercostals arise from the lower border of the ribs. The transversus thoracis arises from the posterior surface of the lower portion of the body of the sternum and the xiphoid process.

Insertion: The innermost intercostals attach to the upper border of the rib below. The transversus thoracis attaches to the inner surface of costal cartilages 2-6.

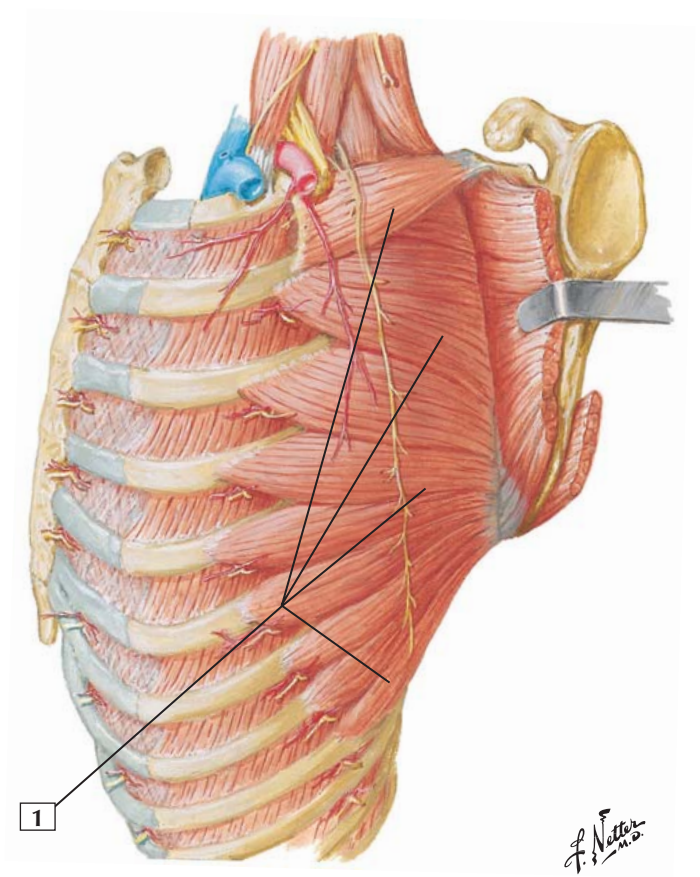
Action: The action of the innermost intercostals is controversial, but these muscles are thought to elevate the ribs. The transversus thoracis muscle depresses the ribs.

Innervation: Intercostal nerves.

Comment: The innermost intercostal muscles frequently are poorly developed and may be fused to the overlying internal intercostals.

The transversus thoracis muscle is variable in its attachments.

All of the intercostal muscles keep the intercostal spaces rigid, preventing them from bulging out during expiration and being drawn in during inspiration.



1. Serratus anterior

Origin: Arises by fleshy digitations from the outer surfaces and superior borders of the first 8 to 9 ribs.

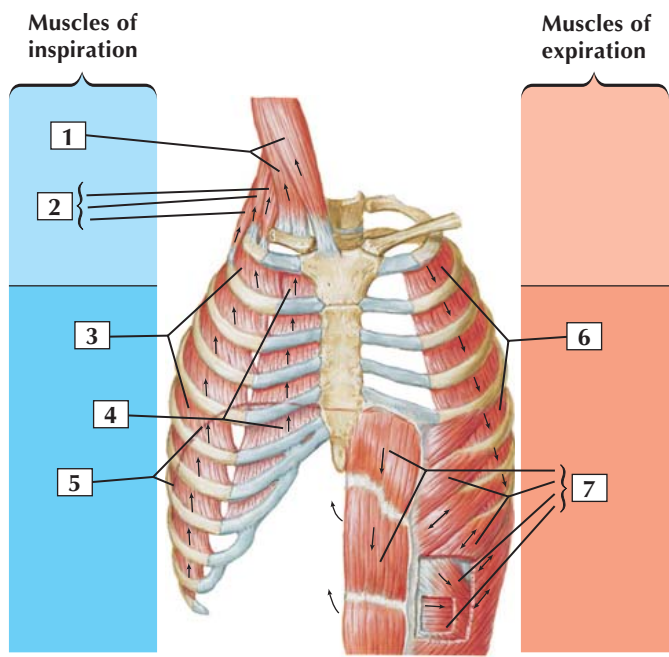
Insertion: The muscle fibers pass backward, closely apply themselves to the chest wall, and insert on the ventral aspect of the vertebral border of the scapula.

Action: This muscle pulls the medial border of the scapula anteriorly toward the thoracic wall, preventing the bone from protruding (winging). Its fibers also rotate the scapula upward by laterally rotating the inferior angle. This action helps abduct the arm at the shoulder. Abduction above 90° (above the horizontal) can be accomplished only by lateral rotation of the inferior angle of the scapula.

Innervation: Long thoracic nerve (C5, C6, and C7).

Comment: The serratus anterior is particularly important in abduction of the arm above 90° .

Clinical: Damage to the long thoracic nerve may lead to “winging” of the scapula, most evident when a patient pushes forward with the upper limb against resistance. In particular, the inferior angle of the scapula is elevated away from the thoracic wall. This type of nerve injury may occur from trauma to the lateral thoracic wall or from lateral flexion of the neck to the opposite side, causing a stretch injury to the nerve.



F. Netter M.D.

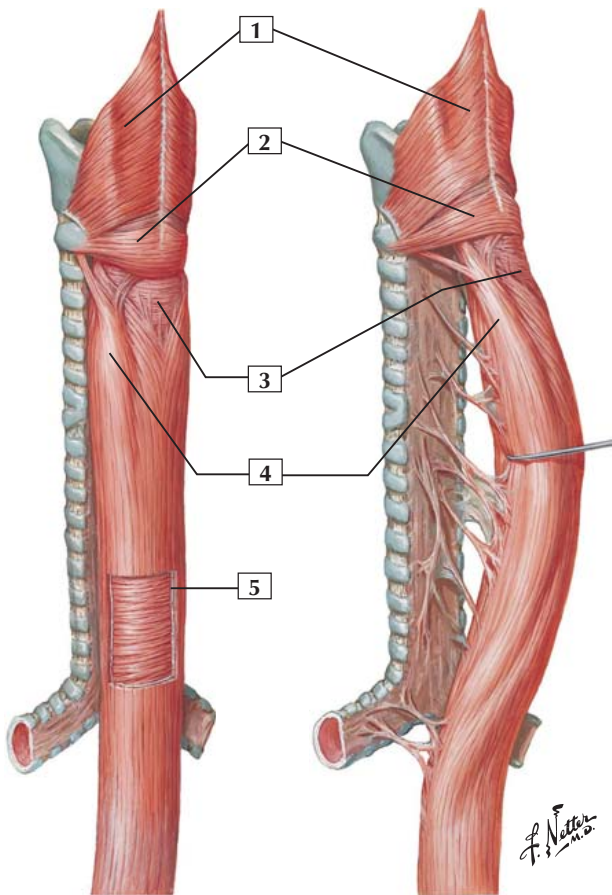
1. Sternocleidomastoid
2. Scalenes (Anterior; Middle; Posterior)
3. External intercostals
4. Interchondral part of internal intercostals
5. Diaphragm (phantom)
6. Internal intercostals except interchondral part
7. Abdominals (Rectus abdominis; External oblique; Internal oblique; Transversus abdominis)

Comment: The principal muscles of inspiration are the external intercostals, the interchondral portion of the internal intercostals, and the diaphragm. Accessory muscles of inspiration include the sternocleidomastoid and the scalenes.

During quiet breathing, the elastic recoil of the lungs and the rib cage account for expiration. Forced expiration involves the internal intercostals and various abdominal muscles.

All of the intercostal muscles keep the intercostal spaces rigid, preventing them from bulging out during expiration and being drawn in during inspiration.

Clinical: Hypertrophy of the accessory muscles of respiration can be significant if a pulmonary pathologic process increases the effort required to breathe. For example, in emphysema, the normal elasticity of the lung is compromised, which makes exhalation of air difficult. Under such conditions, the patient will recruit the accessory muscles of respiration to help expel the air from the lungs. Such patients may present with a “barrel” chest (round, expanded chest wall) appearance.

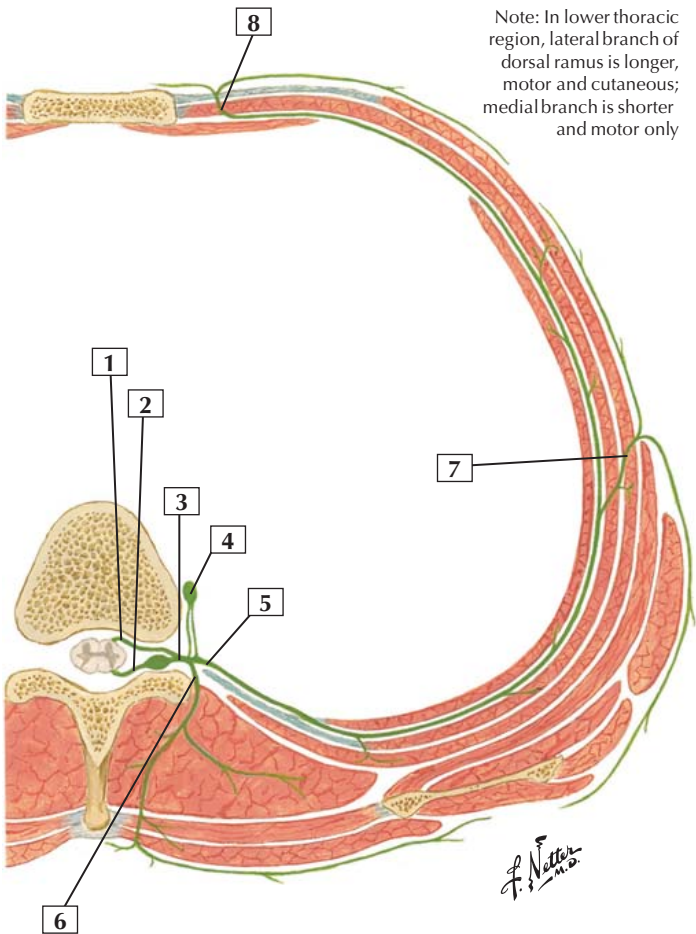


1. Inferior pharyngeal constrictor muscle
2. Cricopharyngeus (muscle) part of inferior pharyngeal constrictor
3. Circular muscle layer with sparse longitudinal fibers
4. Lateral mass of longitudinal muscle
5. Window cut in longitudinal muscle layer (revealing circular muscle layer)

Comment: The esophagus is a muscular canal that extends from the pharynx to the stomach. Its muscular coat is organized into 2 planes: an external plane of longitudinal fibers and an internal plane of circular fibers. The esophageal muscle transitions from skeletal to smooth muscle as it descends from the pharynx to the stomach.

Clinical: The esophagus has 4 narrowed regions along its length where a swallowed object may become lodged or erode the mucosa as it passes through this region. These constricted regions include:

- Where the pharynx becomes continuous with the proximal esophagus
- Where the aortic arch crosses the esophagus
- Where the esophagus is compressed by the left main bronchus
- Where the esophagus passes through the diaphragm (esophageal hiatus)



Note: In lower thoracic region, lateral branch of dorsal ramus is longer, motor and cutaneous; medial branch is shorter and motor only

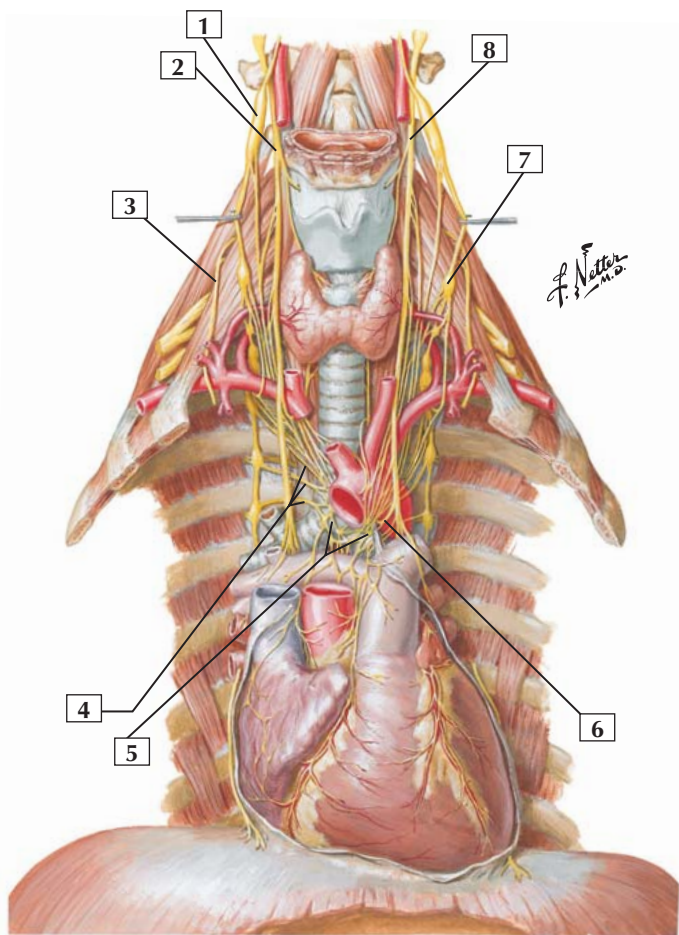
F. Netter M.D.

1. Ventral root
2. Dorsal root
3. Spinal nerve
4. Sympathetic ganglion
5. Ventral ramus (intercostal nerve)
6. Dorsal ramus
7. Lateral cutaneous branch
8. Anterior cutaneous branch

Comment: This thoracic nerve is a typical example of a spinal nerve. Dorsal and ventral roots combine to form the spinal nerve, which divides into a small dorsal ramus that supplies the intrinsic muscles of the back and a larger ventral ramus (intercostal nerve) that innervates all the muscles lining the trunk. The ventral ramus divides into a lateral cutaneous branch at the midaxillary line; anteriorly, and laterally to the sternum, it gives rise to an anterior cutaneous branch. The intercostal nerves course between the internal intercostal and innermost intercostal muscles.

The first 11 thoracic nerves give rise to ventral rami that constitute the intercostal nerves (T12 is the subcostal nerve, and it is inferior to the 12th rib). Intercostal arteries and veins accompany the intercostal nerves (not shown in this illustration).

Clinical: Thoracic ventral rami (intercostal nerves) run in the costal groove at the inferior margin of each rib; physicians must be aware of this positioning when entering the intercostal space (for injections or chest tube placements).



1. Superior cervical sympathetic ganglion
2. Vagus nerve (CN X)
3. Phrenic nerve
4. Thoracic (sympathetic) cardiac branches
5. Cardiac plexus
6. Recurrent laryngeal nerve
7. Middle cervical sympathetic ganglion
8. Vagus nerve (CN X)

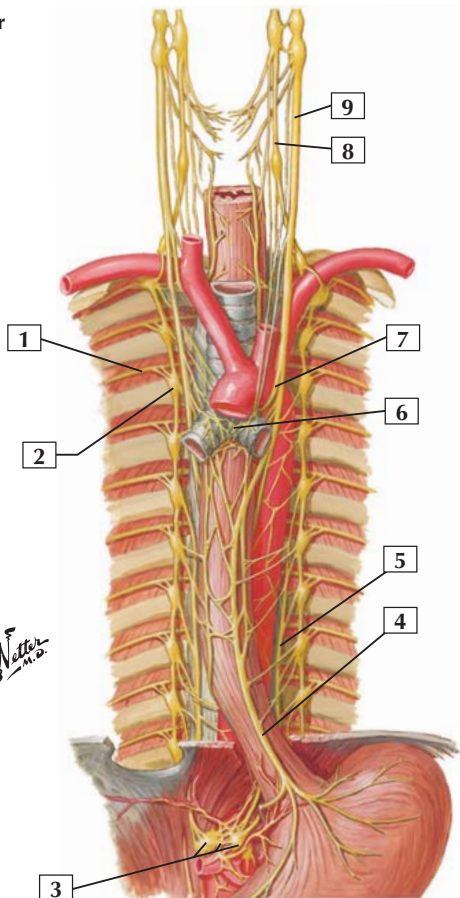
Comment: The cardiac muscle of the heart is innervated by the autonomic nervous system. Sympathetic contributions to the cardiac plexus arise from cardiac nerves that originate largely from the cervical portions of the sympathetic trunk (although their preganglionic fibers arise from neurons in the upper 4 thoracic spinal cord levels) but also send direct thoracic cardiac branches medially toward the heart.

The parasympathetic contributions come from the vagus nerve (CN X). Together, the parasympathetic and sympathetic branches form a rich cardiac plexus around the great vessels arising from the heart and around the bifurcation of the trachea.

Sympathetic innervation to the heart increases heart rate and contractile force, whereas parasympathetic innervation decreases heart rate.

Clinical: Pain sensation from myocardial ischemia, called angina pectoris, is conveyed to the upper 4 thoracic spinal cord levels via the sympathetic pathways, accounting for referred pain over the T1-4 dermatome regions, primarily on the left side. This pain may be initially interpreted by the patient as somatic pain (musculoskeletal) rather than pain from the ischemic cardiac muscle of the heart.

Anterior view



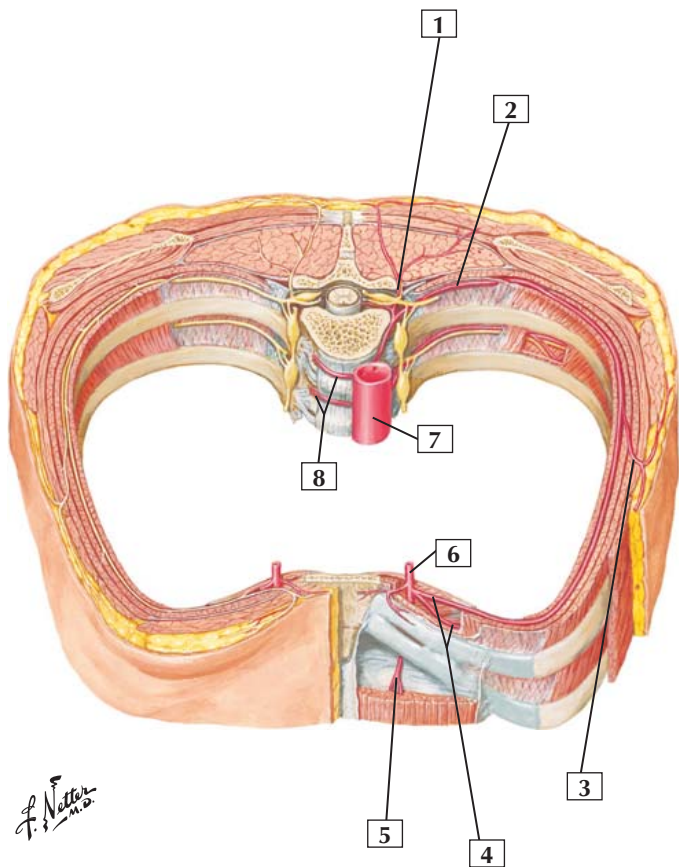
Nerves of Esophagus and Posterior Thoracic Wall

1. 3rd intercostal nerve
2. 3rd thoracic sympathetic ganglion
3. Celiac plexus and ganglia
4. Anterior vagal trunk
5. Left greater splanchnic nerve
6. Cardiac plexus
7. Left recurrent laryngeal nerve
8. Cervical sympathetic trunk
9. Vagus nerve (CN X)

Comment: Nerves of the esophagus and posterior thoracic wall include somatic nerves (thoracic intercostal nerves) and autonomic nerves. The thoracic spinal cord segments give rise to intercostal nerves, which are connected by rami communicantes to the sympathetic trunk. In the thorax, the latter gives rise to the greater, lesser, and least splanchnic nerves, which course through the diaphragm to the abdomen.

The parasympathetic contributions to this region are via the vagus nerve. As they pass through the diaphragm, the left and right vagus nerves form a plexus on the esophagus. Sympathetic and parasympathetic fibers contribute to a rich cardiac plexus of nerves.

Clinical: A mass in the posterior mediastinum may present as pain, neurologic symptoms, or difficulty swallowing. The most common masses include tumors of the peripheral nerves or their sheath cells (e.g., schwannomas), or tumors or diverticula of the esophagus.



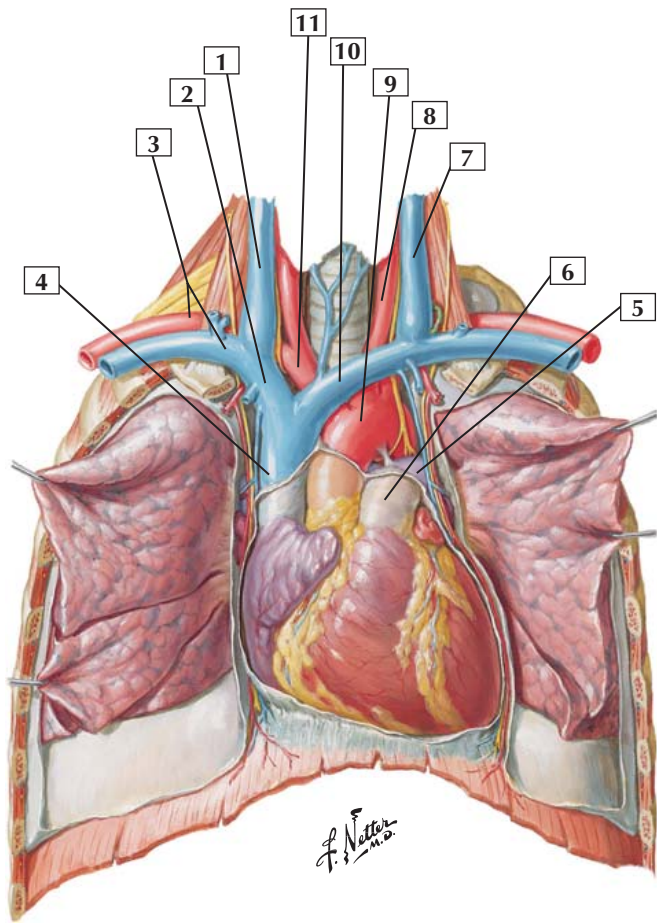
*F. Netter
M.D.*

1. Dorsal branch of posterior intercostal artery
2. Posterior intercostal artery
3. Lateral cutaneous branch of posterior intercostal artery
4. Anterior intercostal arteries
5. Superior epigastric artery
6. Internal thoracic artery
7. Thoracic aorta
8. Right posterior intercostal arteries (*cut*)

Comment: Posterior intercostal arteries arise from the thoracic aorta bilaterally and course along the inferior margin of each rib between the innermost intercostal muscles and internal intercostal muscles. At the midaxillary line, these intercostal vessels give rise to a lateral cutaneous artery. Anteriorly, the intercostal vessels anastomose with the anterior intercostal arteries arising from the internal thoracic (mammary) artery.

Intercostal veins and nerves also course with the intercostal arteries (in this illustration, the arteries are shown on just one side and nerves on the other side; intercostal veins are not shown).

Clinical: Because of the location of the major intercostal neurovascular bundle (nerve, artery, and vein) just inferior to each rib (costal groove), any injections or tubes placed into the intercostal space should occur closer to the superior edge of the rib margin to avoid piercing the neurovascular bundle.



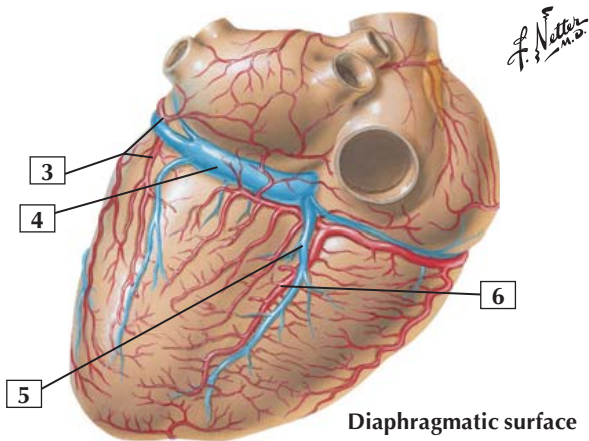
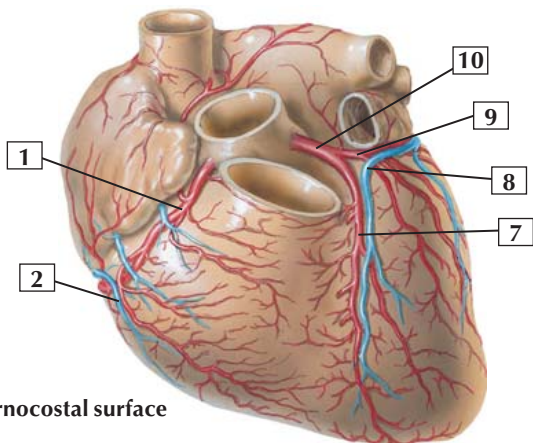
1. Right internal jugular vein
2. Right brachiocephalic vein
3. Subclavian artery and vein
4. Superior vena cava
5. Left pulmonary artery
6. Pulmonary trunk
7. Left internal jugular vein
8. Left common carotid artery
9. Arch of aorta
10. Left brachiocephalic vein
11. Brachiocephalic trunk

Comment: The union of the internal jugular veins, which drain the head and neck region, and the subclavian veins, which drain the upper limbs, forms a right and left brachiocephalic vein. The 2 brachiocephalic veins join to form the superior vena cava.

The pulmonary trunk receives blood from the right ventricle and divides into right and left pulmonary arteries. The aorta receives blood from the left ventricle and arches over the pulmonary trunk, continuing inferiorly as the thoracic aorta.

The pericardium has been incised anteriorly to show the heart resting on the diaphragm. Likewise, the pleura have been incised to view the lungs.

Clinical: Cardiac tamponade can result from fluid accumulation or bleeding into the pericardial cavity. The accumulated fluid can compromise the heart's ability to contract and relax effectively, thus decreasing venous return and cardiac output.



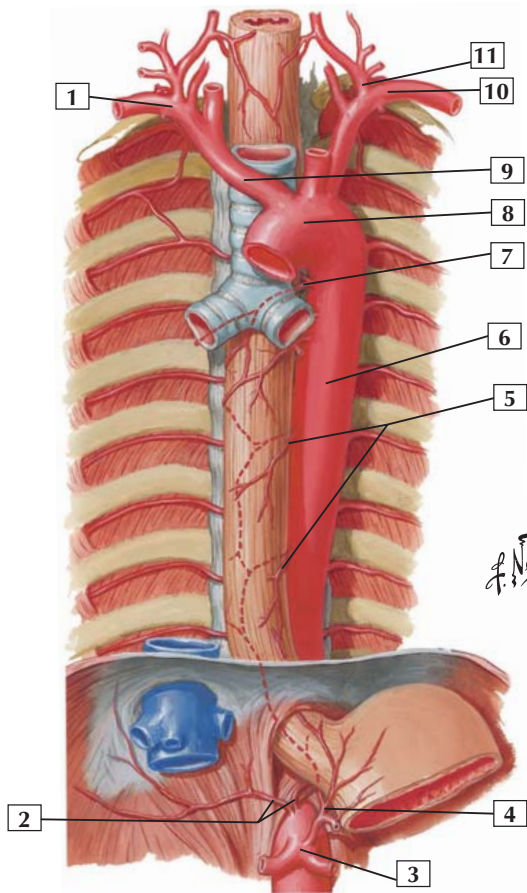
1. Right coronary artery
2. Small cardiac vein
3. Circumflex branch of left coronary artery
4. Coronary sinus
5. Middle cardiac (posterior interventricular) vein
6. Posterior interventricular branch (posterior descending) of right coronary artery
7. Anterior interventricular branch (left anterior descending) of left coronary artery
8. Great cardiac (anterior interventricular) vein
9. Circumflex branch of left coronary artery
10. Left coronary artery

Comment: The right coronary artery arises from the ascending aorta and generally supplies the right atrium, most of the right ventricle, the diaphragmatic surface of the left ventricle, part of the atrioventricular septum, the sinoatrial node (60% of the time), and the atrioventricular node (80% of the time).

The left coronary artery also arises from the ascending aorta, and its branches usually supply the left atrium, most of the left ventricle, some of the right ventricle, most of the interventricular septum, the sinoatrial node (40% of the time), and the atrioventricular node (20% of the time).

The coronary sinus is the largest vein draining the heart. It receives blood from the great, middle, and small cardiac veins and drains into the right atrium.

Clinical: In cases of coronary artery occlusion leading to cardiac ischemia and a myocardial infarct, 40-50% of these cases occur in the proximal portion of the left anterior descending branch of the left coronary artery.

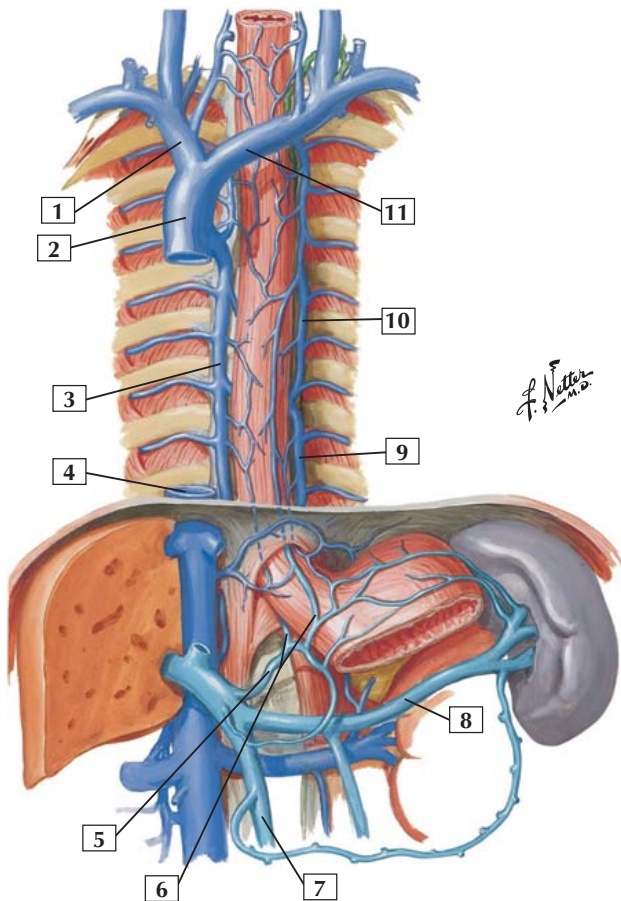


1. Subclavian artery
2. Inferior phrenic arteries
3. Celiac trunk
4. Esophageal branch of left gastric artery
5. Esophageal branches of thoracic aorta
6. Thoracic (descending) aorta
7. Right bronchial artery
8. Arch of aorta
9. Brachiocephalic trunk
10. Subclavian artery
11. Thyrocervical trunk

Comment: The thoracic aorta is the direct continuation of the arch of the aorta. The thoracic aorta gives rise to bronchial, esophageal, pericardial, mediastinal, posterior intercostal, subcostal, and superior phrenic arteries.

The esophagus and descending thoracic aorta are in the posterior mediastinum, deep to the heart, which lies in the middle mediastinum.

Clinical: The small bronchial arteries (usually 1 right and 2 left arteries) are the nutritive arteries (essential nutrients and oxygen) to the pulmonary visceral pleura, bronchi and bronchial glands, and the walls of the larger intrapulmonary arteries.

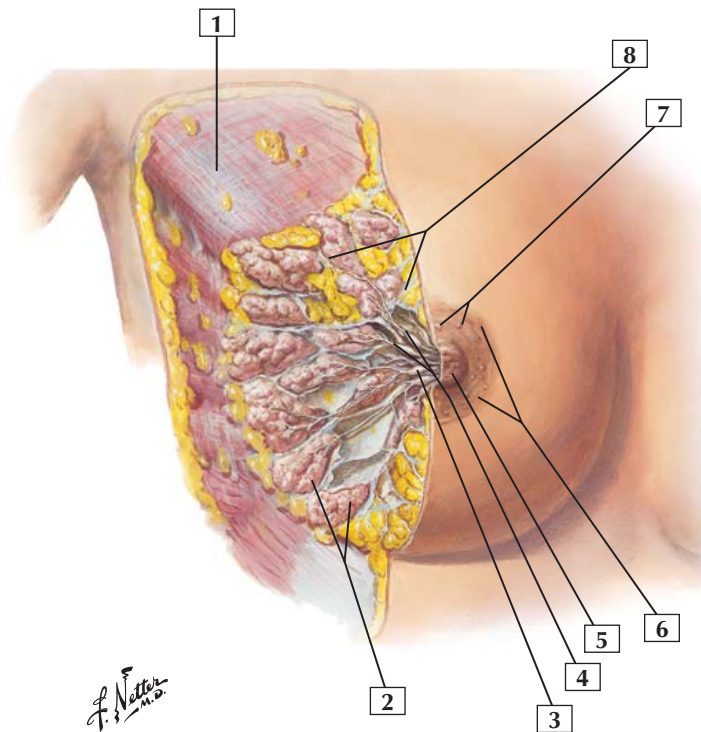


1. Right brachiocephalic vein
2. Superior vena cava
3. Azygos vein
4. Inferior vena cava (*cut*)
5. Left gastric vein
6. Esophageal branches of left gastric vein
7. Superior mesenteric vein
8. Splenic vein
9. Hemiazygos vein
10. Accessory hemiazygos vein
11. Left brachiocephalic vein

Comment: The azygos venous system lies on either side of the vertebral column and drains deep structures of the back, thoracic wall, and abdominal walls. Although variable in anatomy, the azygos vein and its principal tributary, the hemiazygos vein, arise from the inferior vena cava or right ascending lumbar vein, and the left ascending lumbar vein or renal vein, respectively. Ultimately, most of the blood from the azygos system drains into the superior vena cava.

Clinical: The azygos venous system forms an important venous conduit between the inferior vena cava and the superior vena cava. These veins do not contain valves, so blood flow may occur in different directions depending on where the pressure is highest. Via its connections with the left gastric vein in the abdomen, the azygos system is an important component of the portacaval anastomosis in conditions such as portal hypertension.

Anterolateral
dissection



1. Pectoralis major muscle
2. Gland lobules
3. Lactiferous sinus
4. Lactiferous ducts
5. Nipple
6. Areola
7. Areolar glands
8. Suspensory ligaments (Cooper)

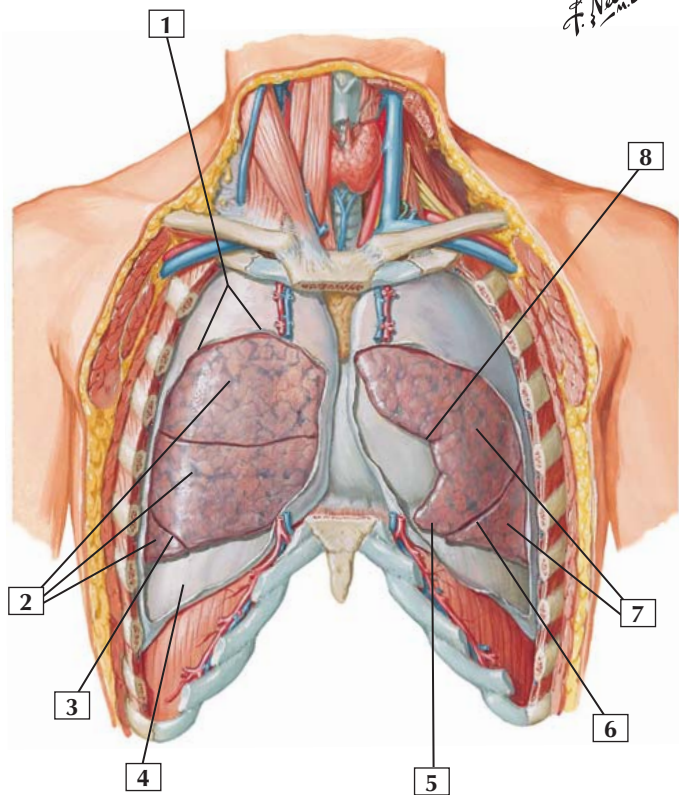
Comment: The mammary gland is a modified sweat gland located in the superficial fascia. Its lobes of glandular tissue are separated by fibrous septa. Each lobe opens to a lactiferous duct that dilates just beneath the nipple to form a lactiferous sinus, or reservoir, for milk during lactation.

The suspensory ligaments (Cooper's ligaments) are strong fibrous connective tissue strands that pass from the dermis of the skin to the superficial fascia through the substance of the breast.

About 75% of the lymphatic drainage of the breast passes to the axillary lymph nodes. Lymph also may drain to infraclavicular nodes, medially to parasternal nodes, or inferiorly to abdominal lymphatics.

Clinical: The breast is divided into quadrants: upper inner, upper outer, lower inner, and lower outer. Approximately 50% of all cancers develop in the upper outer quadrant. Breast cancer is the most common malignancy in women and exceeds the incidence of the next 2 common cancers of lung and colorectal areas combined. Most of these neoplasms are ductal carcinoma.

*F. Netter
M.D.*



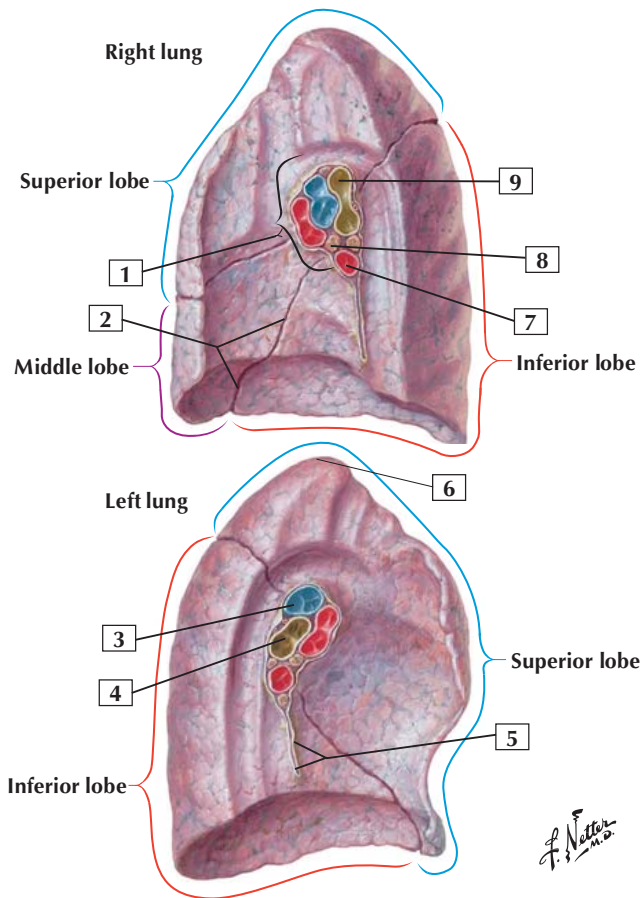
1. Costal part of parietal pleura (*cut away*)
2. Superior, middle, and inferior lobes of right lung
3. Oblique fissure
4. Diaphragmatic part of parietal pleura
5. Lingula of superior lobe of left lung
6. Oblique fissure
7. Superior and inferior lobes of left lung
8. Cardiac notch of left lung

Comment: The lungs lie within pleural cavities containing the parietal and visceral pleura. Parietal pleura lines the inner surface of the thoracic wall, superior aspect of the diaphragm, and the mediastinum; the visceral pleura is intimately associated with the lung surface. Visceral pleura reflects off the lung to become parietal pleura at the hilum, where structures enter and leave lung tissue.

Oblique and horizontal fissures divide the right lung into a superior, middle, and inferior lobe. An oblique fissure divides the left lung into a superior and an inferior lobe. The left lung also contains the lingula, a tongue-shaped portion of the superior lobe. The lingula roughly corresponds to the right lung's middle lobe.

Each lung contains 10 bronchopulmonary segments, each supplied by a segmental bronchus and an artery.

Clinical: The potential space between the parietal and visceral pleura contains only a small amount of serous fluid that lubricates the surfaces and reduces friction during respiration. If fluids or air gain access to this potential space, it becomes a real space, and the pressure can partially compress the lung or collapse it completely.



1. Hilum
2. Oblique fissure
3. Left pulmonary artery
4. Left main bronchus
5. Pulmonary ligament
6. Apex
7. Right inferior pulmonary vein
8. Bronchopulmonary (hilar) lymph nodes
9. Right superior lobar (eparterial) bronchus

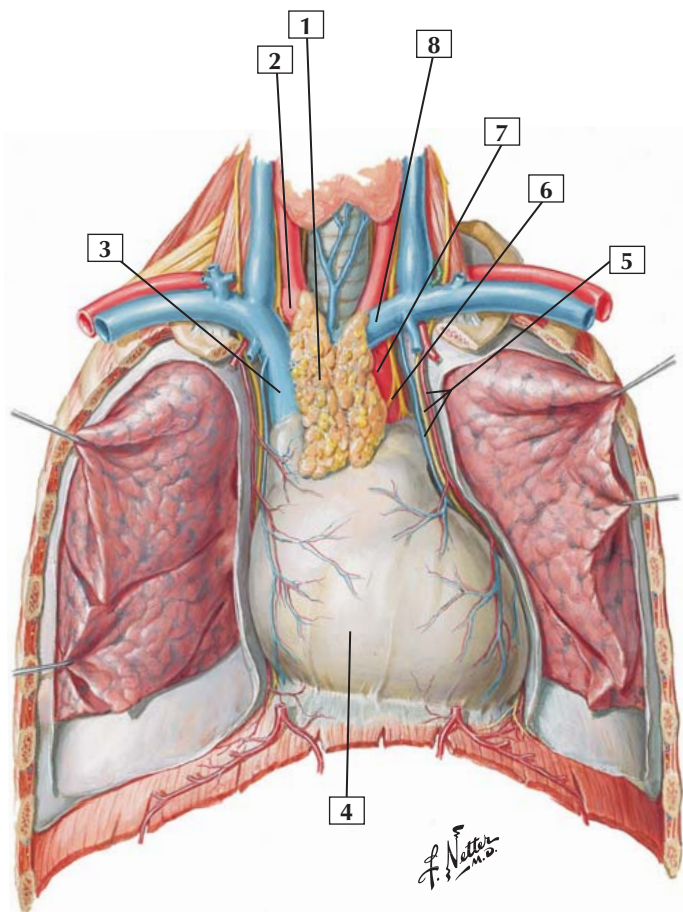
Comment: The hilum of each lung is the point where the pulmonary vessels, bronchi, lymphatics, and nerves enter or leave the lung. At the hilum and along the pulmonary ligament, the visceral pleura reflects from the lung surface to become the parietal pleura lining the mediastinum and inner aspect of the thoracic wall.

Viewed from the hilum of each lung, the bronchi generally lie posteriorly, the pulmonary arteries superiorly, and the pulmonary veins anteriorly and inferiorly.

The right lung has a superior, middle, and inferior lobe, demarcated by the horizontal and oblique fissures. The left lung has a superior and inferior lobe.

Each lung contains 10 bronchopulmonary segments, each supplied by a segmental bronchus and an artery.

Clinical: Lung cancer is the leading cause of cancer-related death and is associated consistently with a 20- to 30-year history of smoking. Lung cancers are highly invasive and rapidly metastasizing tumors. Adenocarcinoma and squamous cell carcinoma are the most common types of lung cancer.



1. Thymus gland
2. Brachiocephalic trunk
3. Superior vena cava
4. Pericardium
5. Phrenic nerve and pericardiophrenic artery and vein
6. Recurrent laryngeal nerve
7. Arch of aorta
8. Left brachiocephalic vein

Comment: The heart lies within the middle mediastinum, encased within a fibroserous sac called the pericardium. The outer layer of the pericardium is the fibrous pericardium, a strong, fibrous layer that blends with the roots of the great vessels. Serous pericardium consists of an underlying parietal layer lining the inner aspect of the fibrous pericardium and a visceral layer that reflects onto the heart as the epicardium.

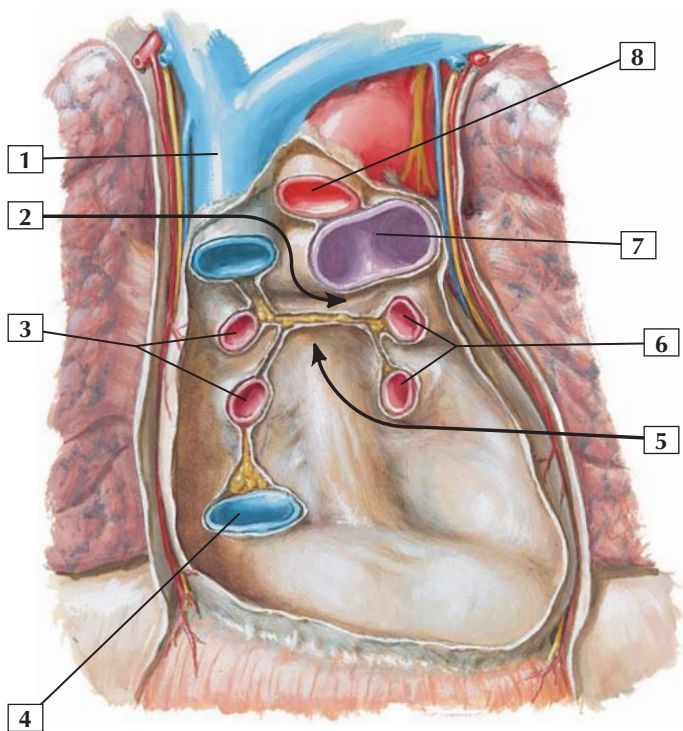
The thymus, often atrophied and imbued with fat in the adult, overlies the great vessels and superior portion of the pericardium. It is usually directly posterior to the manubrium of the sternum.

This figure also shows the mediastinal, diaphragmatic, and costal portions of the parietal pleura.

Clinical: The pericardial cavity is a potential space between the 2 serous layers and contains a thin film of serous lubricating fluid to reduce friction of the beating heart. Trauma to the heart or rupture of a vessel can lead to bleeding in the pericardial cavity, which compresses the heart and compromises its function. This condition is called cardiac tamponade.

Pericarditis is an infection of the pericardium usually caused by a virus, although bacteria and fungi are also causative agents.

Pericardial sac with
heart removed: anterior view



*F. Netter
M.D.*

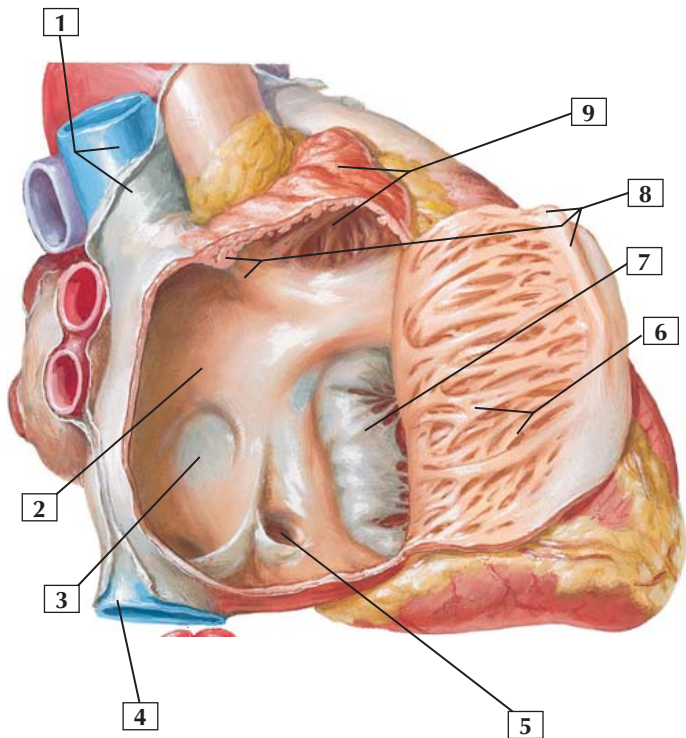
1. Superior vena cava
2. Transverse pericardial sinus
3. Right pulmonary veins
4. Inferior vena cava
5. Oblique pericardial sinus
6. Left pulmonary veins
7. Pulmonary trunk (bifurcation)
8. Ascending aorta

Comment: The pericardial cavity is a potential space between the visceral serous pericardium (epicardium) and the parietal serous pericardium, which lines the inner surface of the fibrous pericardium. The visceral serous pericardium reflects off the heart around these large vessels and becomes the parietal serous pericardial layer. The heart (removed in this illustration) lies within the pericardial sac.

The oblique sinus, a cul-de-sac behind the left atrium of the heart, is another reflection of serous pericardium surrounding the pulmonary veins.

Clinical: The transverse sinus is a space between the reflections of the serous pericardium, which is posterior to the ascending aorta and pulmonary trunk, and anterior to the superior vena cava. This is a clinically important area because clamping these vessels can completely stop ventricular outflow.

Opened right atrium: right lateral view



*F. Netter
M.D.*

1. Superior vena cava
2. Interatrial septum
3. Fossa ovalis
4. Inferior vena cava
5. Opening of coronary sinus
6. Pectinate muscles
7. Septal cusp of tricuspid valve
8. Crista terminalis
9. Right auricle

Comment: The smooth portion of the right atrium is known as the sinus venarum because it develops from the embryonic sinus venosus and receives blood from the superior and inferior venae cavae, and coronary sinus. It is separated from the more muscular portion of the atrium proper by a line, the crista terminalis.

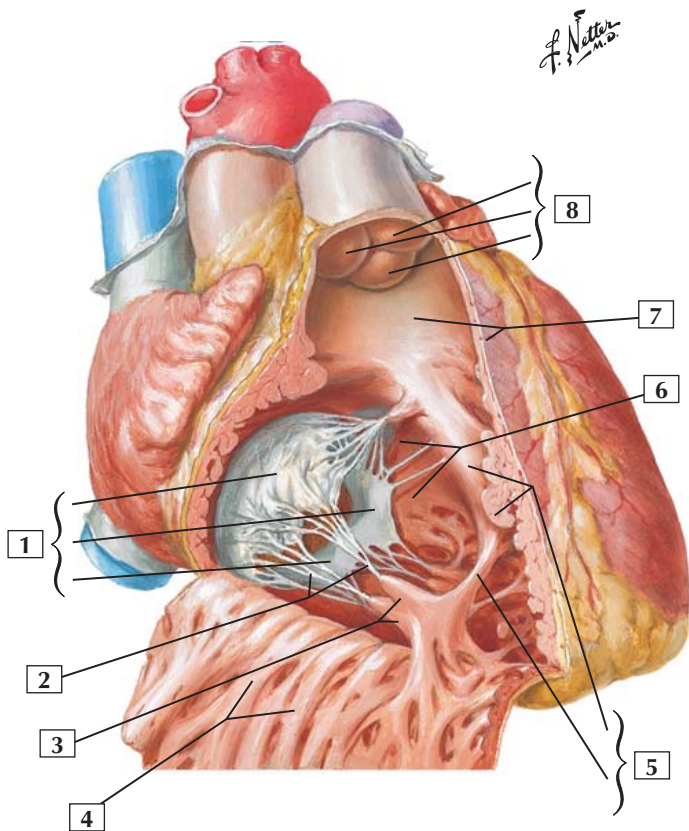
The fossa ovalis is the adult representation of the embryonic foramen ovale.

Although the right atrium is slightly larger than the left atrium, it has thinner walls because the pressure on the right side of the heart is normally lower than that on the left side.

The auricle is a pouch-like appendage of the atrium but is functionally identical to the rest of the atrium.

Clinical: Atrial septal defects make up 10-15% of congenital cardiac anomalies. In such cases, blood flows from the higher-pressure left atrium into the lower-pressure right atrium.

Opened right ventricle: anterior view



1. Tricuspid valve (Anterior, Septal, and Posterior cusps)
2. Chordae tendineae
3. Anterior papillary muscle
4. Trabeculae carneae
5. Septomarginal trabecula (Septal limb and Moderator band)
6. Interventricular septum (muscular part)
7. Conus arteriosus
8. Pulmonary valve (Anterior, Right, and Left semilunar cusps)

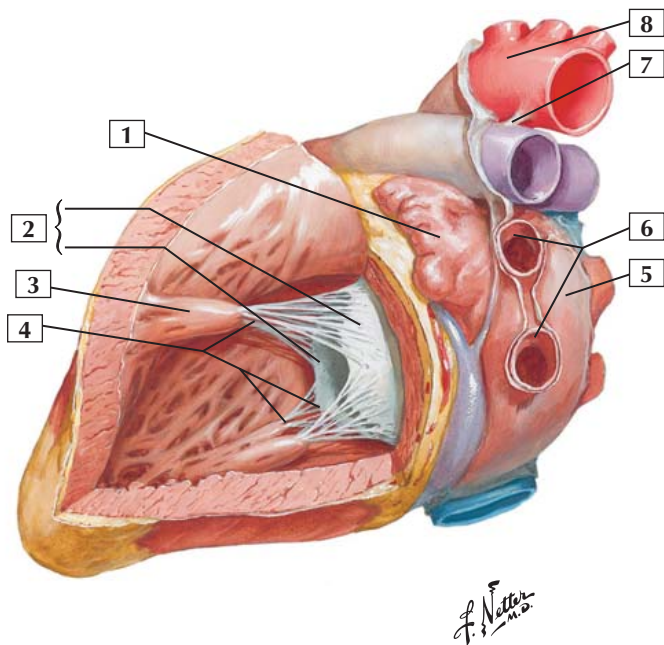
Comment: Chordae tendineae connect papillary muscles to the cusps of the tricuspid, or right atrioventricular, valve. During contraction of the right ventricle, the chordae tendineae prevent the valve cusps from everting into the right atrium.

The septomarginal trabecula (moderator band) of the trabeculae carneae connects the interventricular septum to the base of the anterior papillary muscle. Contraction of this band of muscle prevents overdistention of the ventricle.

The interventricular septum is largely muscular, but its superior aspect contains a small membranous portion that is a common site for ventricular septal defects.

Clinical: Ventricular septal defect is the most common congenital heart defect. The most common site of occurrence is in the perimembranous region of the septum, just beneath the tricuspid and mitral valves. This defect results in a left-to-right shunt of blood and may precipitate congestive heart failure.

Left Atrium and Ventricle: Flap Opened in Posterolateral Wall of Left Ventricle



WWW.YAZDANPRESS.COM

Left Atrium and Ventricle: Flap Opened in Posterolateral Wall of Left Ventricle

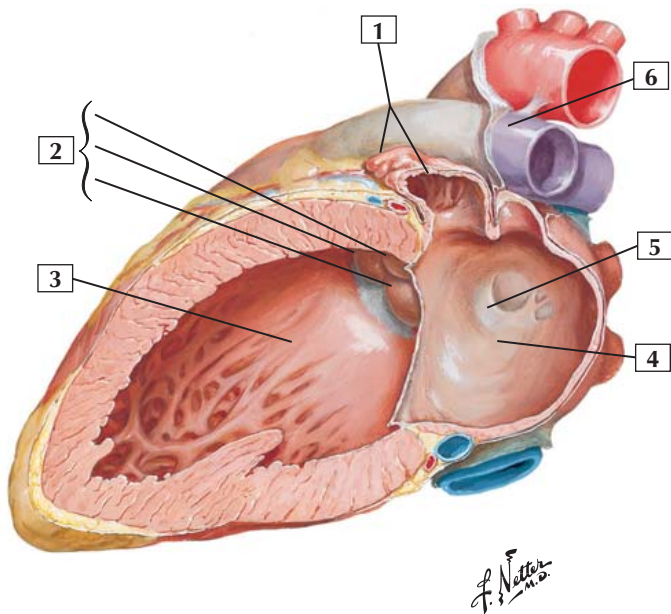
1. Left auricle
2. Mitral valve (Posterior and Anterior cusps)
3. Anterior papillary muscle
4. Chordae tendineae
5. Left atrium
6. Left pulmonary veins
7. Ligamentum arteriosum
8. Arch of aorta

Comment: The left ventricle is significantly thicker than the right ventricle. It contains 2 papillary muscles whose chordae tendineae attach to the cusps of the mitral (left atrioventricular or bicuspid) valve. The mitral valve looks like a bishop's miter.

Heart sounds (lub-dub) occur from the closing of the valves. The first heart sound results from the closing of the mitral and tricuspid valves, whereas the second heart sound results from the closing of the aortic and pulmonic valves.

Clinical: Because of the pressures it must withstand, the mitral valve is most often involved in valvular heart disease. Mitral stenosis (narrowing) can impede the flow of blood from the left atrium to the left ventricle, causing left atrial dilation. Mitral regurgitation (insufficiency) is often caused by abnormalities of the valve leaflets, rupture or fibrosis of a papillary muscle, or rupture of the chordae tendineae.

Left Atrium and Ventricle: Section with Mitral Valve Cut Away



Left Atrium and Ventricle: Section with Mitral Valve Cut Away

1. Left auricle
2. Aortic valve (Left, Right, and Posterior semilunar cusps)
3. Muscular part of interventricular septum
4. Left atrium
5. Valve of foramen ovale
6. Left pulmonary artery

Comment: Usually, the left atrium is smaller than the right atrium, but it has thicker walls. Oxygenated blood from the lungs passes into the left atrium through 4 pulmonary veins.

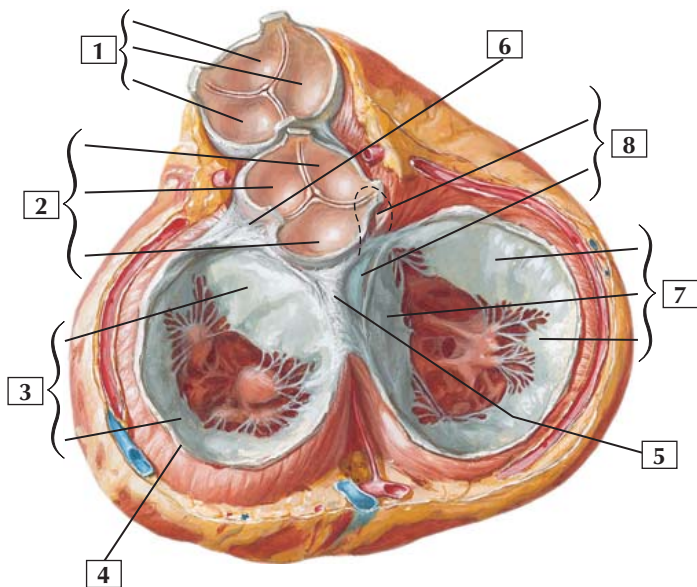
Most of the interventricular septum is muscular, but the uppermost portion is membranous and is a common site for ventricular septal defects.

The upper portion of the left ventricle, known as the aortic vestibule, is the outflow tract to the ascending aorta. The aortic valve has 3 semilunar cusps.

Clinical: Valvular heart disease can arise from a variety of conditions (stenosis, rupture of papillary muscles or chordae tendineae, malformed valve leaflets) and most often involves either the mitral or the aortic valves.

The major blood supply to the interventricular septum is via the left anterior descending branch of the left coronary artery. Ischemia of the interventricular septum may compromise the Purkinje conduction system innervating the septum and ventricular walls.

Heart in diastole:
viewed from base with atria removed



*F. Netter
M.D.*

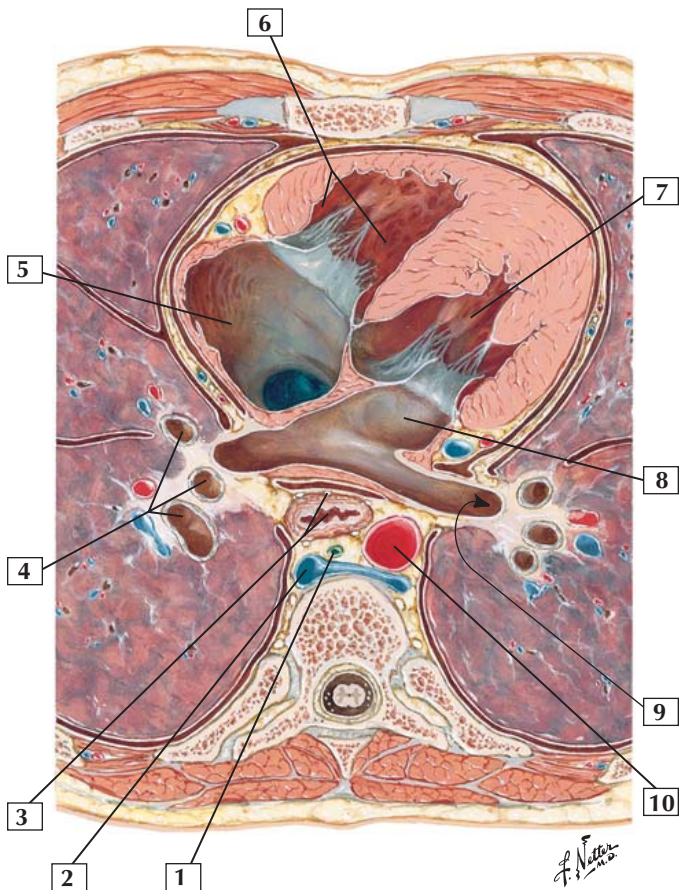
1. Pulmonary valve (Anterior, Right, and Left semilunar cusps)
2. Aortic valve (Right, Left, and Posterior semilunar cusps)
3. Mitral valve (Anterior and Posterior cusps)
4. Left fibrous ring (of mitral valve)
5. Right fibrous trigone
6. Left fibrous trigone
7. Tricuspid valve (Anterior, Septal, and Posterior cusps)
8. Membranous septum (Interventricular and Atrioventricular parts)

Comment: The 1st heart sound (“lub”) is caused by closure of the tricuspid and mitral valves at the onset of ventricular systole. The 2nd heart sound (“dub”) is caused by closure of the aortic and pulmonary valves at the onset of ventricular diastole.

The pulmonary valve is a semilunar valve with 3 cusps. Through the stethoscope, this valve is best heard over the left 2nd intercostal space, just lateral to the sternum. The aortic valve also is a semilunar valve with 3 cusps. Closure of this valve is best heard over the right 2nd intercostal space just lateral to the sternum.

The mitral (bicuspid or left atrioventricular) valve has 2 cusps. Its closure at the onset of ventricular systole is best heard in the left 5th intercostal space, at the midclavicular line. The tricuspid (right atrioventricular) valve has 3 cusps. Its sound is best heard over the lower portion of the body of the sternum.

The wall of the heart is composed principally of cardiac muscle and a fibrous skeleton that provides attachment points for some of the cardiac muscle fibers and each heart valve.



WWW.YAZDANPRESS.COM
**Mediastinum: Cross Section at Level
of T8 Vertebra**

1. Thoracic duct
2. Azygos vein
3. Esophagus and esophageal plexus
4. Branches of right main bronchus
5. Right atrium
6. Right ventricle
7. Left ventricle
8. Left atrium
9. Left inferior pulmonary vein
10. Thoracic (descending) aorta

Comment: The mediastinum is the region between the 2 pleural cavities. A horizontal line between the sternal angle divides it into a superior and inferior mediastinum. The inferior mediastinum is further divided into anterior, middle, and posterior compartments. The anterior mediastinum lies just behind the body of the sternum and contains remnants of the thymus gland, lymph nodes, fat, and some connective tissue. The middle mediastinum contains the pericardium and heart and nerves and the roots of the great vessels. The posterior mediastinum is posterior to the pericardium and heart. It contains the esophagus, thoracic aorta, azygos system of veins, thoracic duct, and nerves.

Bones and Joints

- 4-1** Bony Framework of Abdomen

Muscles

- 4-2** External Abdominal Oblique: Muscular Part (A) and Aponeurotic Part (B)
- 4-3** Internal Oblique
- 4-4** Rectus Abdominis
- 4-5** Cremaster Muscle
- 4-6** Anterior Abdominal Wall: Deep Dissection
- 4-7** Quadratus Lumborum
- 4-8** Diaphragm

Nerves

- 4-9** Autonomic Nerves and Ganglia of Abdomen
- 4-10** Autonomic Reflex Pathways: Schema
- 4-11** Nerves of Kidney, Ureters, and Urinary Bladder

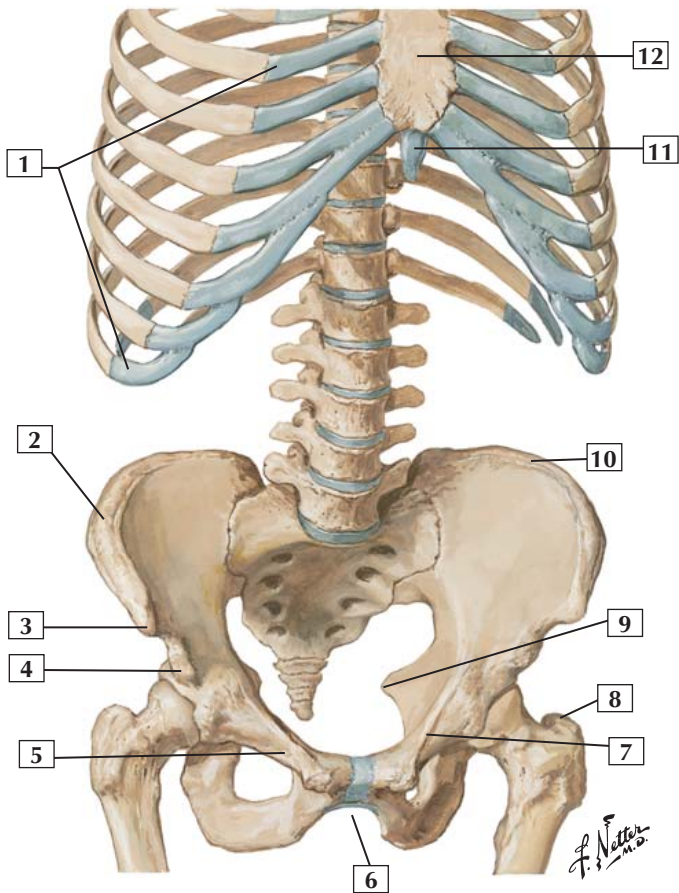
Vessels

- 4-12** Visceral Referred Pain
- 4-13** Veins of Anterior Abdominal Wall
- 4-14** Inguinal Canal and Spermatic Cord
- 4-15** Arteries of Stomach, Liver, and Spleen
- 4-16** Arteries of Large Intestine
- 4-17** Arteries of Posterior Abdominal Wall

- 4-18** Renal Artery and Vein In Situ
- 4-19** Veins of Posterior Abdominal Wall
- 4-20** Hepatic Portal Vein Tributaries: Portacaval Anastomoses

Viscera

- 4-21** Greater Omentum and Abdominal Viscera
- 4-22** Omental Bursa: Stomach Reflected
- 4-23** Omental Bursa: Cross Section
- 4-24** Gallbladder and Extrahepatic Bile Ducts
- 4-25** Surfaces of Liver
- 4-26** Mucosa and Musculature of Small Intestine
- 4-27** Mucosa and Musculature of Large Intestine
- 4-28** Gross Structure of Kidney
- 4-29** Abdominal Wall and Viscera: Median (Sagittal) Section
- 4-30** Schematic Cross Section of Abdomen at T12
- 4-31** Schematic Cross Section of Abdomen at L2 and L3

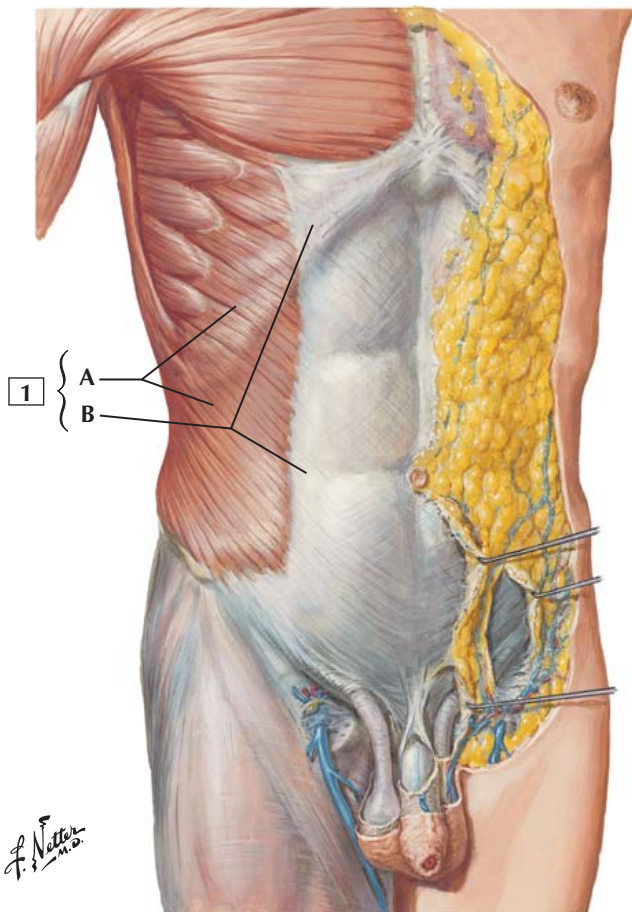


1. Costal cartilages
2. Iliac crest
3. Anterior superior iliac spine
4. Anterior inferior iliac spine
5. Superior pubic ramus
6. Pubic arch
7. Pecten pubis
8. Greater trochanter of femur
9. Ischial spine
10. Iliac crest
11. Xiphoid process
12. Body of sternum

Clinical: Imaginary lines mentally drawn on the surface of the abdominal wall assist clinicians in localizing pain and associated anatomic structures. The subcostal line is an imaginary horizontal line across the lower margin of the costal cartilages; it crosses the descending duodenum. The transumbilical plane is a horizontal line passing through the umbilicus and the L3-4 intervertebral disc. The transtubercular plane passes through the iliac tubercles of the iliac crest and corresponds to the body of the 5th lumbar vertebra.

Another clinically useful way to locate painful viscera is to divide the abdomen into quadrants. This is done by visualizing an imaginary vertical (median) plane from the xiphoid process to the pubic symphysis and a horizontal (transumbilical) plane. The 4 quadrants are the right upper quadrant, left upper quadrant, right lower quadrant, and left lower quadrant.

External Abdominal Oblique: Muscular Part (A) and Aponeurotic Part (B)



WWW.YAZDANPRESS.COM

External Abdominal Oblique: Muscular Part (A) and Aponeurotic Part (B)

1. External abdominal oblique: muscular part (A) and aponeurotic part (B)

Origin: Arises by fleshy digitations from the external surface and inferior borders of the lower 8 ribs.

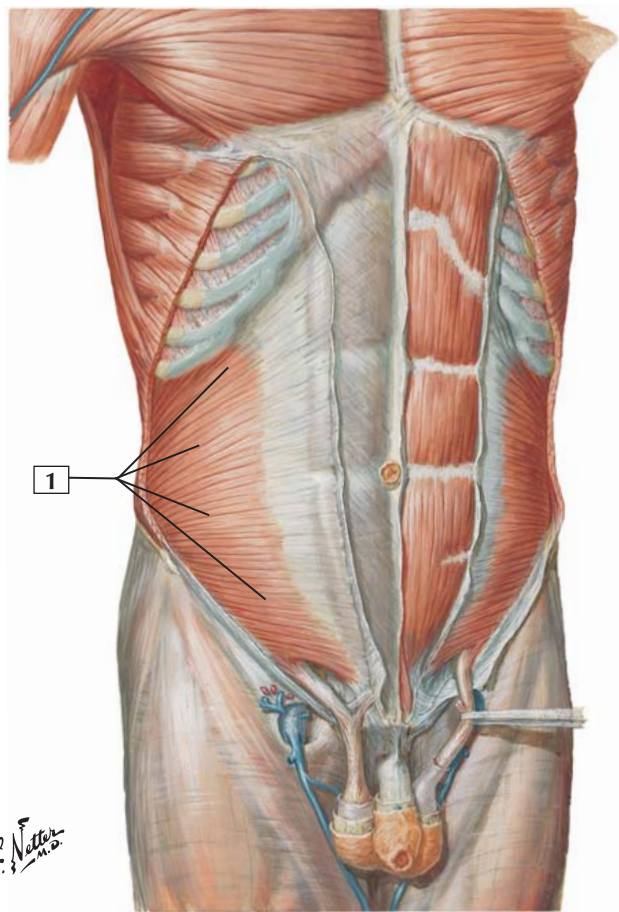
Insertion: The muscle attaches to the anterior half of the iliac crest, to the anterior superior iliac spine, and into a broad aponeurosis along a line from the 9th costal cartilage to the anterior superior iliac spine. The aponeurosis inserts into the midline linea alba.

Action: Compresses the abdominal contents. Contracting bilaterally, the muscles flex the vertebral column or trunk. Acting alone, it bends the vertebral column laterally and rotates it so as to bring the shoulder of the same side forward.

Innervation: Supplied by intercostal nerves T7-11 and the subcostal nerve (T12).

Comment: This is the largest and most superficial of the 3 flat abdominal muscles.

Clinical: On the left side (patient's left) of this dissection, one can see the fatty Camper fascia and the underlying membranous (Scarpa) fascia of the abdominal wall. These fascial planes are important in the spread of infection. Fluid from the perineal region (e.g., ruptured urethra) can spread into the abdominal wall between Scarpa's fascia and the underlying investing (deep) fascia of the external abdominal oblique muscle and aponeurosis.



1. Internal oblique

Origin: Arises from the lateral half of the inguinal ligament, the iliac crest, and the thoracolumbar fascia.

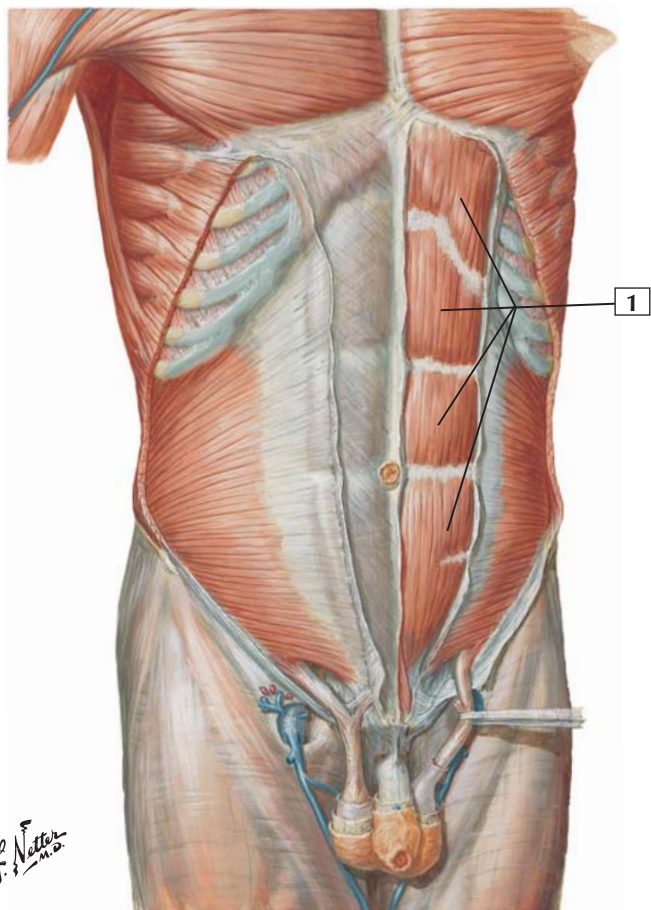
Insertion: Attaches to the inferior borders of the cartilages of the last 3 or 4 ribs, the linea alba, the pubic crest, and the pectineal line.

Action: Compresses the abdominal contents. Contraction of both internal oblique muscles flexes the vertebral column. Contraction on one side only bends the vertebral column laterally and rotates it, moving the shoulder of the opposite side anteriorly.

Innervation: By intercostal nerves T7-11, subcostal nerve (T12), and iliohypogastric and ilioinguinal nerves (L1).

Comment: In the inguinal region, the aponeuroses of the internal oblique and transverse abdominal muscles fuse to form the conjoint tendon.

Clinical: A weakness in the anterior abdominal wall can lead to hernias, where underlying viscera and fat may protrude anteriorly and cause a bulge or rupture of the anterior muscle layers. The most common types of abdominal wall hernias are inguinal hernias, umbilical hernias, linea alba hernias (usually occur in the epigastric region), and incisional hernias (occur at the site of a previous surgical scar).



1. Rectus abdominis

Origin: Arises inferiorly by 2 tendons. The lateral tendon is attached to the pubic crest, and the medial tendon interlaces with the tendon of the opposite side to arise from the pubic symphysis.

Insertion: Attaches into the cartilages of the 5th, 6th, and 7th ribs and the xiphoid process.

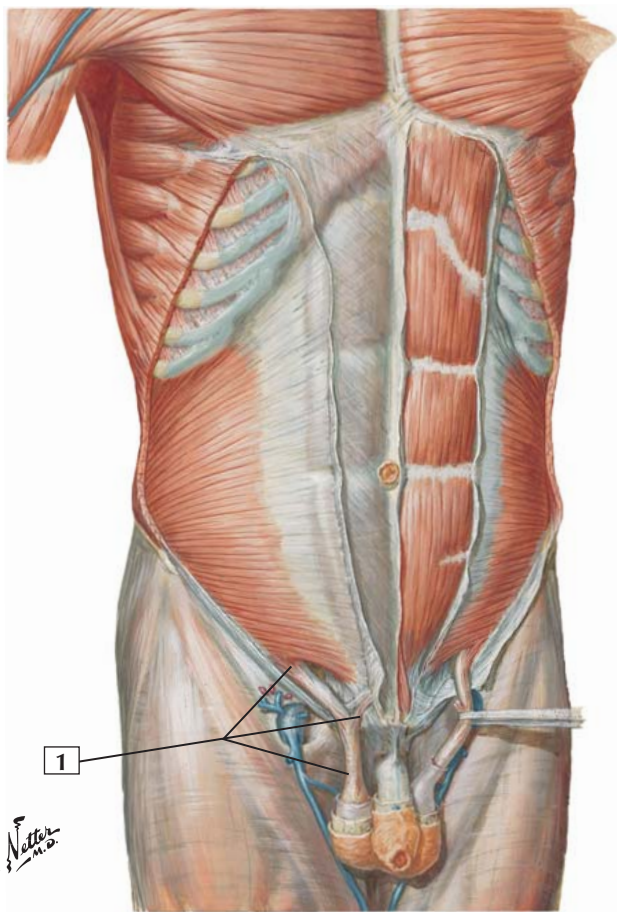
Action: Flexes the vertebral column or trunk, tenses the anterior abdominal wall, and depresses the ribs.

Innervation: Intercostal nerves (T7-11) and the subcostal nerve (T12).

Comment: The rectus abdominis muscle is contained in the rectus sheath and is separated from the rectus abdominis on the other side by the linea alba.

The muscle is crossed by fibrous bands, which are the 3 tendinous intersections.

Clinical: If abdominal pain is present, especially if the affected visceral structure (e.g., bowel, appendix) comes in contact with the inner aspect of the peritoneal wall, the patient may present with a guarding reflex. The patient will contract the abdominal wall muscles when palpated (rebound tenderness) because of the abdominal pain and the abdomen will become rigid.



1. Cremaster muscle

Origin: This thin muscle arises from the middle of the inguinal ligament and is a continuation of the internal abdominal oblique muscle.

Insertion: Attaches by a small tendon to the pubic tubercle and crest.

Action: Draws the testes upward.

Innervation: Genital branch of the genitofemoral nerve (L1 and L2).

Comment: After passing through the inguinal ring, the muscle fibers of the cremaster form a series of loops that are embedded in the cremasteric fascia (surrounding the spermatic cord in a male).

The spermatic cord is covered by 3 fascial layers derived from the abdominal wall. The external spermatic fascia is derived from the external abdominal oblique aponeurosis; the middle spermatic (cremasteric) fascia, from the internal abdominal oblique muscle; and the internal spermatic fascia, from the transversalis fascia.

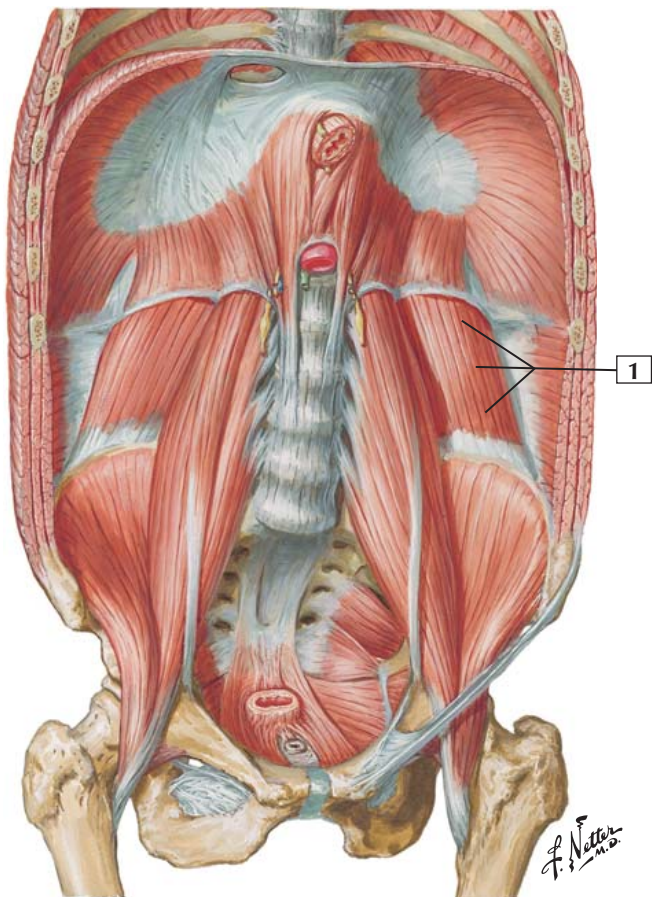
Clinical: The testes descend into the scrotum shortly before birth. This is necessary for viable germ cell division and future sperm production. The human testes will not produce sperm if the testis is not cooled to several degrees below that of the body's normal temperature (37°C [98.6°F]).

Anterior Abdominal Wall: Deep Dissection

1. Superior epigastric vessels
2. Rectus abdominis muscle
3. Transversus abdominis muscle
4. Posterior layer of rectus sheath
5. Inferior epigastric vessels
6. Inguinal ligament (Poupart's)
7. Inguinal falx (conjunct tendon)
8. Cremasteric muscle (middle spermatic fascia)
9. Lacunar ligament (Gimbernat's)
10. Medial umbilical ligament (occluded part of umbilical artery)
11. Arcuate line
12. Transversalis fascia
13. Anterior layer of rectus sheath
14. Linea alba

Comment: Above the arcuate line, the anterior layer of the rectus sheath comprises the fused aponeuroses of the external and internal abdominal oblique muscles, whereas the posterior layer comprises the fused aponeuroses of the internal abdominal oblique and the transversus abdominis muscles. Below the arcuate line, the aponeuroses of all 3 muscles fuse to form the anterior layer of the sheath; and the rectus abdominis muscle rests only on the thin transversalis fascia.

Clinical: The inferior epigastric vessels form the lateral umbilical fold and anastomose with the superior epigastric vessels, which are continuous with the internal thoracic (mammary) vessels. This arterial vascular anastomosis is important in providing blood to the abdominal wall, because these arteries have connections all along their route with intercostal arteries (in the thorax) and segmental lumbar branches in the abdomen.



1. Quadratus lumborum

Origin: Arises from the transverse processes of L3-5, the iliolumbar ligament, and the iliac crest.

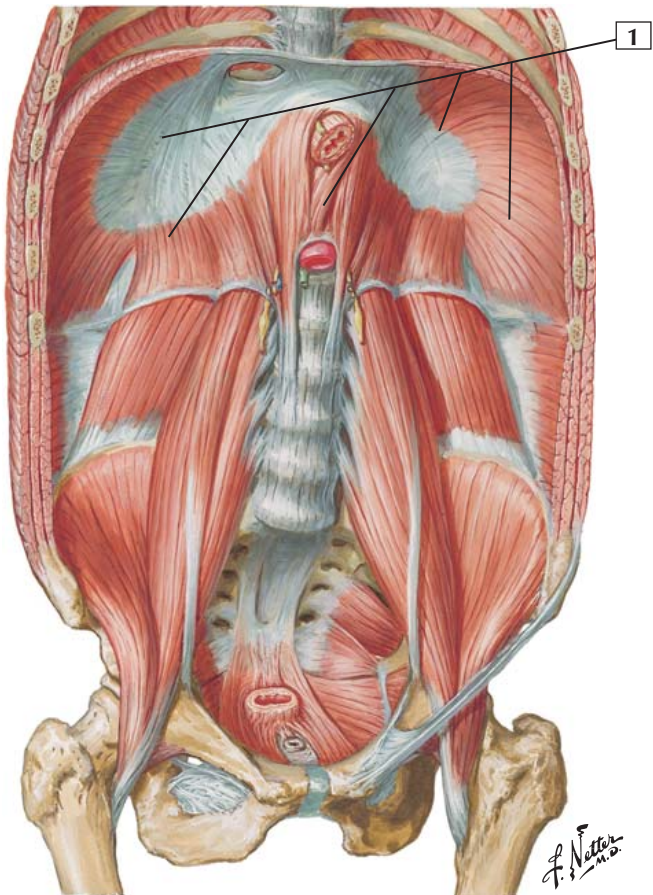
Insertion: Attaches to the lower border of the last rib and the transverse processes of L1-3 vertebrae.

Action: With the pelvis fixed, this muscle laterally flexes the lumbar vertebral column (trunk). It also fixes the 12th rib during inspiration. When both quadratus lumborum muscles act together, they can help extend the lumbar vertebral column.

Innervation: Subcostal nerve (T12 and L1-4 nerves).

Comment: Superiorly, the diaphragm forms the lateral arcuate ligament (lumbocostal arch) where it passes over the quadratus lumborum.

Clinical: The lumbocostal triangle (located just lateral and superior to the lateral arcuate ligament) is a nonmuscular area between the costal and lumbar portions of the diaphragm. During trauma or with increased abdominal pressure, this portion of the diaphragm can become weakened and viscera can herniate into the thorax superiorly.





1. Diaphragm

Origin: This dome-shaped musculofibrous septum arises from the circumference of the thoracic outlet, with fibers arising from a sternal portion (xiphoid process), a costal portion (lower 6 costal cartilages), and a lumbar portion (L1-3 vertebrae).

Insertion: The muscles converge and insert into the central tendon.

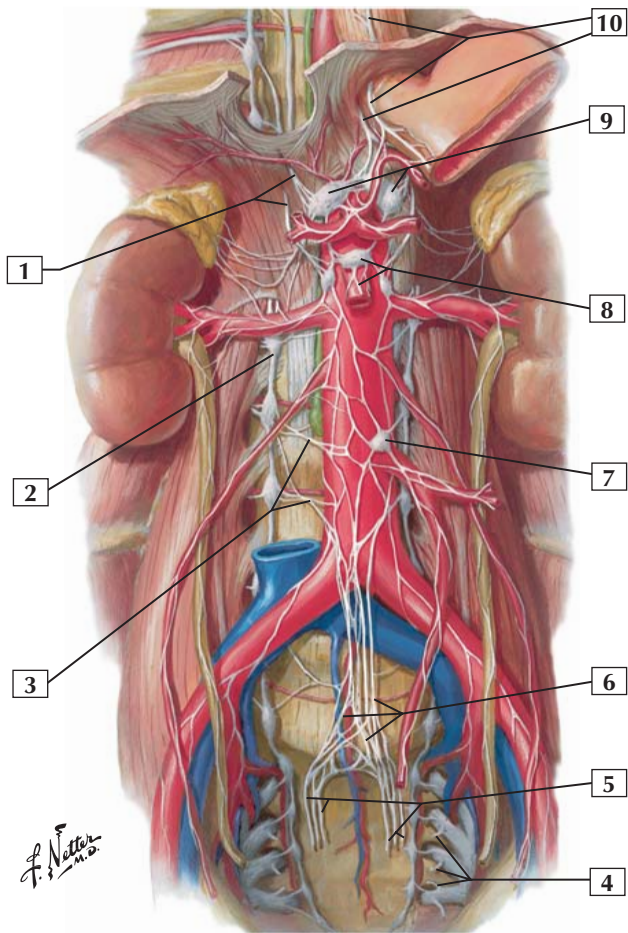
Action: Attached to the ribs and lumbar vertebrae, the muscular diaphragm draws the central tendon downward and forward during inspiration. This increases the volume of the thoracic cavity and decreases the volume of the abdominal cavity.

Innervation: Phrenic nerve (C3, C4, and C5).

Comment: The diaphragm has 3 large openings: the caval hiatus for the inferior vena cava (at the level of the T8 vertebra), the esophageal hiatus (at the level of the T10 vertebra), and the aortic hiatus (in front of the T12 vertebra).

Where the diaphragm passes over the aorta, it forms an arch called the median arcuate ligament. As the diaphragm passes over the psoas major muscle, it forms the medial arcuate ligament; and where it passes over the quadratus lumborum, it forms the lateral arcuate ligament.

Clinical: If inflamed viscera (e.g., gallbladder) contacts the underside of the diaphragm, the parietal peritoneum may become inflamed and the pain will be passed along the sensory axons of the phrenic nerve (C3-5) on the right side to the corresponding dermatomes in the lower neck and shoulder region. This is an example of referred pain from the abdomen to a somatic region of the body.



WWW.YAZDANPRESS.COM

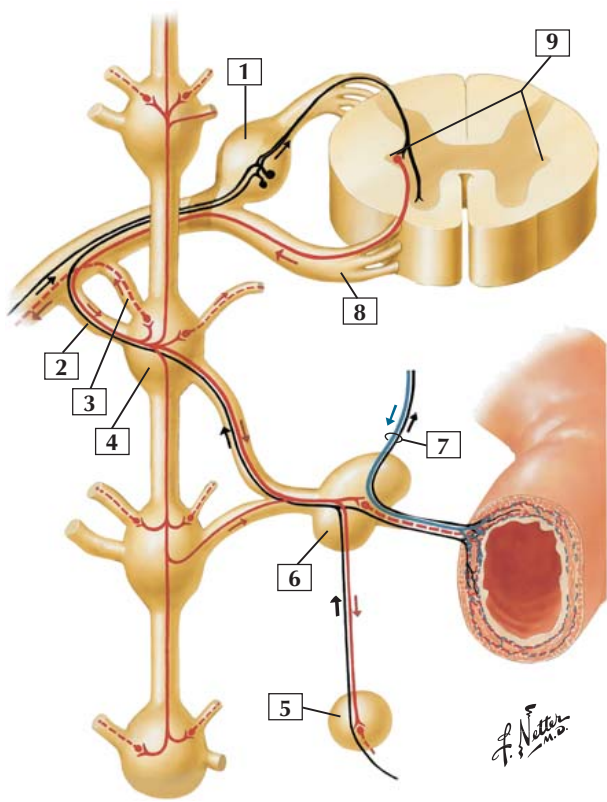
Autonomic Nerves and Ganglia of Abdomen

1. Right greater and lesser splanchnic nerves
2. Right sympathetic trunk
3. 2nd and 3rd lumbar splanchnic nerves
4. Pelvic splanchnic nerves
5. Right and left hypogastric nerves to inferior hypogastric (pelvic) plexus
6. Superior hypogastric plexus
7. Inferior mesenteric ganglion
8. Superior mesenteric ganglion and plexus
9. Celiac ganglia
10. Vagal trunks: Anterior and Posterior

Comment: Sympathetic and parasympathetic nerves innervate the viscera of the abdominal cavity. Sympathetic nerves coursing in the thoracic splanchnic nerves (from T5-12 spinal cord levels) and lumbar splanchnics (upper lumbar levels) synapse largely in 3 major collections of ganglia: celiac, superior mesenteric, and inferior mesenteric ganglia. A nerve plexus continuing from this most inferior ganglion gives rise to the superior hypogastric plexus, which provides sympathetic innervation to pelvic viscera.

Parasympathetic innervation to the upper two thirds of the abdominal viscera (derived from the foregut and midgut portions of the embryonic gut) comes from the vagus nerve. The remaining portions of the abdominal and pelvic viscera (embryonic hindgut) receive parasympathetics from S2, S3, and S4 via pelvic splanchnic nerves.

Most of these autonomic fibers reach the viscera by traveling on the blood vessels originating from the celiac trunk and the superior and inferior mesenteric arteries.



Sympathetic fibers	{	Preganglionic	— (solid red)	Parasympathetic fibers	{	Preganglionic	— (solid blue)	Afferent fibers	— (solid black)
		Postganglionic	- - - (dashed red)			Postganglionic	- - - (dashed blue)		

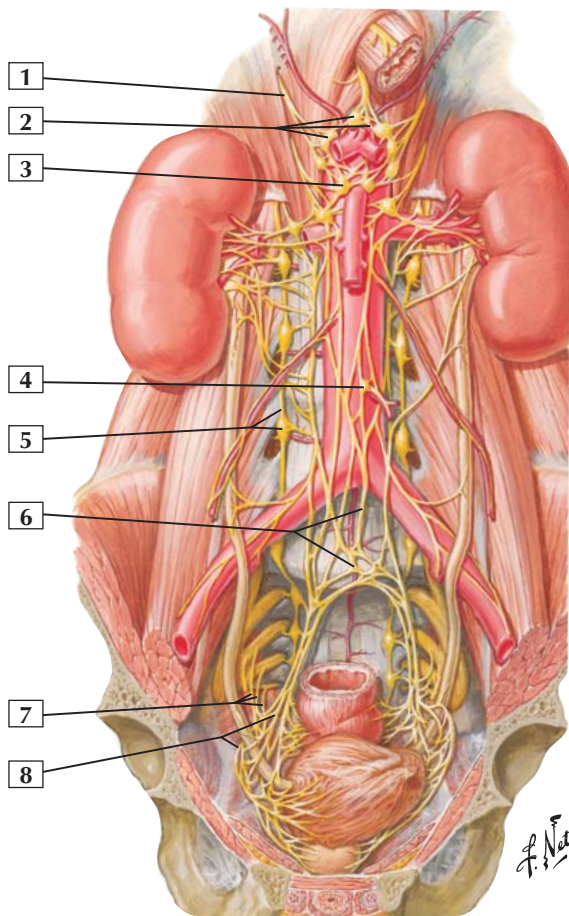
1. Spinal sensory (dorsal root) ganglion
2. White ramus communicans
3. Gray ramus communicans
4. Ganglion of sympathetic trunk
5. Superior mesenteric ganglion
6. Celiac ganglion
7. Vagus nerve (CN X)
8. Anterior (ventral) root
9. Intermediolateral cell column

Comment: This schema shows the general pattern for sympathetic and parasympathetic innervation of abdominal viscera.

Preganglionic sympathetic fibers can synapse in ganglia of the sympathetic trunk, course via splanchnic nerves to synapse in collateral ganglia such as the celiac or superior mesenteric ganglion (this example), or pass directly to the adrenal medulla (not shown).

Parasympathetic fibers to the upper two thirds of the abdominal viscera are conveyed by the vagus nerve, which sends preganglionic fibers directly to the walls of the organs innervated. These fibers end in terminal ganglia in the visceral wall, which give rise to short postganglionic fibers.

Clinical: Pain sensation from the bowel (largely from distention or inflammation) is conveyed by afferent fibers whose nerve cell bodies reside in the dorsal root ganglia of the T5-L2 spinal levels. Therefore, visceral pain is often referred to somatic regions of the body corresponding to the dermatomes supplied by the spinal cord segment that receives the visceral afferent (sensory) input. This is called referred pain.



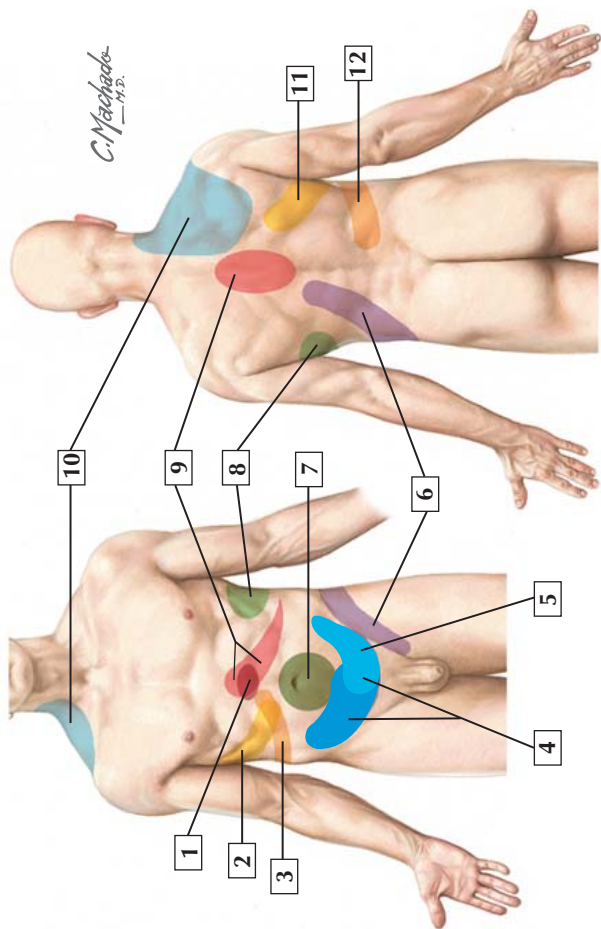
Nerves of Kidney, Ureters, and Urinary Bladder

1. Greater splanchnic nerve
2. Celiac ganglia and plexus
3. Superior mesenteric ganglion
4. Inferior mesenteric ganglion
5. Sympathetic trunk and ganglion
6. Superior hypogastric plexus
7. Pelvic splanchnic nerves
8. Inferior hypogastric (pelvic) plexus with periureteric loops and branches to lower ureter

Comment: A rich plexus of sympathetic nerves arising from the superior mesenteric ganglion courses to the kidneys. Sympathetics to pelvic viscera arise from the superior hypogastric plexus formed below the inferior mesenteric ganglion. These nerves course on either side of pelvic viscera to the inferior hypogastric plexus.

Parasympathetic fibers to the kidneys arise from the vagus nerve. Pelvic viscera and lower abdominal viscera receive their parasympathetic fibers from pelvic splanchnic nerves arising from S2, S3, and S4 spinal cord levels.

Clinical: The pain (renal colic) of a renal stone that passes from the kidney and into the ureter is usually felt from the loin to the groin as the stone works its way toward the urinary bladder in the pelvis. The pain is conveyed by visceral afferents to the corresponding dorsal root ganglia of the spinal cord (T11-L2); thus, the pain is localized to these dermatomes.

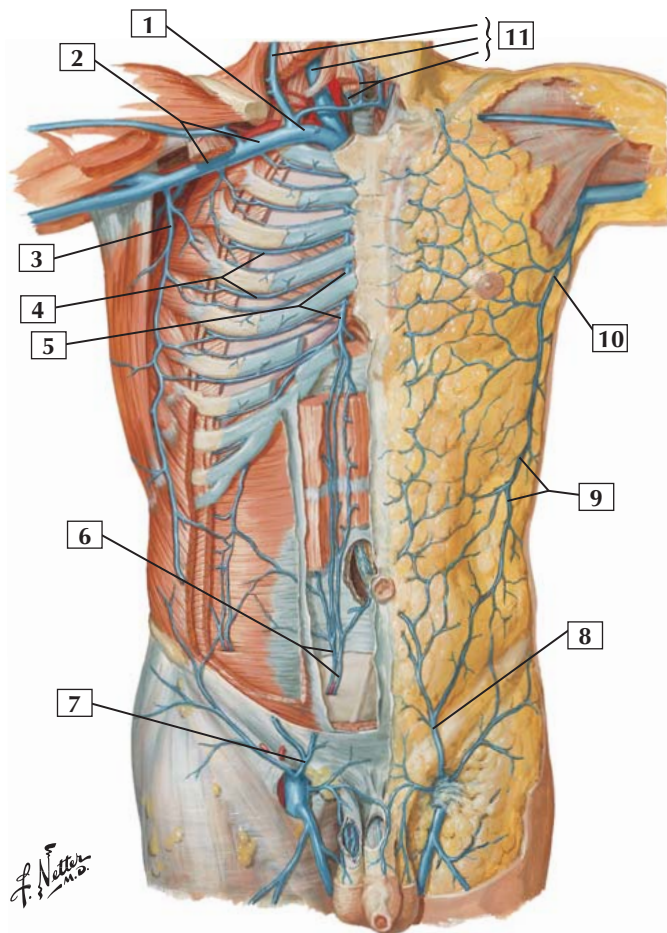


1. Duodenum and head of the pancreas
2. Gallbladder
3. Liver
4. Cecum and colon
5. Sigmoid colon
6. Kidney
7. Small intestine
8. Spleen
9. Stomach
10. Liver, gallbladder, and duodenum (irritation of diaphragm)
11. Gallbladder
12. Liver

Comment: Pain afferents from the abdominal viscera pass to the spinal cord largely by following the thoracic and lumbar splanchnic sympathetic nerves (T5-L2). Visceral pain may be perceived as somatic pain (skin and skeletal muscle) over these respective dermatomes and is called referred pain.

The nerve cell bodies of the afferent fibers from the viscera are located in the dorsal root ganglia of the respective spinal cord levels.

Clinical: Most visceral pain is related to distention or irritation from inflammation or both. Knowing where visceral pain is referred to on the body's surface is important in clinical diagnosis. Some visceral pain (e.g., from the stomach, gallbladder, spleen) is referred to both the anterior and posterior body walls, as shown in the image.

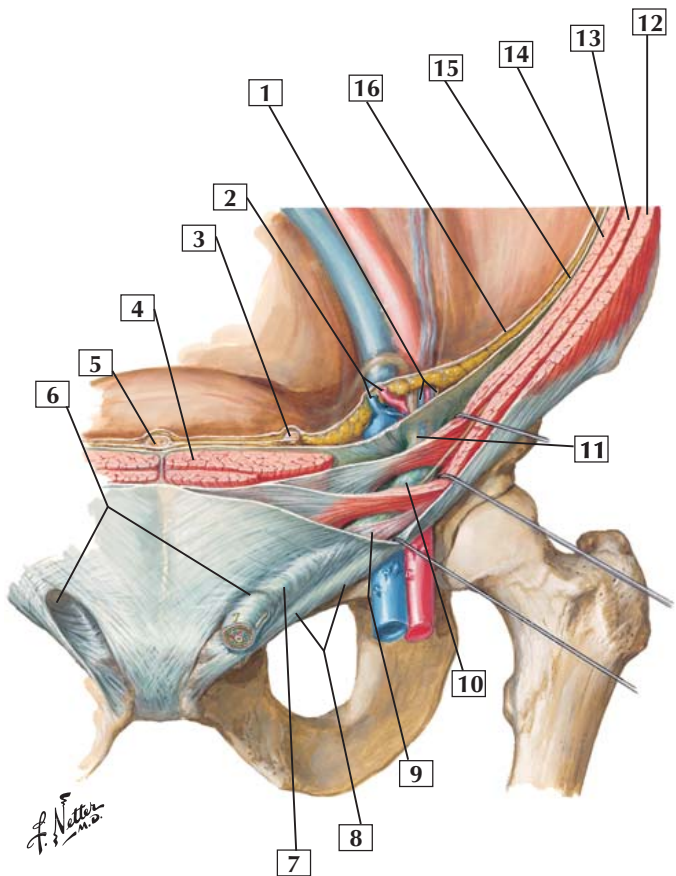


1. Subclavian vein
2. Axillary vein
3. Lateral thoracic vein
4. Anterior intercostal veins
5. Internal thoracic vein
6. Inferior epigastric veins
7. Superficial epigastric vein
8. Superficial epigastric vein
9. Thoracoepigastric vein
10. Lateral thoracic vein
11. Jugular veins (External; Internal; Anterior)

Comment: The veins of the anterior abdominal wall provide an important superficial anastomotic network of veins that returns blood to the heart. These veins include anastomoses between the superficial epigastric veins, which drain the inguinal region, and the lateral thoracic veins, which drain into the axillary vein. On a deeper plane, the inferior epigastric veins anastomose with superficial epigastric veins and the internal thoracic (mammary) veins.

In this illustration, a superficial dissection of the veins is shown in the fatty subcutaneous tissue on one side and on a deeper plane of dissection within the abdominal wall musculature on the other side.

Clinical: Just as in the limbs and head and neck regions, the thorax and abdominopelvic regions have both a superficial and deep venous arrangement with numerous interconnections between these veins. The connections (anastomoses) ensure that venous blood can return to the heart via several different routes if need be (which is important if a venous route is obstructed).

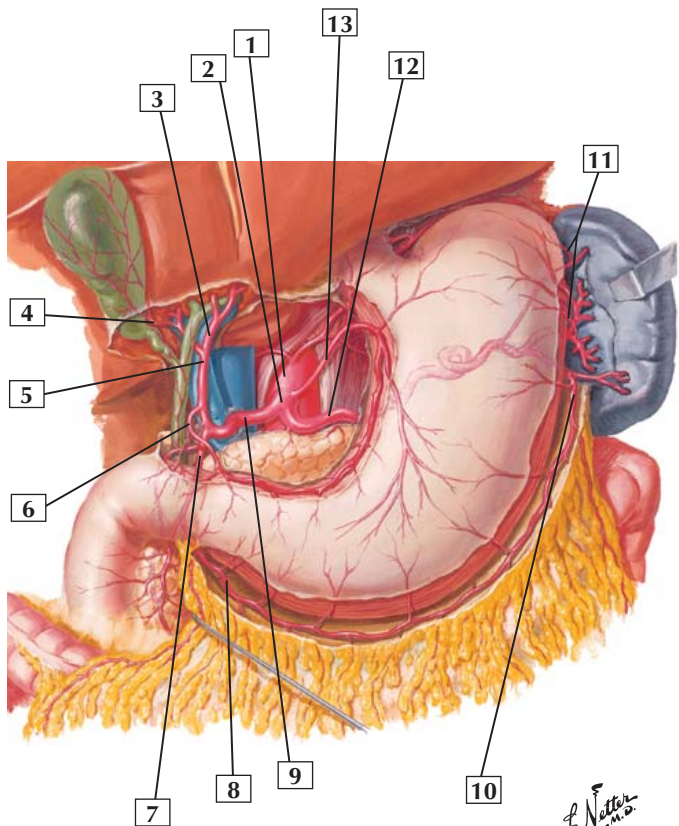


1. Testicular vessels and genital branch of the genitofemoral nerve
2. Inferior epigastric vessels
3. Medial umbilical ligament (occluded part of umbilical artery)
4. Rectus abdominis muscle
5. Median umbilical ligament (urachus)
6. Superficial inguinal rings
7. Intercrural fibers
8. Inguinal ligament (Poupart's)
9. Cremasteric muscle
10. Spermatic cord
11. Internal spermatic fascia (from transversalis fascia at deep inguinal ring)
12. External abdominal oblique muscle
13. Internal abdominal oblique muscle
14. Transversus abdominis muscle
15. Transversalis fascia
16. Peritoneum

Comment: The inguinal canal extends from the deep inguinal ring to the superficial inguinal ring. In males, the spermatic cord traverses this canal.

Clinical: Indirect inguinal hernias (75% of inguinal hernias) occur lateral to the inferior epigastric vessels, pass through the deep inguinal ring and inguinal canal, and are enclosed within the internal spermatic fascia of the spermatic cord.

Direct inguinal hernias occur medial to the inferior epigastric vessels (Hesselbach's triangle), pass through the posterior wall of the inguinal canal, and are separate from the spermatic cord.

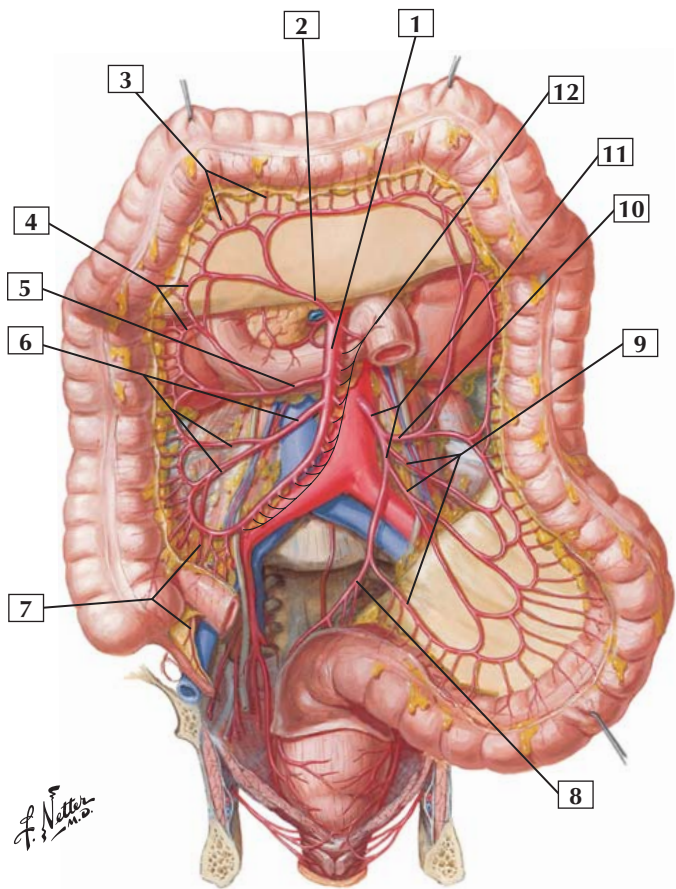


F. Netter
M.D.

1. Abdominal aorta
2. Celiac trunk
3. Left hepatic artery
4. Cystic artery
5. Proper hepatic artery
6. Right gastric artery
7. Gastroduodenal artery
8. Right gastro-omental (gastroepiploic) artery
9. Common hepatic artery
10. Left gastro-omental (gastroepiploic) artery
11. Short gastric arteries
12. Splenic artery
13. Left gastric artery

Comment: Branches of the celiac trunk supply adult derivatives of the embryonic foregut and the spleen, a mesodermal derivative. The celiac trunk gives rise to the left gastric artery, the common hepatic artery, and the splenic artery. These primary branches distribute arterial blood to the liver, gallbladder, portions of the pancreas, spleen, stomach, and proximal duodenum.

Clinical: This epigastric region of the abdominal cavity is clinically important because pain secondary to pathophysiologic processes is common in this area. Vital structures, such as the stomach, duodenum, spleen, pancreas, liver, and gallbladder, all reside in this general region or refer pain to this region and to dermatomes related to the T5-9 or T10 spinal levels. Because so many structures and vessels are in this epigastric region, physicians must obtain a thorough history and perform a physical examination to localize the site(s) of epigastric pain.



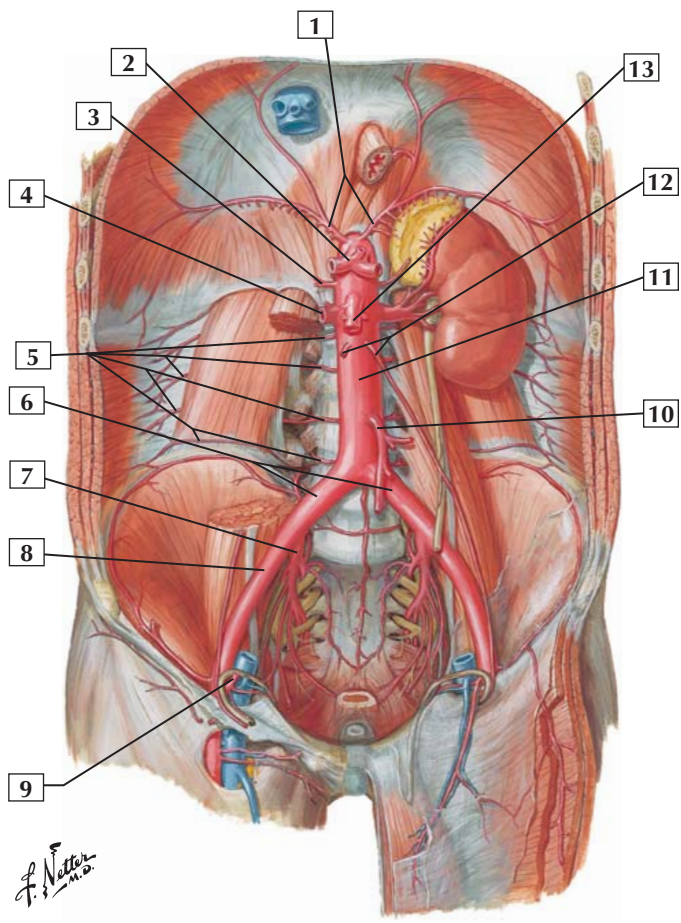
F. Netter M.D.

1. Superior mesenteric artery
2. Middle colic artery
3. Straight arteries (arteriae rectae)
4. Marginal artery
5. Right colic artery
6. Ileocolic artery (Colic branch; Ileal branch)
7. Appendicular artery
8. Superior rectal artery
9. Sigmoid arteries
10. Left colic artery
11. Inferior mesenteric artery
12. Jejunal and ileal (intestinal) arteries

Comment: The superior mesenteric artery supplies blood to the adult gastrointestinal tract derivatives of the embryonic midgut. These include arteries to a portion of the pancreas, the distal duodenum, all of the small intestine, the appendix, the ascending colon, and most of the transverse colon.

The inferior mesenteric artery supplies the embryonic hindgut derivatives: the distal transverse colon, descending and sigmoid colon, and superior portion of the rectum.

Clinical: Anastomotic channels exist between the branches of the superior and inferior mesenteric arteries. If the blood flow from one bowel region is compromised, collateral flow from anastomotic branches usually can assist in supplying blood to the compromised region.

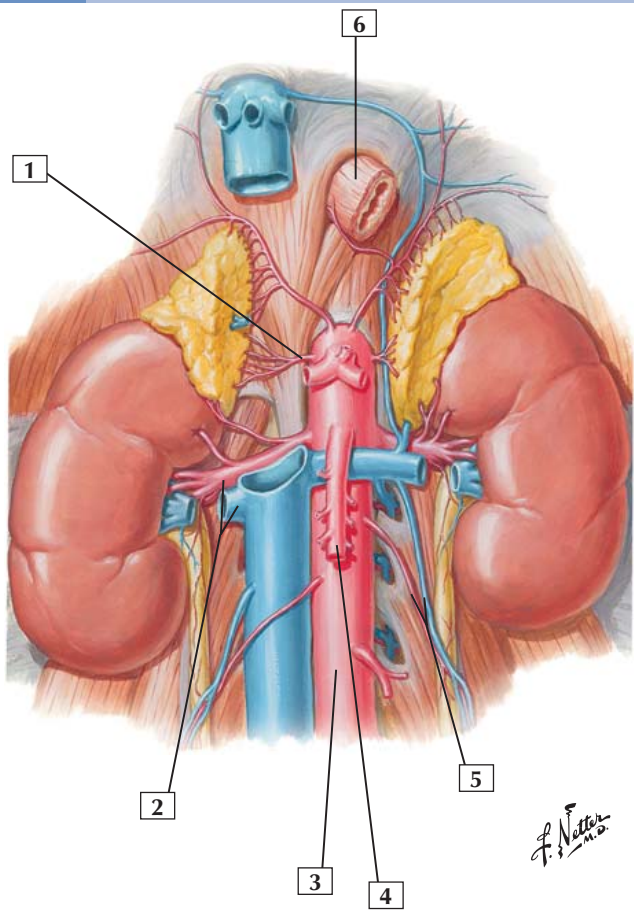


1. Inferior phrenic arteries
2. Celiac trunk with common hepatic, left gastric, and splenic arteries
3. Middle suprarenal artery
4. Right renal artery
5. 1st to 4th right lumbar arteries
6. Common iliac arteries
7. Internal iliac artery
8. External iliac artery
9. Inferior epigastric artery
10. Inferior mesenteric artery
11. Abdominal aorta
12. Testicular (ovarian) arteries
13. Superior mesenteric artery

Comment: The abdominal aorta enters the abdomen via the aortic hiatus (T12 vertebral level) in the diaphragm and divides into the common iliac arteries anterior to the L4 vertebra.

The abdominal aorta supplies blood to the abdominopelvic viscera and posterior abdominal wall. The 3 unpaired vessels supplying the gastrointestinal tract are the celiac, superior, and inferior mesenteric arteries. Paired branches to glandular structures include the middle suprarenal, renal, and gonadal arteries. Parietal branches to the posterior abdominal wall include the inferior phrenic arteries, 4 pairs of lumbar arteries, and a small median sacral artery.

Clinical: Aneurysms (an arterial wall bulge) of large arteries may occur for a variety of reasons. The abdominal aorta inferior to the origin of the renal arteries and above the aortic bifurcation is a common site for aortic aneurysms. The iliac arteries also are often involved. Surgical repair is usually warranted, especially if there is a danger of rupture.



1. Right middle suprarenal artery
2. Right renal artery and vein
3. Abdominal aorta
4. Superior mesenteric artery (*cut*)
5. Left testicular (ovarian) artery and vein
6. Esophagus

Comment: The abdominal aorta gives rise to 3 paired arteries that supply glandular structures of the abdominopelvic cavity. The paired arteries are the middle suprarenal arteries, the left and right renal arteries, and the left and right gonadal (ovarian or testicular) arteries.

As endocrine glands, the suprarenal glands receive a rich arterial supply from inferior phrenic arteries, directly from middle suprarenal arteries arising from the aorta, and from inferior suprarenal arteries arising from the renal vessels.

The suprarenal (adrenal) glands and the kidneys are retroperitoneal organs. The right kidney lies slightly lower than the left kidney, owing to the presence of the liver on the right side. The right adrenal gland usually is pyramidal, and the left adrenal gland is usually semilunar.

Clinical: Because of the segmental development of the kidney and its lobulated appearance, it is not uncommon for there to be several renal arteries and/or veins associated with the kidneys. Therefore, surgeons operating in this region of the abdomen must be aware of the variability in the renal vessels.

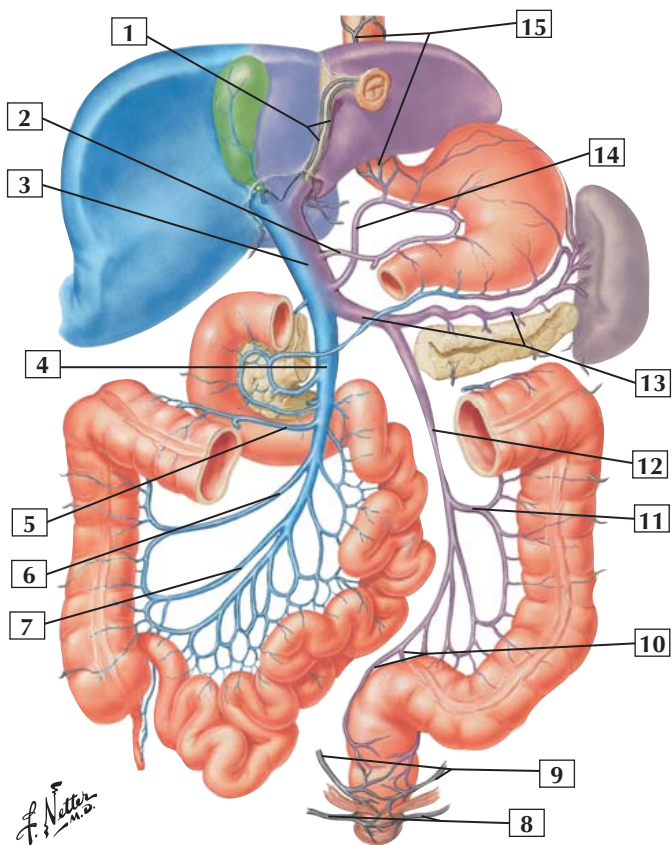
1. Inferior phrenic veins
2. Inferior vena cava
3. Right renal vein
4. 1st to 4th right lumbar veins
5. Common iliac vein
6. External iliac vein
7. Internal iliac vein
8. Common iliac vein
9. Ascending lumbar veins
10. Ovarian (testicular) veins

Comment: The inferior vena cava pierces the diaphragm at the level of the T8 vertebra and enters the right atrium of the heart. Just inferior to the diaphragm, 2 or 3 hepatic veins drain blood from the liver into the inferior vena cava.

Principal tributaries of the inferior vena cava correspond to many of the arterial branches arising from the abdominal aorta. Commonly, these tributaries include the common iliac veins, pairs of lumbar veins, gonadal (testicular or ovarian) veins, renal veins, azygos vein, suprarenal veins, inferior phrenic veins, and hepatic veins. Veins draining the gastrointestinal tract and spleen form the portal venous system.

Clinical: Veins vary in number and arrangement and possess numerous connections with veins lying superficial or deep, as well as with veins of specialized systems such as the portal system draining the gastrointestinal tract. These veins do not have valves, and blood flow may occur in either direction depending on the pressure gradient propelling the blood.

Hepatic Portal Vein Tributaries:
Portacaval Anastomoses



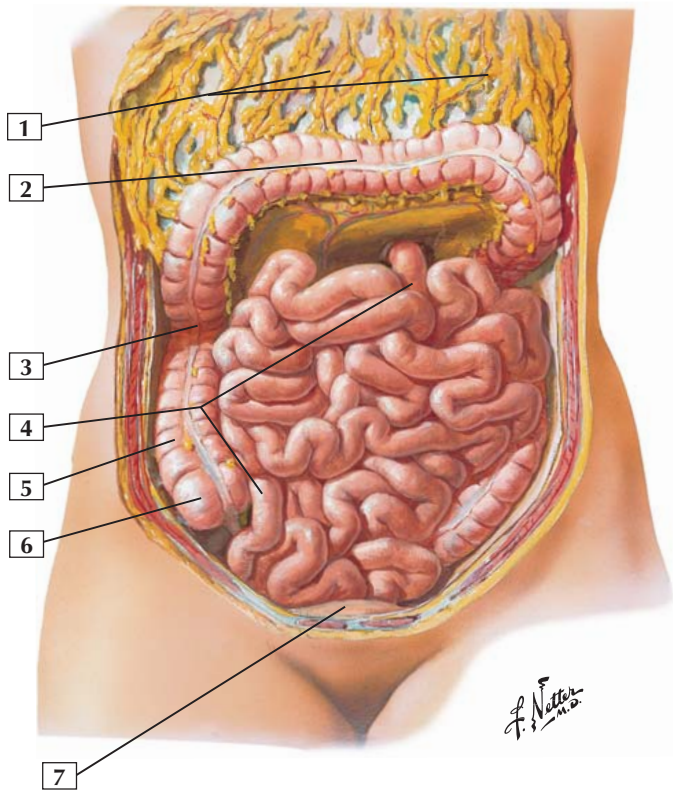
Hepatic Portal Vein Tributaries: Portacaval Anastomoses

1. Paraumbilical veins
2. Right gastric vein
3. Hepatic portal vein
4. Superior mesenteric vein
5. Middle colic vein
6. Right colic vein
7. Ileocolic vein
8. Inferior rectal veins
9. Middle rectal veins
10. Left and right superior rectal veins
11. Left colic vein
12. Inferior mesenteric vein
13. Splenic vein
14. Left gastric vein
15. Esophageal veins

Comment: The hepatic portal vein is formed by the union of the splenic vein and superior mesenteric vein.

Clinical: Important portacaval anastomotic sites include sites around the esophagus, the paraumbilical region, the rectum, and where portions of the gastrointestinal tract are in a retroperitoneal position.

If portal blood flow is decreased or prevented from flowing through the liver, the venous blood still can reach the heart via these important portacaval anastomoses. Likewise, if the inferior vena cava is partially compressed or obstructed, venous blood can flow via the portacaval anastomoses into the portal system of veins.



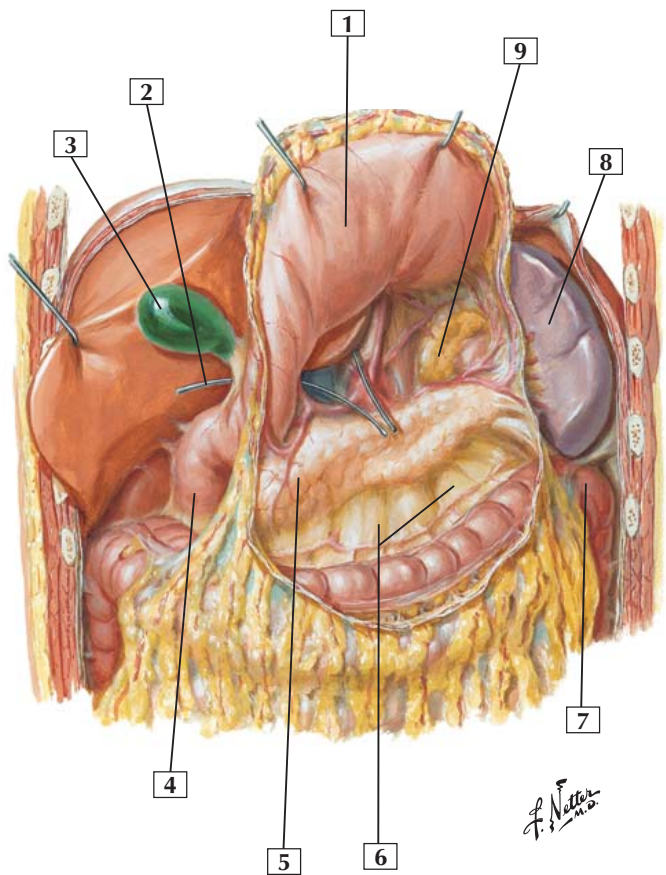
1. Greater omentum (*turned up*)
2. Transverse colon (*turned up*)
3. Right colic (hepatic) flexure
4. Small intestine (jejunum and ileum)
5. Ascending colon
6. Cecum
7. Urinary bladder

Comment: The abdominopelvic cavity is a potential space. Parietal peritoneum lines the inner aspect of the abdominal walls and reflects onto the viscera as visceral peritoneum.

Portions of the ascending, transverse, and descending colon can be seen framing the small bowel, which consists of the jejunum and ileum in this illustration. The fatty greater omentum is turned up but remains attached to the bowel margin.

Clinical: If a portion of the peritoneal cavity or its contents becomes inflamed, the greater omentum can migrate to the site of inflammation and wall off the site by forming an adhesion, potentially protecting the remainder of the cavity. Because of its ability to wall off an infection site, the greater omentum is sometimes referred to as the abdomen's "policeman."

Also, the greater omentum often is a site for the metastatic spread of cancer from multiple primary sites.



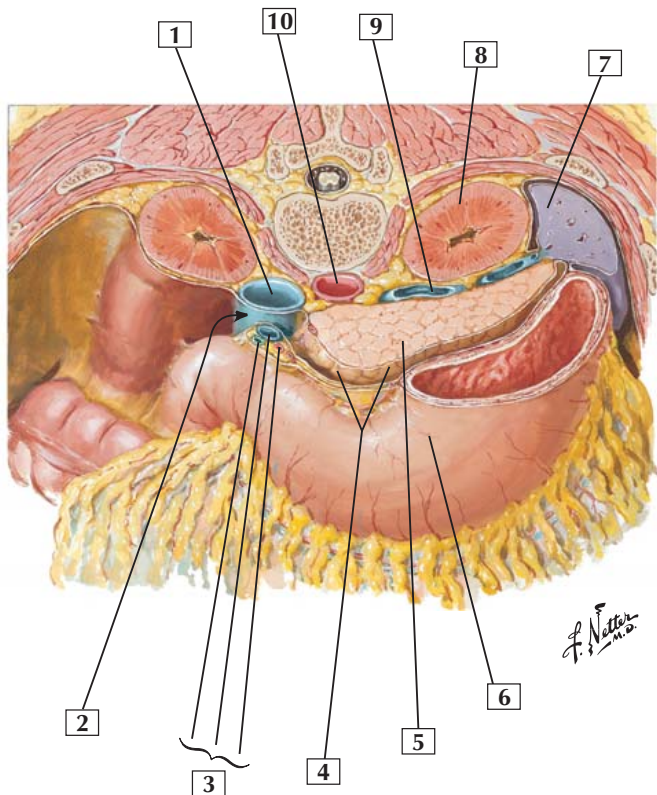
1. Stomach (posterior surface)
2. Probe in omental (epiploic) foramen
3. Gallbladder
4. Descending (2nd) part of duodenum
5. Head of pancreas (retroperitoneal)
6. Transverse mesocolon
7. Left colic (splenic) flexure
8. Spleen
9. Left suprarenal (adrenal) gland (retroperitoneal)

Comment: The greater omentum has been severed in this illustration, and the stomach has been elevated to show the lesser sac (the remainder of the abdominopelvic cavity is called the greater sac) residing posteriorly to the stomach and anteriorly to the retroperitoneal pancreas.

A probe enters the lesser sac through the epiploic foramen of Winslow. Anterior to the epiploic foramen lies the hepatoduodenal ligament, which is a portion of the lesser omentum (the other part is the hepatogastric ligament). Within the hepatoduodenal ligament one finds the proper hepatic artery, the common bile duct, and the portal vein.

Only a portion of the 2nd part of the duodenum is visible in this illustration. Similar to the pancreas, the duodenum is secondarily retroperitoneal.

Clinical: A perforated gastric ulcer in the posterior wall of the stomach could spill gastric contents into the lesser sac and its acidic juices may erode into the pancreas. Likewise, cancer of the pancreas could invade the duodenum, stomach, or spleen because of its close proximity to these structures.

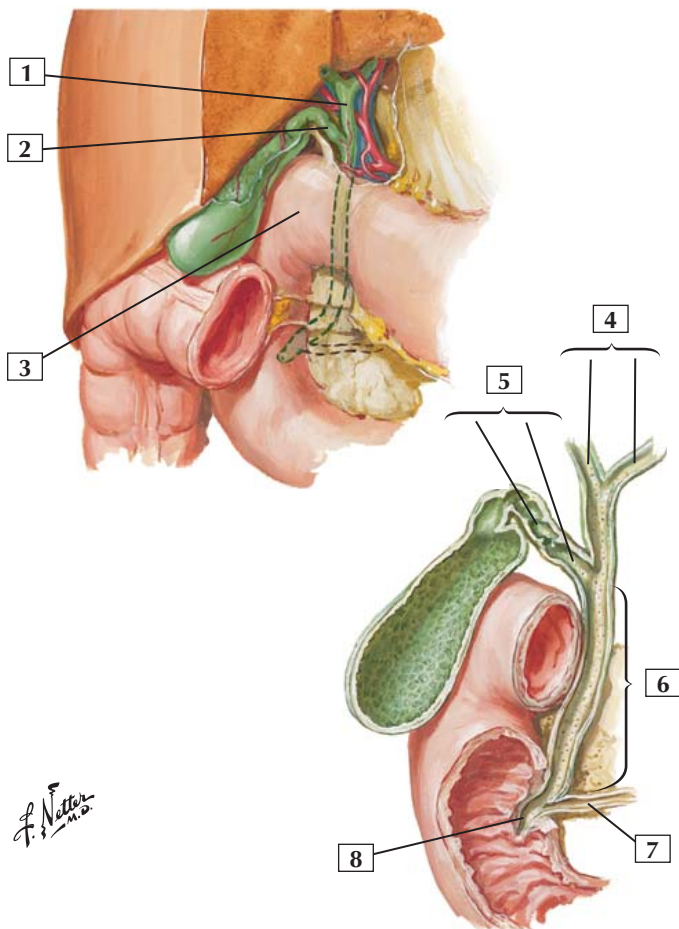


1. Inferior vena cava
2. Omental (epiploic) foramen (of Winslow)
3. Portal triad (Common bile duct; Hepatic portal vein; Proper hepatic artery)
4. Omental bursa (lesser sac)
5. Pancreas
6. Stomach
7. Spleen
8. Left kidney
9. Splenic vein
10. Abdominal aorta

Comment: The omental bursa, or lesser sac, resides posteriorly to the stomach and anteriorly to the pancreas, which lies retroperitoneally. Access to the lesser sac is through a small foramen called the epiploic foramen of Winslow. The rest of the abdominopelvic cavity is referred to as the greater sac.

The portal triad lies within the hepatoduodenal ligament, which is part of the lesser omentum (the other part is the hepatogastric ligament). Just posterior to this triad, one can access the inferior vena cava (the inferior vena cava and aorta are retroperitoneal).

Clinical: Note the location of the pancreas and its close proximity to a number of important epigastric structures, including the duodenum, stomach, spleen, left kidney and adrenal gland, and the aorta and inferior vena cava. Cancer from or trauma to the pancreas can have implications for any one of these structures that lies close to this important retroperitoneal organ.



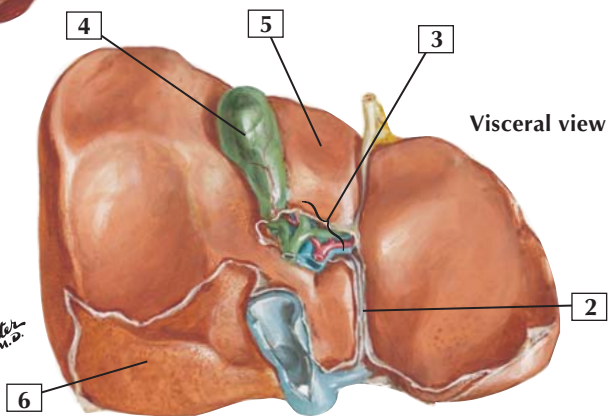
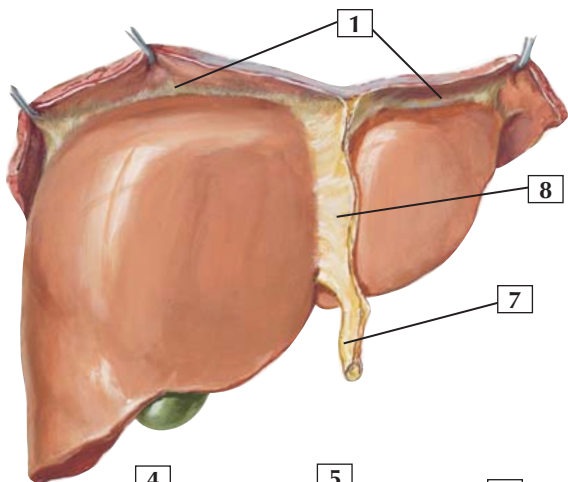
F. Netter
M.D.

1. Common hepatic duct
2. Cystic duct
3. Superior (1st) part of duodenum
4. Hepatic ducts (Right; Left)
5. Cystic duct (Spiral fold; Smooth part)
6. Common bile duct
7. Pancreatic duct
8. Hepatopancreatic ampulla (of Vater)

Comment: Bile leaves the liver by the right and left hepatic ducts, draining into a common hepatic duct. The latter drains via the cystic duct into the gallbladder, which concentrates and stores bile. When stimulated by autonomic nerves and cholecystokinin, the gallbladder contracts, sending bile down the cystic duct. The bile flows through the common bile duct to the major duodenal papilla, which empties into the descending duodenum. At this location, the common bile duct joins the main pancreatic duct to form the hepatopancreatic ampulla of Vater.

Clinical: Gallstones occur in 10-20% of adults; risk factors include increased age, obesity, and being female. About 80% of gallstones are cholesterol stones, and about 20% are pigment (bilirubin calcium salts) stones. Gallstones can block the flow of bile from the gallbladder to the duodenum and cause inflammation (cholecystitis) or block the hepatopancreatic ampulla and impede exocrine secretion from the pancreas. The pain of acute cholecystitis may be felt in the right upper abdominal quadrant, radiating laterally just beneath the right breast to the back just below the inferior angle of the right scapula.

Anterior view



*F. Netter
M.D.*

1. Coronary ligament
2. Fissure for ligamentum venosum
3. Porta hepatis
4. Gallbladder
5. Quadrate lobe
6. Bare area
7. Round ligament (ligamentum teres) of liver (obliterated umbilical vein) forming free border of falciform ligament
8. Falciform ligament

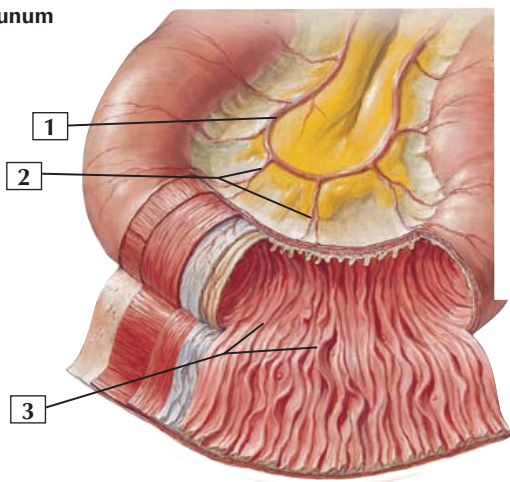
Comment: Visceral peritoneum reflects off the liver in the form of the falciform ligament and the coronary ligaments, which reflect off the right and left lobes of the liver and onto the underlying diaphragm. The bare area of the liver marks the portion of the liver not covered by visceral peritoneum because it is in direct contact with the diaphragm.

The round ligament of the liver is the obliterated umbilical vein. It is visible in the free margin of the falciform ligament. The round ligament joins the ligamentum venosum, which is the fused ductus venosus from the fetus. Before birth, this passageway allows umbilical blood coming from the placenta to bypass the liver and drain directly into the inferior vena cava and pass to the fetal heart.

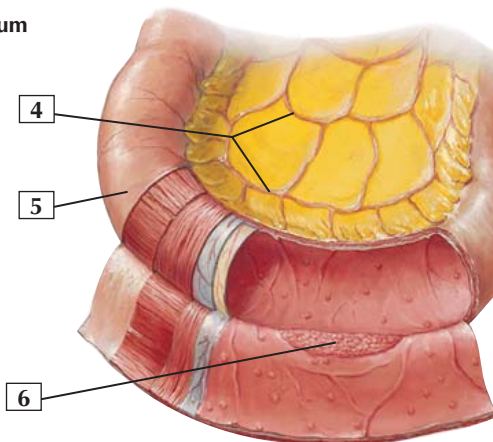
The liver is the largest solid organ in the body (the skin is the largest nonsolid organ) and functions in the production and secretion of bile, storage of nutrients, production of cellular fuels, plasma proteins, clotting factors, and detoxification and phagocytosis.

Clinical: Cirrhosis is a largely irreversible disease of the liver. Causes include alcoholic liver disease (60-70% of cases), viral hepatitis, biliary diseases, genetic hemochromatosis, and cryptogenic cirrhosis.

Jejunum



Ileum



F. Netter M.D.

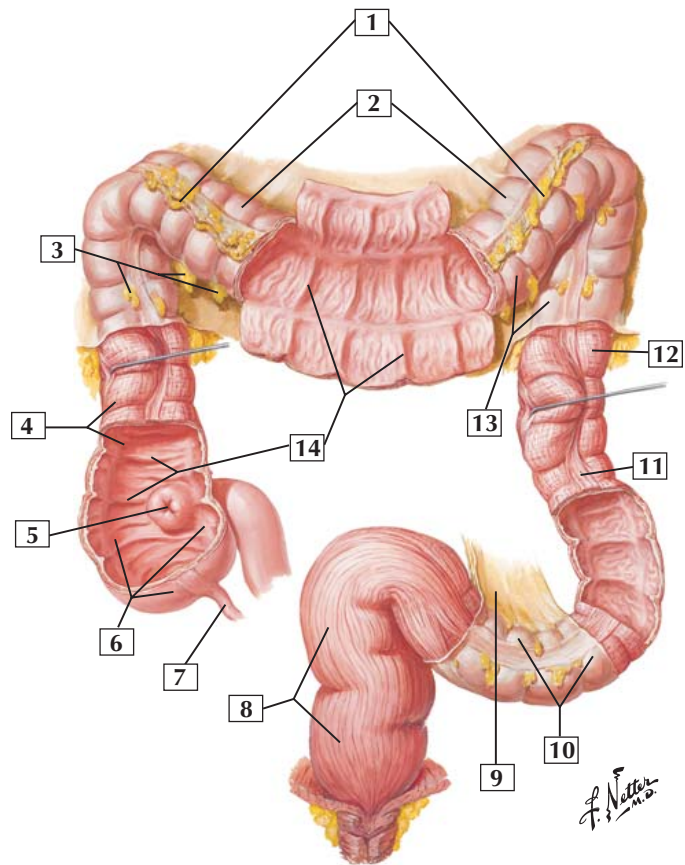
Mucosa and Musculature of Small Intestine

1. Anastomotic loop (arcade) of jejunal arteries
2. Straight arteries (arteriae rectae)
3. Circular folds (valves of Kerckring)
4. Anastomotic loops (arcades) of ileal arteries
5. Serosa (visceral peritoneum)
6. Aggregate lymphoid nodules (Peyer's patches)

Comment: The small intestine includes the duodenum (secondarily retroperitoneal), the jejunum (mesenteric), and the ileum (mesenteric). The jejunum constitutes the proximal two-fifths and the ileum the distal three-fifths of the mesenteric small intestine.

Several gross characteristics distinguish the jejunum from the ileum. The jejunum is larger in diameter and has longer straight arteries branching from its arterial arcades. It also has less fat in its mesentery and prominent circular folds of mucosa (plicae circulares) in its interior wall. More distally in the small bowel, the concentration of aggregated lymphoid nodules (Peyer's patches) increases.

Clinical: Crohn's disease is an idiopathic inflammatory bowel disease that may affect any segment of the gastrointestinal tract but usually involves the small intestine and colon. The disease presents as abdominal pain (periumbilical or lower right quadrant), diarrhea, fever, and several other symptoms and is most common between the ages of 15 and 30 years.



Mucosa and Musculature of Large Intestine

1. Greater omentum (*cut away*)
2. Transverse colon
3. Omental (epiploic) appendices (fat)
4. Ascending colon
5. Ileal orifice
6. Cecum
7. Appendix
8. Rectum
9. Sigmoid mesocolon
10. Sigmoid colon
11. Taenia coli
12. Descending colon
13. Haustra
14. Semilunar folds

Comment: The large intestine includes the cecum (and the appendix), ascending colon, transverse colon, descending colon, sigmoid colon, rectum, and anal canal.

Sacs of fat (omental appendices), longitudinal smooth muscle bands called taeniae coli (3 bands exist), and haustra are characteristic features of the colon. Functionally, the colon is responsible for dehydration and compaction of indigestible materials for elimination. The reabsorption of water and electrolytes and host defense mechanisms also are important functions.

The transverse and sigmoid colon are intraperitoneal and are tethered by a mesentery.

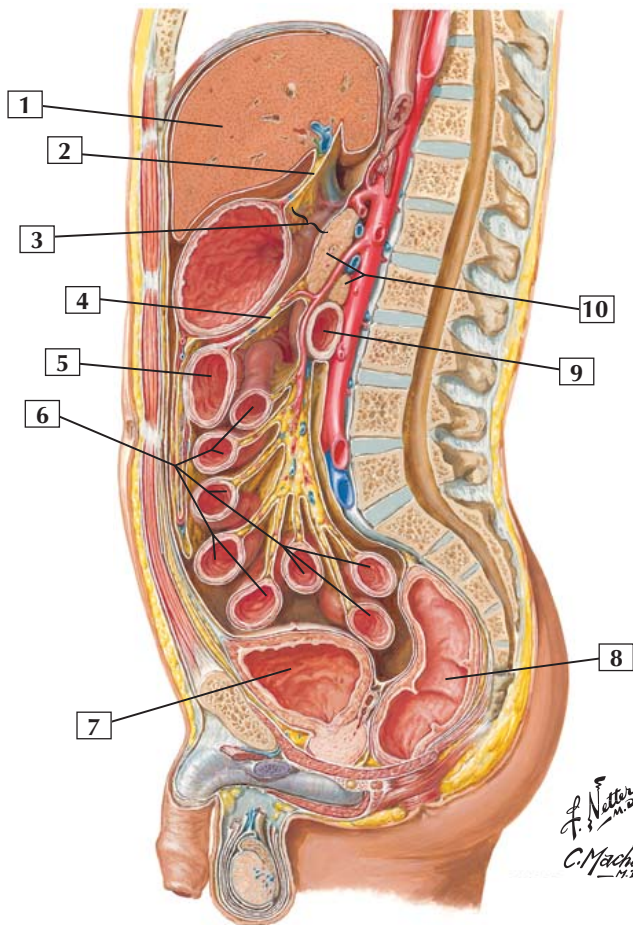
Clinical: Colorectal cancer is second only to lung cancer in site-specific mortality and accounts for almost 15% of cancer-related deaths in the United States.

1. Cortex
2. Medulla (pyramids)
3. Renal papilla
4. Medullary rays
5. Ureter
6. Minor calices
7. Renal pelvis
8. Major calices
9. Renal column

Comment: At the gross level, the interior of the human kidney is divided into an outer cortical layer and inner medullary layer.

At its apex, each medullary pyramid has a renal papilla in which the collecting ducts of the nephron deliver urine to minor and major calices. Several major calices coalesce to form the renal pelvis, which exits the kidney at its hilum and forms the ureter. The ureter conveys urine to the urinary bladder.

Clinical: Kidney stones (renal stones, nephrolithiasis) can form in the kidney and enter the urinary collecting system, where they may cause renal colic (loin to groin pain) and obstruction of the flow of urine from the kidney to the urinary bladder. The 3 most common sites of obstruction occur at the ureteropelvic junction at the hilum of the kidney, where the ureter crosses the common iliac vessels, at the pelvic brim, and at the ureterovesical junction as the ureter passes through the bladder's detrusor muscle wall.

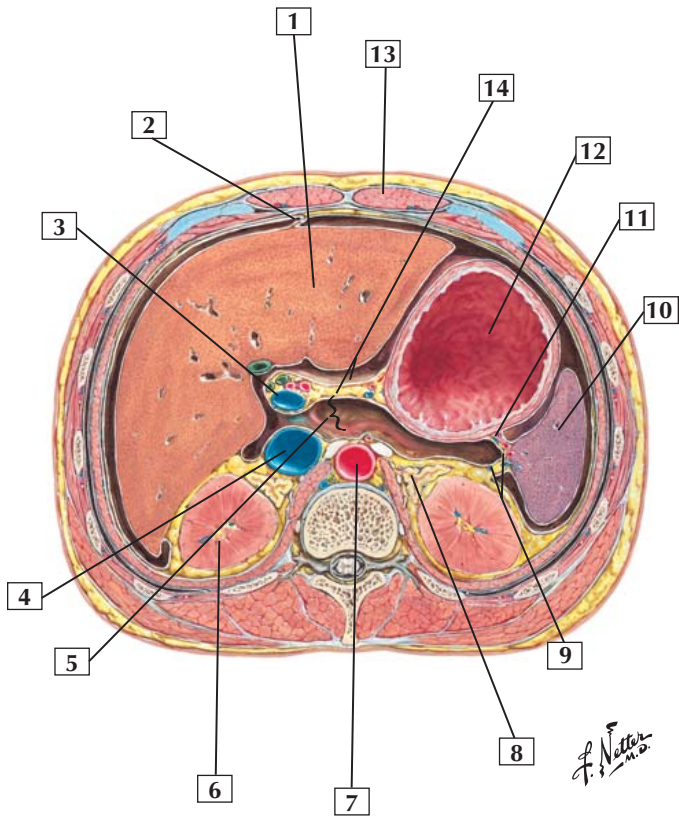


**Abdominal Wall and Viscera:
Median (Sagittal) Section**

1. Liver
2. Lesser omentum
3. Omental bursa (lesser sac)
4. Transverse mesocolon
5. Transverse colon
6. Small intestine
7. Urinary bladder
8. Rectum
9. Inferior (horizontal, or 3rd) part of duodenum
10. Pancreas

Comment: Reflections of the parietal and visceral peritoneum and their intervening mesenteries can be seen in this sagittal section. The stomach, small intestine (jejunum and ileum portions), transverse colon, and sigmoid colon are suspended in the peritoneal cavity by mesenteries. The other portions of the gastrointestinal tract are secondarily retroperitoneal.

Clinical: The abdominopelvic cavity is a potential space, normally containing only a small amount of serous lubricating fluid that allows the viscera to glide easily over one another during gastrointestinal peristalsis. The abnormal accumulation of serous fluid in this potential space is called ascites. Ascites can occur for a variety of reasons. In liver cirrhosis, the sinusoidal hypertension (portal hypertension) can contribute up to 10-20 L/day of weeping hepatic lymph that may collect in the peritoneal cavity and greatly distend the abdomen.



WWW.YAZDANPRESS.COM

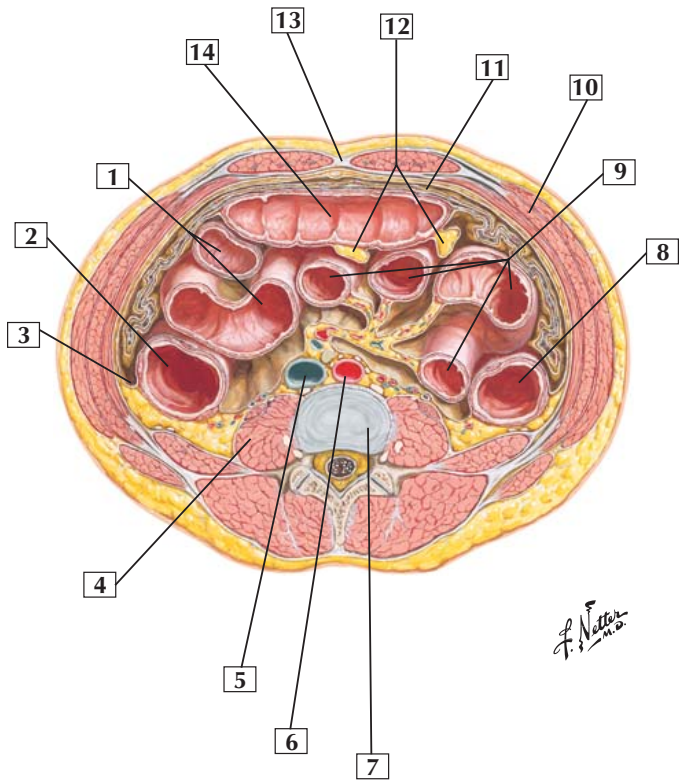
Schematic Cross Section of Abdomen at T12

1. Liver
2. Falciform ligament
3. Portal vein
4. Inferior vena cava
5. Omental bursa (lesser sac)
6. Right kidney
7. Abdominal aorta
8. Left suprarenal (adrenal) gland
9. Splenorenal ligament with splenic vessels
10. Spleen
11. Gastrosplenic ligament with short gastric vessels
12. Stomach
13. Rectus abdominis muscle (in rectus sheath)
14. Lesser omentum

Comment: In this cross section of the abdomen, the intraperitoneal viscera are represented by the liver, stomach, and spleen. Retroperitoneal viscera lying beneath the parietal peritoneum in the posterior abdominal wall include the right and left kidneys, suprarenal (adrenal) glands, aorta, and inferior vena cava.

Within the hepatoduodenal portion of the lesser omentum, one can see the portal vein, common bile duct, and proper hepatic artery.

Clinical: Note that the kidneys and adrenal glands are retroperitoneal organs, which lie posterior to the parietal peritoneum covering the posterior abdominal wall. Therefore, in some instances, these organs may be accessed surgically without entering the peritoneal cavity, thus reducing the chance for intra-abdominal infection.



Schematic Cross Section of Abdomen at L2 and L3

1. Ileum
2. Ascending colon
3. Right paracolic gutter
4. Psoas major muscle
5. Inferior vena cava
6. Abdominal aorta
7. Intervertebral disc (between L2 and L3 vertebral bodies)
8. Descending colon
9. Loops of jejunum
10. Internal oblique muscle
11. Greater omentum
12. Omental appendices (fat)
13. Linea alba
14. Transverse colon

Comment: This cross section of the lower abdominopelvic cavity shows the loops of the small bowel suspended by a mesentery. Also visible are portions of the ascending, transverse, and descending colon. The ascending and descending colon are secondarily retroperitoneal, having been pushed against the posterior abdominal wall during embryonic development of the gastrointestinal tract.

Clinical: Note the relationships of the abdominal viscera to the posterior, lateral, and anterior abdominal wall muscles. The greater omentum drapes over the intestines like a fatty apron and can “wall off” sites of inflammation within the peritoneal cavity by forming adhesions to protect the rest of the viscera. When this occurs, adhesions usually result (the inflamed visceral peritoneum scars and forms connective tissue adhesions with adjacent peritoneal surfaces). The adhesions may become significant and limit bowel motility, leading to reduced or obstructed flow through a bowel segment.



Bones and Joints

5-1 Bones and Ligaments of Pelvis

Muscles

5-2 Levator Ani (Puborectalis; Pubococcygeus; Iliococcygeus)

5-3 (Ischio-)coccygeus

5-4 Female Perineum

5-5 Compressor Urethrae and Sphincter Urethrovaginalis

5-6 Sphincter Urethrae (Female)

5-7 Male Perineum

5-8 Sphincter Urethrae (Male)

5-9 External Anal Sphincter (Deep; Superficial; Subcutaneous)

Nerves

5-10 Nerves of Pelvic Viscera: Female

5-11 Nerves of Perineum and External Genitalia: Female

5-12 Nerves of Perineum: Male

Vessels

5-13 Arteries of Female Pelvis

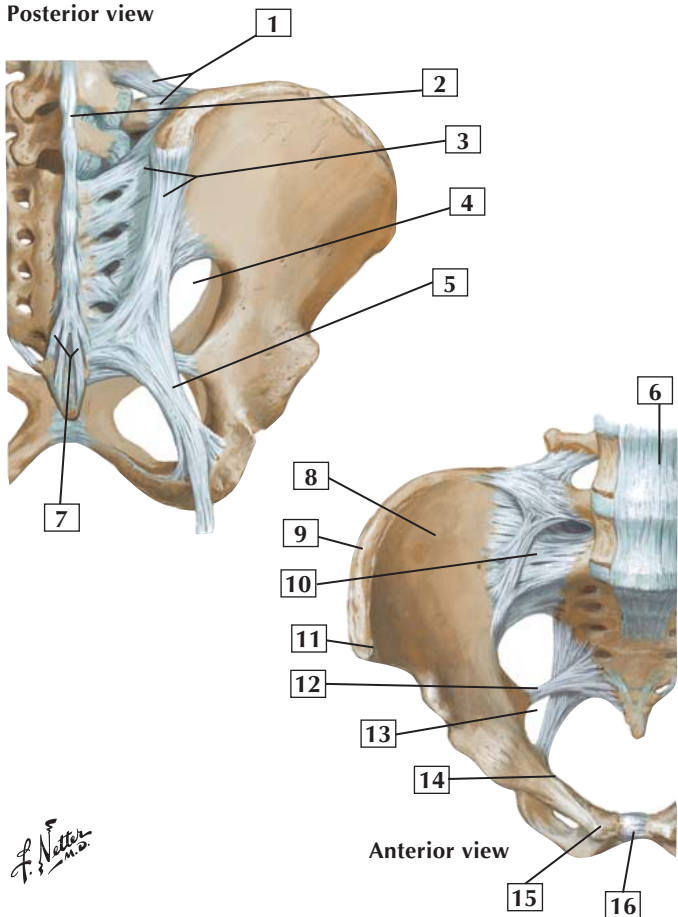
5-14 Arteries and Veins of Female Perineum

- 5-15** Veins of Rectum and Anal Canal
- 5-16** Arteries and Veins of Male Pelvis
- 5-17** Arteries and Veins of Male Perineum

Viscera

- 5-18** Female Pelvic Contents: Superior View
- 5-19** Support Structures of Female Pelvic Viscera
- 5-20** Female Perineum
- 5-21** Male Pelvic Contents: Superior View
- 5-22** Male Perineum and Penis

Posterior view



F. Netter M.D.

1. Iliolumbar ligament
2. Supraspinous ligament
3. Posterior sacroiliac ligaments
4. Greater sciatic foramen
5. Sacrotuberous ligament
6. Anterior longitudinal ligament
7. Posterior sacrococcygeal ligaments
8. Iliac fossa
9. Iliac crest
10. Anterior sacroiliac ligament
11. Anterior superior iliac spine
12. Sacrospinous ligament
13. Lesser sciatic foramen
14. Pectin pubis
15. Pubic tubercle
16. Pubic symphysis

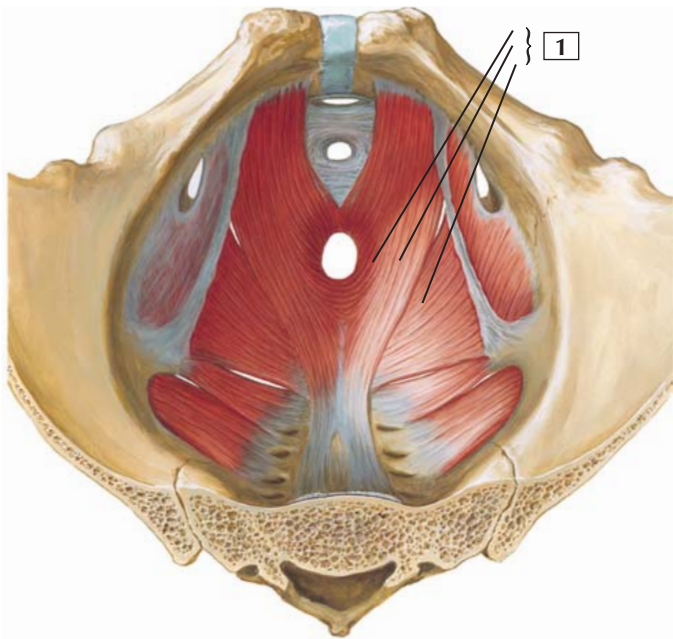
Comment: The sacroiliac joint is a plane synovial joint between the sacrum and ilium. It permits little movement. The sacroiliac joint transmits the weight of the body to the hip bone when a person is standing. It is reinforced by anterior, posterior, and interosseous sacroiliac ligaments.

The sacrococcygeal joint is a cartilaginous joint between the sacrum and coccyx. It allows some movement and contains an intervertebral disc between S5 and Co1.

The pubic symphysis is a cartilaginous (fibrocartilage) joint between the 2 pubic bones.

The sacrospinous ligament divides the greater sciatic foramen from the lesser sciatic foramen.

Superior view
(viscera removed)



*F. Netter
M.D.*

WWW.YAZDANPRESS.COM

Levator Ani (Puborectalis; Pubococcygeus; Iliococcygeus)

1. Levator ani (Puborectalis; Pubococcygeus; Iliococcygeus)

Origin: Arises from the body of the pubis, the arcus tendineus (actually a thickened portion of the obturator fascia) of the levator ani, and the ischial spine.

Insertion: Attaches to the coccyx, anococcygeal raphe, external anal sphincter, walls of the prostate, rectum, anal canal, and central tendon of the perineum.

Action: Supports and slightly raises the pelvic floor.

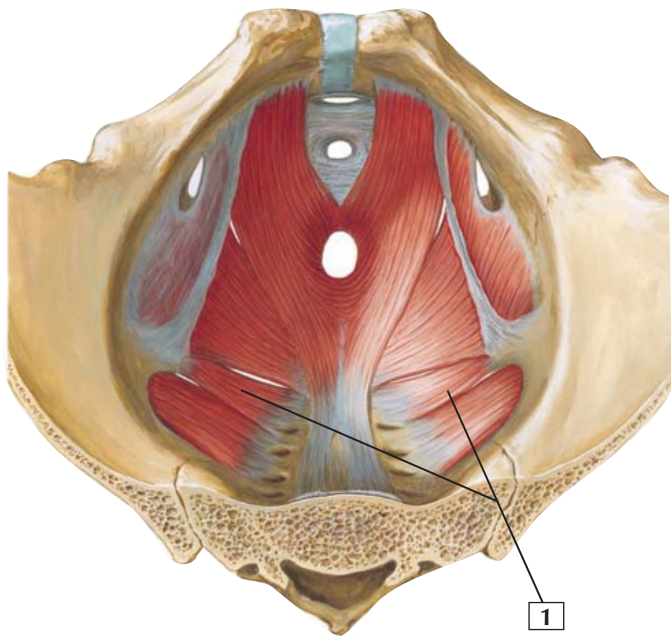
Innervation: Ventral rami of S3 and S4 and perineal branch of the pudendal nerve.

Comment: The levator ani has 3 parts: the puborectalis, the pubococcygeus, and the iliococcygeus muscles. With the coccygeus muscle, the levator ani forms the pelvic diaphragm.

The greater sciatic foramen exists superior to the pelvic diaphragm and provides a passageway for structures to leave the pelvic cavity and enter the gluteal region. The lesser sciatic foramen exists inferior to the pelvic diaphragm and provides a passageway for neurovascular structures to pass from the gluteal region to the perineum (importantly, the pudendal neurovascular bundle).

Clinical: The levator ani, as part of the pelvic diaphragm, provides an important support structure for the pelvic viscera, and especially the female reproductive viscera. It helps maintain the integrity of the uterus and vagina, as well as support the rectum and assist in defecation by straightening the anorectal junction in both sexes.

Superior view
(viscera removed)



*F. Netter
M.D.*

1. (Ischio-)coccygeus

Origin: Arises from the spine of the ischium and the sacrospinous ligament.

Insertion: Attaches to the coccyx and lower portion of the sacrum.

Action: With the levator ani, the coccygeus supports the pelvic floor. It also draws the coccyx forward after the latter has been pushed back during parturition (in females) or defecation.

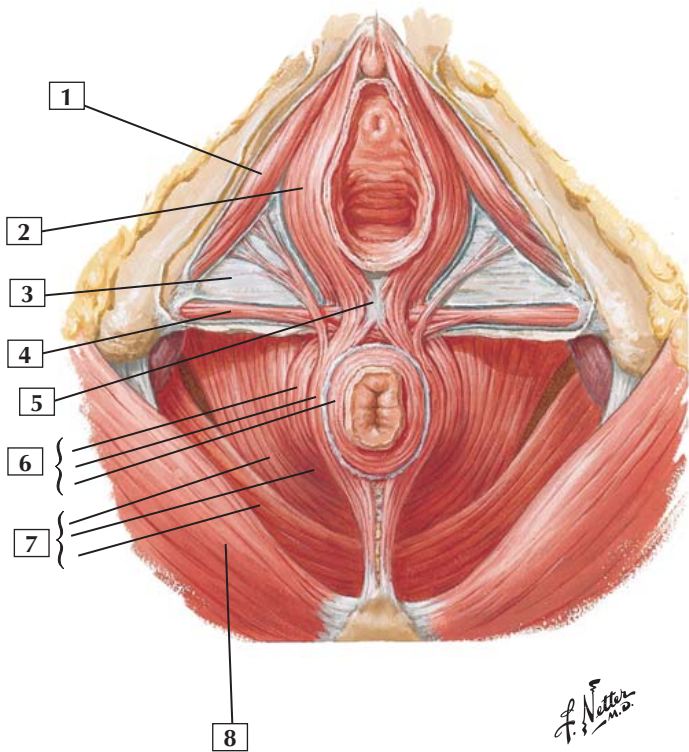
Innervation: Ventral rami of S4 and S5.

Comment: The pelvic diaphragm comprises the coccygeus and levator ani. Together, these muscles support and raise the pelvic floor.

The coccygeus muscle is the muscle used by dogs to tuck their tails between their hind legs; in humans, it is largely a mixture of skeletal muscle fibers and fibrous connective tissue.

The greater sciatic foramen exists superior to the pelvic diaphragm and provides a passageway for structures to leave the pelvic cavity and enter the gluteal region. The lesser sciatic foramen exists inferior to the pelvic diaphragm and provides a passageway for neurovascular structures to pass from the gluteal region to the perineum (importantly, the pudendal neurovascular bundle).

Clinical: Assisting the levator ani, the coccygeus pulls the coccyx forward after defecation and forms the posterior portion of the pelvic diaphragm.



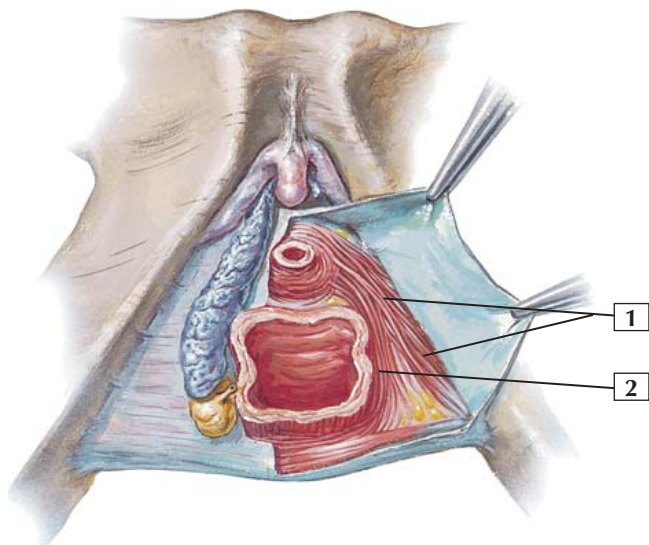
1. Ischiocavernosus muscle with deep perineal (investing or Gallaudet's) fascia removed
2. Bulbospongiosus muscle with deep perineal (investing or Gallaudet's) fascia removed
3. Perineal membrane
4. Superficial transverse perineal muscle with deep perineal (investing or Gallaudet's) fascia removed
5. Perineal body
6. Parts of external anal sphincter muscle (Deep; Superficial; Subcutaneous)
7. Levator ani muscle (Pubococcygeus; Puborectalis; Iliococcygeus)
8. Gluteus maximus muscle

Comment: The muscles of the perineum are skeletal muscles. They are innervated by the pudendal nerve and its branches (ventral rami of S2-4).

The central tendon of the perineum (perineal body) is a mass of fibromuscular tissue found in the midline between the anus and vagina. It is an attachment point for many of the muscles of the perineum and is important for maintaining the integrity of this region.

Clinical: An episiotomy is a surgical incision usually made posteriorly (median incision) or posterolateral in the inferoposterior wall of the vagina to enlarge the vaginal opening during childbirth. This procedure is done only if the normal delivery might result in a tear of the perineum and perineal body, which would disrupt the integrity of the perineum. The episiotomy is easier to suture after delivery than to try to repair a nasty tear of the perineal body.

Female



C. Machado
M.D.

WWW.YAZDANPRESS.COM

Compressor Urethrae and Sphincter Urethrovaginalis

1. Compressor urethrae
2. Sphincter urethrovaginalis

Comment: The anatomy of these muscles is controversial. The urethral sphincter might be more of a “urogenital sphincter,” consisting of a compressor urethrae muscle and a sphincter urethrovaginalis muscle. The sphincter action of these muscles is debatable.

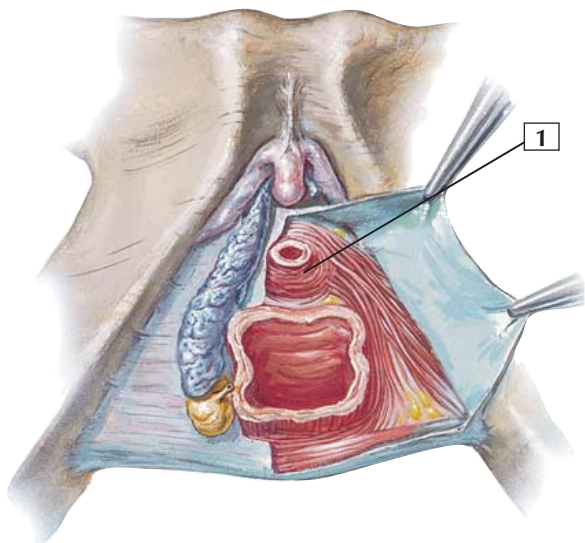
These muscles are innervated primarily by the perineal branch of the pudendal nerve (S2-4).

On one side of this illustration, the ischiocavernosus and bulbospongiosus muscles have been removed to show the underlying erectile tissues of the bulb of the vestibule and the crus of the clitoris (still ensheathed in a fascial layer). Posterior to the bulb of the vestibule lies the greater vestibular (Bartholin's) gland, which secretes mucus during sexual arousal that lubricates the vaginal opening.

Clinical: During childbirth, the urogenital sphincter complex can be stretched, weakening their actions both as sphincters and support structures of the lower perineum.

Urinary tract infections are more common in women, in part because of their shorter urethra and the proximity to pathogens that may be present in the vestibule (the region defined by the labia minora).

Female



C. Machado
— M.D.

1. Sphincter urethrae (female)

Origin: Arises from the inferior pubic ramus.

Insertion: Attaches to a median raphe and the perineal body.

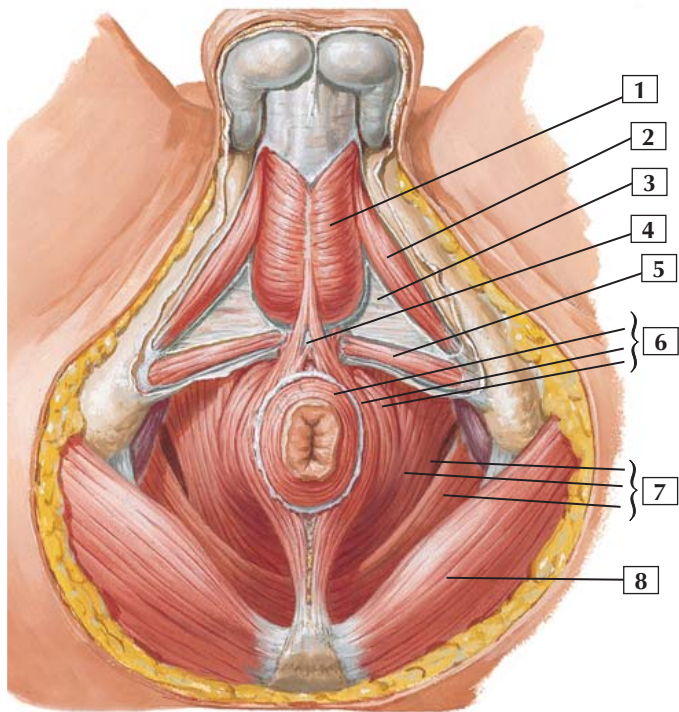
Action: The muscles on both sides act together to constrict the urethra.

Innervation: Perineal branch of the pudendal nerve (S2-4).

Comment: In women, this muscle blends with the compressor urethrae muscle and the urethrovaginal sphincter muscles.

Although some textbooks call this muscle the “external” urethral sphincter, women do not possess an internal urethral sphincter (smooth muscle sphincter at the neck of the urinary bladder), which is a sphincter muscle found only in men.

Clinical: Stretching during childbirth can weaken the integrity of the urogenital sphincter (sphincter urethrae and compressor urethrae muscles) as well as the support structures of the reproductive viscera (pelvic diaphragm, pubovesical and cervical ligaments), leading to stress incontinence, in which there is an involuntary loss of urine after an increase in intra-abdominal pressure.



*F. Netter
M.D.*

1. Bulbospongiosus muscle with deep perineal (investing or Gallaudet's) fascia removed
2. Ischiocavernosus muscle with deep perineal (investing or Gallaudet's) fascia removed
3. Perineal membrane
4. Perineal body
5. Superficial transverse perineal muscle with deep perineal (investing or Gallaudet's) fascia removed
6. Parts of external anal sphincter muscle (Subcutaneous; Superficial; Deep)
7. Levator ani muscle (Pubococcygeus; Puborectalis; Iliococcygeus)
8. Gluteus maximus muscle

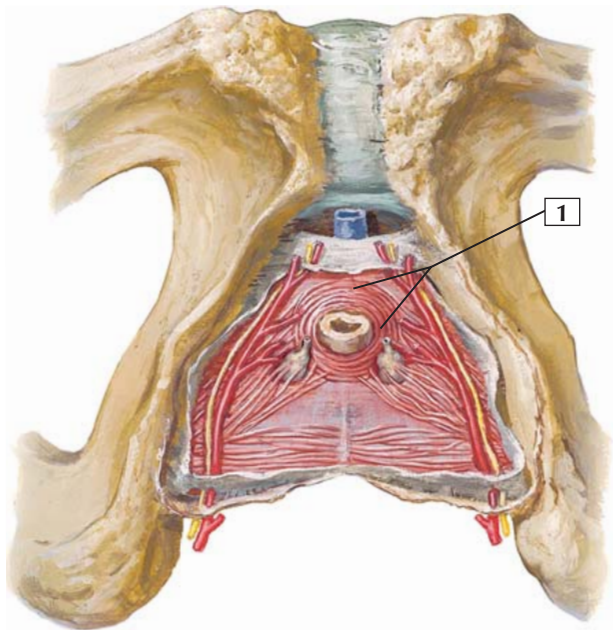
Comment: The muscles of the male perineum are skeletal in nature and are innervated by the pudendal nerve and its branches. Many of these muscles have attachments to the central tendon of the perineum (perineal body). The perineal body is a midline structure located just anterior to the anal canal and just behind the bulb of the penis.

This illustration shows the subdivision of the diamond-shaped perineum into an anterior urogenital triangle and a posterior anal triangle. An imaginary horizontal line connecting the 2 ischial tuberosities divides the perineum into these 2 descriptive triangles.

The ischiocavernosus and bulbospongiosus muscles cover the crus of the penis (corpus cavernosum) and the bulb of the penis (corpus spongiosum). These bodies are the erectile tissue of the penis.

Clinical: Contraction of the bulbospongiosus muscle helps to evacuate any remaining urine in the spongy urethra.

Male-Inferior view



*F. Netter
M.D.*

1. Sphincter urethrae (male)

Origin: Arises from the ischiopubic ramus.

Insertion: Inserts into a median raphe and the perineal body and extends superoanterior along the prostate to the neck of the urinary bladder.

Action: Acting together, muscles on both sides form a sphincter that compresses the membranous portion of the male urethra.

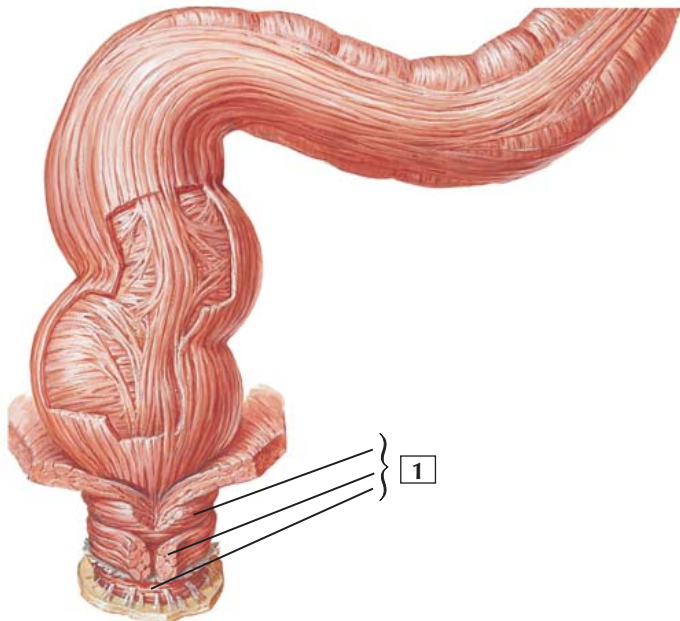
Innervation: Perineal branch of the pudendal nerve (S2-4).

Comment: In men, only a portion of the muscle forms a true sphincter of the urethra (external urethral sphincter). It is thought that another portion of the muscle extends vertically to the bladder and invests the prostatic urethra anteriorly and laterally. It is unknown how or whether this muscle acts on the prostatic urethra.

At the neck of the male urinary bladder, an internal urethral sphincter (smooth muscle, sympathetically innervated from L1-2) exists that is important during ejaculation because it prevents semen from entering the urinary bladder or urine from entering the prostatic urethra.

Clinical: Erectile dysfunction is an inability to achieve and/or maintain penile erection sufficient for sexual intercourse. Normally, sexual stimulation releases nitric oxide from nerve endings and vascular endothelial cells, thus relaxing the smooth muscle tone and increasing blood flow, which then compresses the veins draining the erectile tissues and allows for engorgement of the tissues. Drugs that treat erectile dysfunction aid in the relaxation of the smooth muscle.

Anterior view



*F. Netter
M.D.*

WWW.YAZDANPRESS.COM

External Anal Sphincter (Deep; Superficial; Subcutaneous)

1. External anal sphincter (Deep; Superficial; Subcutaneous)

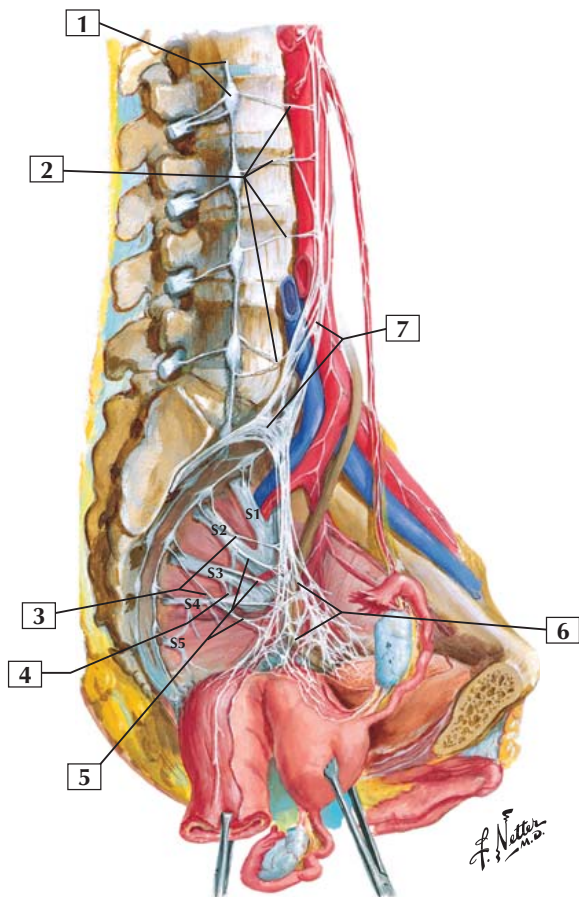
Attachments: Surrounds the last 2 cm of the anal canal and consists of subcutaneous, superficial, and deep portions. Some fibers attach anteriorly to the perineal body and posteriorly to the anococcygeal ligament. Fibers also may join the superficial transverse perineal muscle, the levator ani, and the bulbospongiosus. Deep fibers interlace with the puborectalis muscle.

Action: This muscle is in a tonic state of contraction and has no antagonist. It keeps the anal canal closed.

Innervation: Supplied by the inferior rectal branches (largely S4) of the pudendal nerve (S2-4).

Comment: An internal sphincter lies deep to the external anal sphincter. This smooth muscle sphincter is under involuntary control. Sympathetic fibers maintain its tonic contraction, whereas parasympathetic fibers relax muscle tone and permit expansion of the anal canal during defecation or flatulence. This action also requires that the external anal sphincter be relaxed simultaneously.

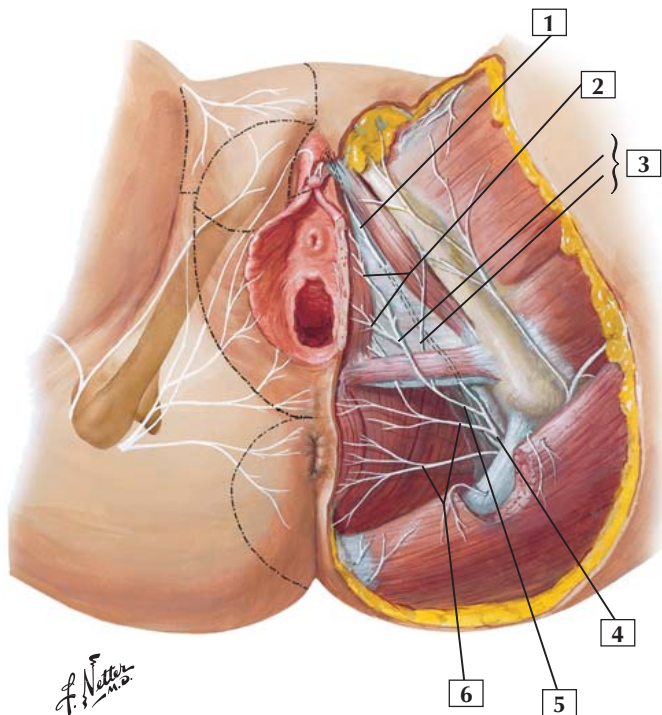
Clinical: Trauma to the anal mucosal lining (e.g., from compacted feces) can lead to an anal infection that can spread into the adjacent sphincter muscles and beyond, into the ischioanal fossae of the fat-filled anal triangle.



1. Sympathetic trunk and L2 ganglion
2. Lumbar splanchnic nerves
3. Sacral splanchnic nerves (sympathetic)
4. Pudendal nerve
5. Pelvic splanchnic nerves (parasympathetic)
6. Inferior hypogastric (pelvic) plexus
7. Superior hypogastric plexus

Comment: The female pelvic viscera are innervated largely by the lower portion of the parasympathetic division of the autonomic nervous system. These parasympathetic preganglionic fibers arise as the pelvic splanchnic nerves from the nerve roots of S2, S3, and S4. Many of these preganglionic parasympathetic fibers synapse in the inferior hypogastric (pelvic) plexus, adjacent to the rectum, uterus, ovary, and uterine tubes. Postganglionic parasympathetics from the inferior hypogastric plexus course to the respective pelvic viscera.

Clinical: Pain afferents from the ovaries, uterine tubes, and the fundus and body of the uterus follow sympathetic fibers back to the spinal cord (T11 or T12 to L1-2 levels). Pain fibers from the uterine cervix and vagina (subperitoneal structures) travel back to the spinal cord via the pelvic splanchnic nerves (S2-4). Cell bodies for these pain afferents reside in the dorsal root ganglia of the respective spinal cord levels. Therefore, pain from the pelvic and perineal viscera is felt over the dermatome areas T11-L2 and S2-4 and are largely confined to the hypogastric region, pelvis, and perineum and occasionally radiate into the upper part of the lower limb.



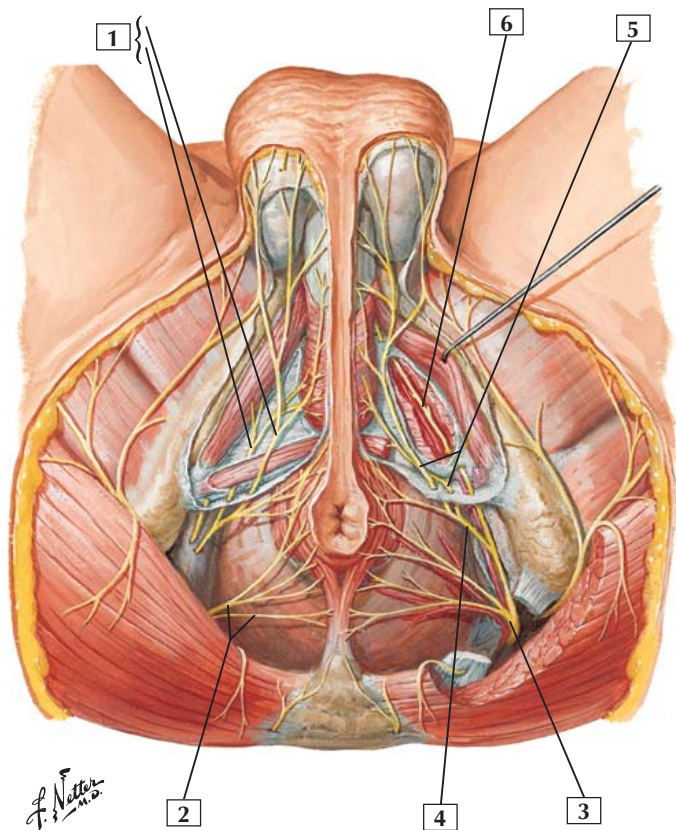
Nerves of Perineum and External Genitalia: Female

1. Dorsal nerve of clitoris
2. Posterior labial nerves
3. Branches of perineal nerve (Superficial; Deep)
4. Pudendal nerve in pudendal (Alcock's) canal (dissected)
5. Perineal nerve
6. Inferior anal (rectal) nerves

Comment: The pudendal nerve (somatic nerve) innervates the skin and skeletal muscle of the female perineum and external genitalia. It arises from the ventral rami of S2, S3, and S4 spinal cord levels. After emerging from the pudendal (Alcock's) canal, the pudendal nerve divides into inferior anal (rectal) nerves, the perineal nerve, and the dorsal nerve of the clitoris.

Parasympathetic fibers arise from the S2-4 levels; travel in pelvic splanchnic nerves to the inferior hypogastric plexus and uterovaginal plexus; and stimulate vaginal secretions, erection of the clitoris, and engorgement of the bulbs of the vestibule (vasodilation of the arteries supplying the erectile tissue of the clitoris and vestibular bulb).

Clinical: In some cases it is necessary to achieve local anesthesia of the perineal area, and the pudendal nerve may be blocked selectively by infiltrating a local anesthetic into the region of the pudendal canal, thus numbing the S2-4 somatic region (skin and skeletal muscle) of the perineum.



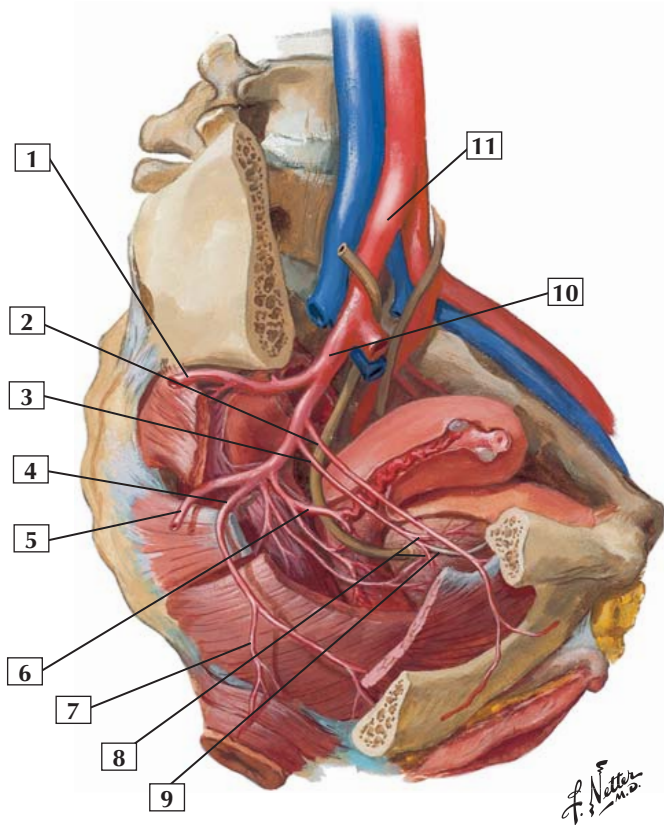
1. Perineal nerves (Superficial; Deep)
2. Inferior anal (rectal) nerves
3. Pudendal nerve
4. Perineal nerve
5. Superficial and deep branches of perineal nerve
6. Dorsal nerve of penis (continuation of pudendal nerve supplying muscles on superior aspect of perineal membrane)

Comment: The pudendal nerve and its branches innervate the skin and skeletal muscles of the male perineum. The nerve arises from ventral rami of S2, S3, and S4 spinal cord levels. After emerging from the pudendal (Alcock's) canal, the pudendal nerve divides into inferior anal (rectal) nerves, the perineal nerve, superficial and deep branches of the perineal nerve (which also supply the scrotum), and the dorsal nerve of the penis.

Parasympathetic fibers arise from the S2-4 levels, travel in pelvic splanchnic nerves to the inferior hypogastric plexus and prostatic nerve plexus, and stimulate the release of nitric oxide from the nerve endings and endothelial cells of the erectile tissues, which relaxes smooth muscle tone and increases blood flow to permit erection.

Clinical: Erectile dysfunction is the inability to achieve or maintain penile erection sufficient for sexual intercourse. Nitric oxide released by the pelvic splanchnic parasympathetic nerve fibers and endothelial cells normally causes the dilation of the arteries supplying blood to the erectile tissues. When this mechanism is compromised, erectile dysfunction results. Drugs that are used to treat this disorder aid smooth muscle relaxation by augmenting the action of nitric oxide.

Right paramedian section:
lateral view

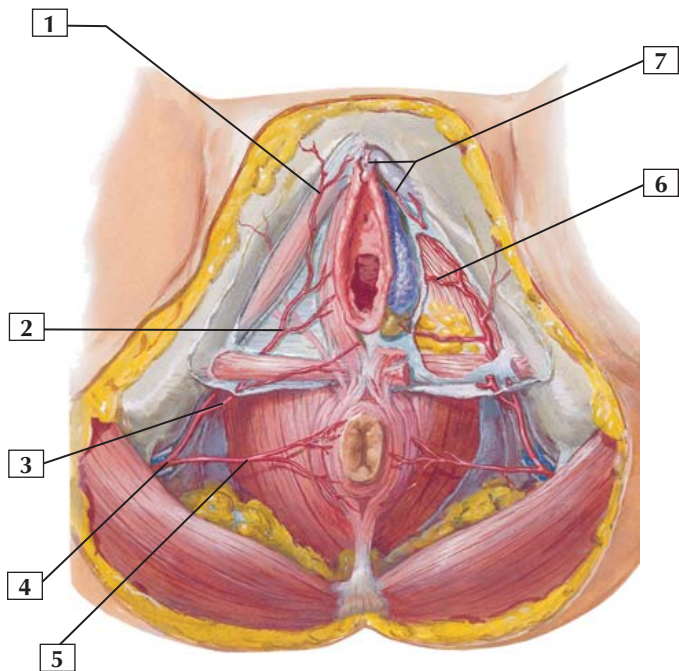


1. Superior gluteal artery
2. Obturator artery
3. Umbilical artery (patent part)
4. Internal pudendal artery
5. Inferior gluteal artery
6. Uterine artery
7. Inferior rectal artery
8. Superior vesical arteries
9. Umbilical artery (occluded part)
10. Internal iliac artery
11. Right common iliac artery

Comment: The internal iliac artery is the primary blood supply for the pelvic viscera and perineum. It divides into an anterior trunk (which largely supplies pelvic viscera and the perineum) and a posterior trunk. Branches of the posterior trunk generally supply the pelvic walls or pass through the greater sciatic foramen into the gluteal region. The branching pattern of the internal iliac artery varies greatly, so it is advisable to name the arteries according to the structures that they supply.

Veins draining the corresponding structures are similarly identified and named. These veins drain into the internal iliac vein and into the common iliac vein on each side.

Clinical: Cancer cells originating in the pelvic viscera may spread (metastasize) via the venous system and will generally follow the venous drainage back toward the central circulation. For most of the pelvic viscera this means via the inferior vena cava, although some spread to the adjacent veins of the vertebral column is also common.



F. Netter
M.D.

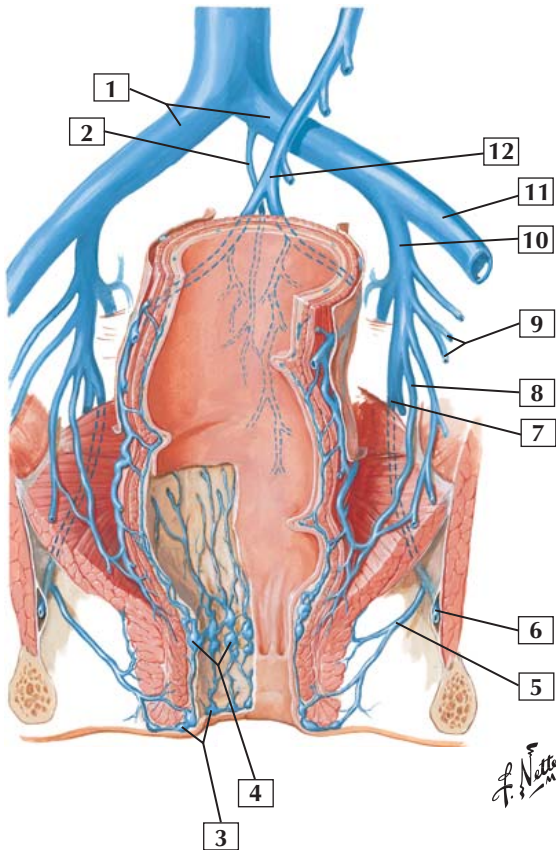
1. Posterior labial artery
2. Perineal artery
3. Perineal artery
4. Internal pudendal artery in pudendal (Alcock's) canal
5. Inferior rectal artery
6. Artery to bulb of vestibule
7. Dorsal artery of clitoris

Comment: The internal pudendal artery is a branch of the anterior division of the internal iliac artery. It courses to the perineum by passing through the lesser sciatic foramen and the pudendal (Alcock's) canal.

In the perineum, the internal pudendal artery gives off the inferior rectal artery and the perineal artery. Branches of the perineal artery supply the bulb of the vestibule and clitoris.

Venous branches accompany all the branches of the internal pudendal artery. Their names correspond to the names of the arterial branches.

Clinical: The rich lymphatic network of the perineum drains largely to the superficial inguinal lymph nodes and then along the iliac nodes to the para-aortic (lumbar) nodes in the abdomen. Infections and cancer cells traveling in the lymphatics follow this same pathway.

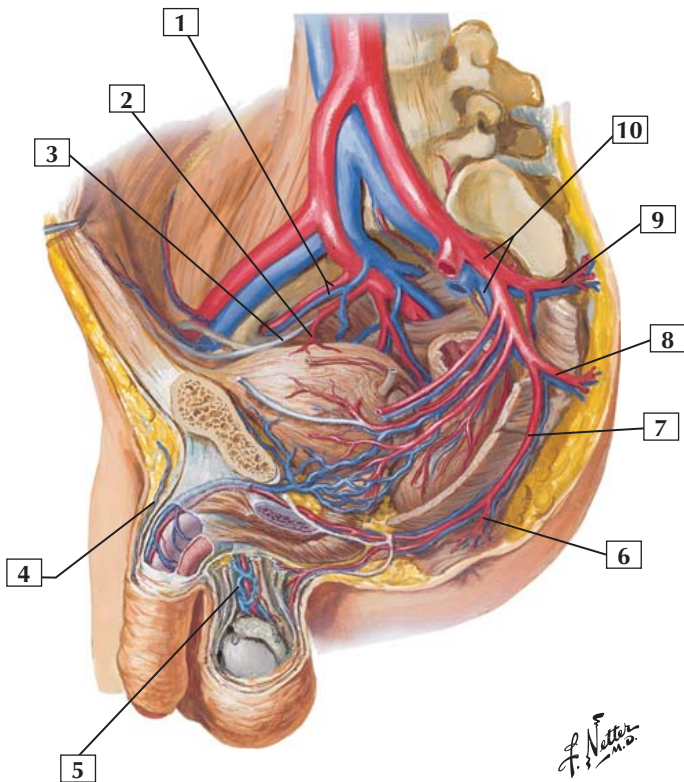


1. Common iliac veins
2. Median sacral vein
3. External rectal plexus
4. Internal rectal plexus
5. Inferior rectal vein
6. Internal pudendal vein (in pudendal [Alcock's] canal)
7. Internal pudendal vein
8. Middle rectal vein
9. Superior vesical and uterine veins
10. Internal iliac vein
11. External iliac vein
12. Superior rectal vein (from inferior mesenteric vein)

Comment: The veins draining blood from the rectum and anal canal comprise 3 sets of veins: inferior and middle rectal veins from the internal pudendal vein (caval system) and the superior rectal vein from the inferior mesenteric vein (portal system). These valveless veins provide an important portacaval anastomosis around the rectum should the venous return by the portal or caval system be impeded. Note the extensive anastomoses between the venous tributaries in the walls of the anal canal and rectum. Corresponding arteries accompany these veins.

Clinical: Hemorrhoids are symptomatic varicose dilations of submucosal veins that protrude into the anal canal or extend through the anus and affect 50-80% of individuals (more common after pregnancy). Usually, they are described as internal hemorrhoids (dilations of veins of internal rectal plexus), external hemorrhoids (dilations of veins of external rectal plexus), or mixed (combination of both).

Left paramedian section:
lateral view



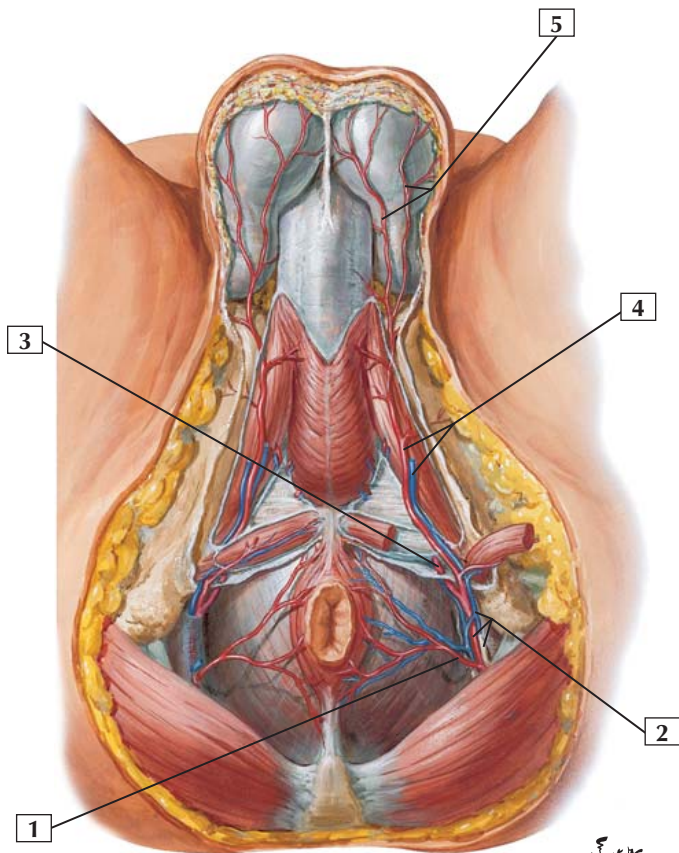
*F. Netter
M.D.*

1. Right obturator vessels
2. Superior vesical artery
3. Umbilical artery (occluded part)
4. Superficial dorsal vein of penis
5. Pampiniform (venous) plexus
6. Inferior rectal artery
7. Internal pudendal artery
8. Inferior gluteal artery
9. Superior gluteal artery
10. Internal iliac vessels

Comment: The internal iliac artery supplies the pelvic structures, perineum, and external genitalia.

Within the spermatic cord, the pampiniform venous plexus surrounds the testicular artery and drains blood from the testes into the testicular vein. The pampiniform venous plexus acts as a countercurrent cooling mechanism that cools the arterial blood flowing in the testicular artery. Spermatogenesis occurs only if the temperature is lower than body temperature; the testes reside in the scrotum and possess this countercurrent mechanism to maintain the appropriate ambient temperature.

Clinical: A rich venous plexus surrounds the base of the prostate gland. Cancer cells originating from the prostate may metastasize via these venous channels to the inferior vena cava and lungs as well as spreading to the rich venous plexus of the pelvic bones, sacrum, and vertebral column.



F. Netter
M.D.

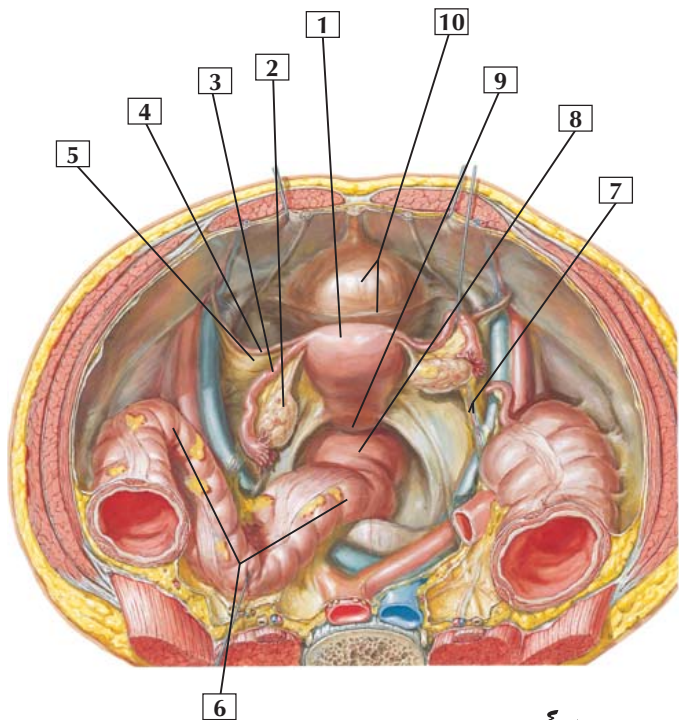
1. Inferior rectal artery
2. Internal pudendal vessels and pudendal nerve (cut) in pudendal (Alcock's) canal (opened up)
3. Internal pudendal artery passes superior to perineal membrane
4. Perineal artery and vein
5. Posterior scrotal arteries

Comment: The internal pudendal artery is a branch of the anterior division of the internal iliac artery. It enters the perineum by passing out of the gluteal region through the lesser sciatic foramen and coursing through the pudendal (Alcock's) canal.

The internal pudendal artery gives rise to the inferior rectal artery and the perineal artery. Branches of the perineal artery supply the bulb of the penis, the penis, and the scrotum.

Venous tributaries accompany the branches of the internal pudendal artery. The names of these veins correspond to the names of the arterial branches.

Clinical: The extravasation of urine from a rupture of the spongy urethra can spread into the superficial pouch of the urogenital triangle, into the scrotum beneath the dartos fascia, around the penis between the dartos and deep penial (Buck's) fascia, and into the lower abdominal wall beneath the membranous (Scarpa's) fascia.



*F. Natter
M.D.*



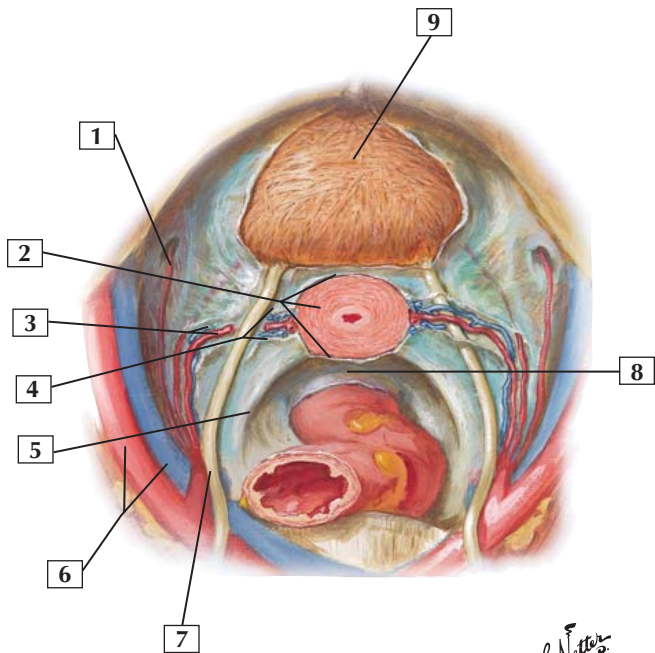
1. Uterus (fundus)
2. Ovary
3. Uterine (fallopian) tube
4. Round ligament of uterus
5. Broad (lateral uterine) ligament
6. Sigmoid colon
7. Suspensory ligament of ovary (contains ovarian vessels)
8. Rectum
9. Rectouterine pouch (cul-de-sac of Douglas)
10. Urinary bladder

Comment: In women, the peritoneum passes from the anterior abdominal wall over the superior surface of the urinary bladder. It then passes from the bladder to the uterus, forming the vesicouterine pouch between these 2 structures. The peritoneum continues over the fundus and body of the uterus, the posterior fornix, and wall of the vagina; it then reflects onto the anterior and lateral sides of the rectum. Between the rectum and uterus lies the rectouterine pouch. Posteriorly and superiorly, the peritoneum becomes the sigmoid mesocolon.

Within the suspensory ligament of the ovary lie the ovarian vessels, nerves, and lymphatics.

The round ligament of the uterus passes anteriorly and laterally to the deep, or internal, inguinal ring.

Clinical: The broad ligament of the uterus provides some support to the uterus and, along with the pelvic diaphragm and various ligaments, especially the cardinal and uterosacral ligaments, helps keep the uterus from prolapsing.



F. Netter M.D.

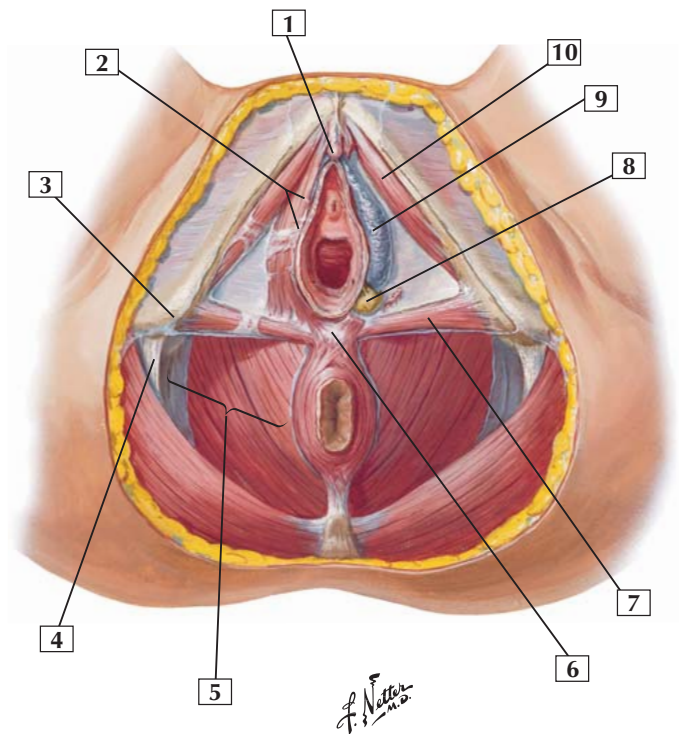
Support Structures of Female Pelvic Viscera

1. Obturator artery
2. Cervix of uterus and uterovaginal fascia
3. Uterine vessels
4. Cardinal (transverse or Mackenrodt's) ligament
5. Uterosacral fold (uterosacral ligaments lie in this fold)
6. External iliac vessels
7. Ureter
8. Rectouterine pouch (of Douglas)
9. Urinary bladder (vesical fascia partially removed)

Comment: In addition to the pelvic diaphragm (levator ani and coccygeus muscles) and the broad ligament, several important subperitoneal ligaments aid in the support of the uterus, including the cardinal and uterosacral ligaments. The uterine vessels run within the superior margin of the cardinal ligament, passing over the ureters (as shown on one side but bisected on the other side to show the ureter).

Clinical: Uterine prolapse involves the loss of support by cardinal and uterosacral ligaments and the pelvic diaphragm (levator ani portion). When these important support structures are weakened, the broad ligament alone is not sufficient to support the uterus or prevent its prolapse.

The uterus may descend slightly (common in parous women) or may reach the vaginal orifice or beyond (complete prolapse).

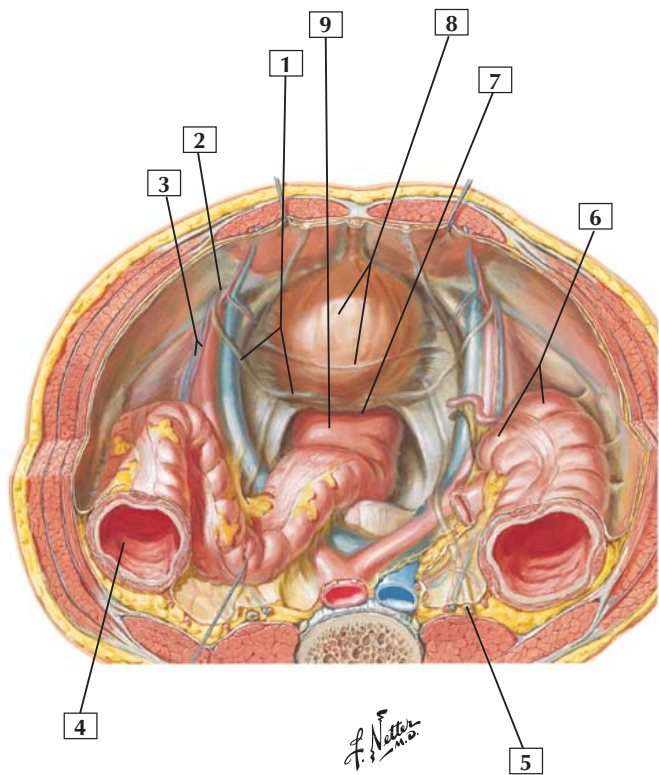


1. Clitoris
2. Bulbospongiosus muscle
3. Ischial tuberosity
4. Sacrotuberous ligament
5. Ischioanal fossa
6. Perineal body
7. Superficial transverse perineal muscle
8. Greater vestibular (Bartholin's) gland
9. Bulb of vestibule
10. Ischiocavernosus muscle

Comment: The perineum is the region between the proximal portions of the thighs. This diamond-shaped area extends from the mons pubis anteriorly to the medial surfaces of the thighs laterally (ischial tuberosities) and to the coccyx posteriorly.

A horizontal line joining the two ischial tuberosities divides the diamond-shaped perineum into an anterior urogenital triangle and a posterior anal triangle.

Clinical: The perineal body is a fibromuscular mass that marks the point of convergence of the bulbospongiosus muscle, external anal sphincter, and transverse perineal muscles. It provides important support to the perineum and pelvic viscera. If the perineal body is torn (e.g., during childbirth) and not properly repaired, its support function is compromised and vaginal prolapse may result.

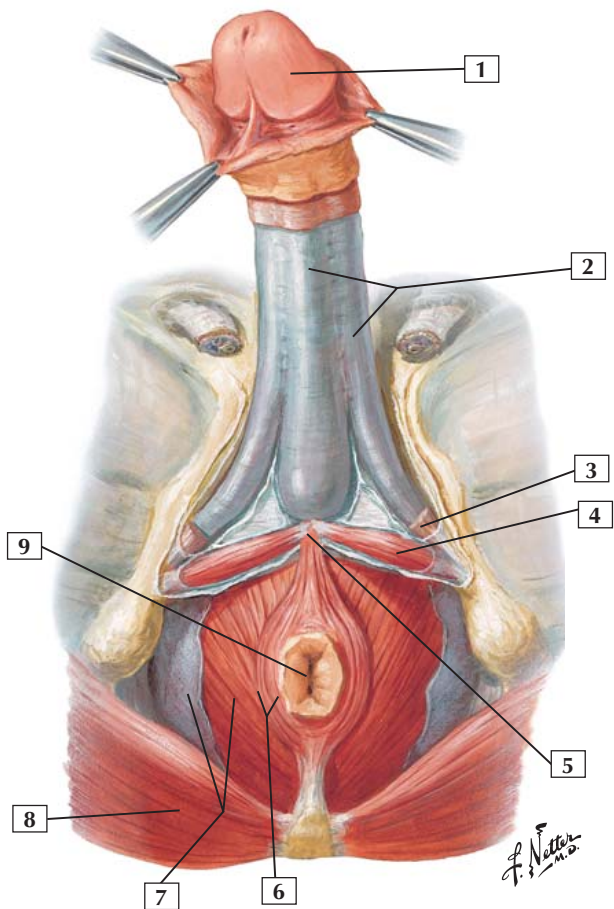


1. Ductus deferens (in peritoneal fold)
2. Deep inguinal ring
3. Testicular vessels (in peritoneal fold)
4. Descending colon
5. Ureter
6. Cecum
7. Rectovesical pouch
8. Urinary bladder
9. Rectum

Comment: The male peritoneum passes from the anterior abdominal wall over the superior surface of the urinary bladder and inferiorly on the posterior surface of the bladder. It also passes over the superior ends of the seminal vesicles, and it posteriorly lines the rectovesical pouch, the space between the rectum and urinary bladder. It then reflects onto the superior part of the rectum. Posteriorly and superiorly, it becomes the sigmoid mesocolon.

The testicular vessels and lymphatics lie in a retroperitoneal position and course to and from the deep inguinal ring. At the ring, notice the retroperitoneal pathway of the ductus deferens as it courses toward the seminal vesicle.

Clinical: Note the retroperitoneal course of the ureters as they pass to the urinary bladder. They course beneath the testicular vessels but over the iliac vessels. They then pass deep to the ductus deferens as they approach the bladder. Surgeons operating in the pelvic cavity must be aware of the retroperitoneal course of the ureters because they can be easily damaged, leading to the extravasation of urine into adjacent retroperitoneal and intraperitoneal spaces.



1. Glans penis
2. Deep (Buck's) fascia of penis
3. Ischiocavernosus muscle (cut away)
4. Superficial transverse perineal muscle
5. Perineal body
6. External anal sphincter muscle
7. Levator ani muscle and inferior fascia of pelvic diaphragm roofing ischioanal fossa
8. Gluteus maximus muscle
9. Anus

Comment: The male perineum includes the anal canal, the membranous and spongy parts of the urethra, the root of the penis, and the scrotum (not shown). The root, or attached part of the penis, consists of 2 crura and a bulb, which lies centrally, and the ischiocavernosus and bulbospongiosus muscles, which cover those erectile bodies. The crura are attached to the internal surface of the ischial ramus.

After descending from the bladder and passing through the prostate, the urethra enters the proximal portion of the bulb of the penis. It passes through the corpus spongiosum as the spongy urethra.

The levator ani muscle, a portion of the pelvic diaphragm, is visible in the anal triangle.

Clinical: Male circumcision, performed for religious and/or hygienic reasons, involves the removal of the prepuce or foreskin of the penis, leaving the glans exposed.

Bones and Joints

- 6-1** Humerus and Scapula: Anterior View
- 6-2** Humerus and Scapula: Posterior View
- 6-3** Shoulder (Glenohumeral) Joint: Anterior View
- 6-4** Shoulder (Glenohumeral) Joint: Lateral View
- 6-5** Bones of Elbow: In Extension
- 6-6** Bones of Elbow: In 90° Flexion
- 6-7** Ligaments of Elbow
- 6-8** Bones of Forearm
- 6-9** Bones of Wrist and Hand
- 6-10** Ligaments of Wrist: Palmar View
- 6-11** Ligaments of Wrist: Posterior View
- 6-12** Metacarpophalangeal and Interphalangeal Ligaments: Medial Views
- 6-13** Metacarpophalangeal and Interphalangeal Ligaments: Anterior View

Muscles

- 6-14** Trapezius
- 6-15** Latissimus Dorsi
- 6-16** Levator Scapulae
- 6-17** Deltoid
- 6-18** Supraspinatus Muscle and Infraspinatus Muscle
- 6-19** Teres Minor and Teres Major



- 6-20** Subscapularis
- 6-21** Pectoralis Major
- 6-22** Biceps Brachii
- 6-23** Coracobrachialis
- 6-24** Brachialis
- 6-25** Triceps Brachii and Anconeus
- 6-26** Arm: Serial Cross Section
- 6-27** Pronator Teres and Pronator Quadratus
- 6-28** Flexor Carpi Radialis
- 6-29** Palmaris Longus
- 6-30** Flexor Carpi Ulnaris
- 6-31** Flexor Digitorum Superficialis
- 6-32** Flexor Digitorum Profundus
- 6-33** Flexor Pollicis Longus
- 6-34** Supinator
- 6-35** Brachioradialis
- 6-36** Extensor Carpi Radialis Longus
- 6-37** Extensor Carpi Radialis Brevis
- 6-38** Extensor Digitorum
- 6-39** Extensor Digiti Minimi
- 6-40** Extensor Carpi Ulnaris
- 6-41** Abductor Pollicis Longus
- 6-42** Extensor Pollicis Brevis
- 6-43** Extensor Pollicis Longus

- 6-44** Extensor Indicis
- 6-45** Muscles in Cross Section of Forearm
- 6-46** Abductor Pollicis Brevis
- 6-47** Flexor Pollicis Brevis
- 6-48** Opponens Pollicis
- 6-49** Adductor Pollicis
- 6-50** Abductor Digiti Minimi
- 6-51** Flexor Digiti Minimi Brevis
- 6-52** Opponens Digiti Minimi
- 6-53** Lumbrical Muscles
- 6-54** Dorsal Interosseous Muscles
- 6-55** Palmar Interosseous Muscles
- 6-56** Cross Section of Palm

Nerves

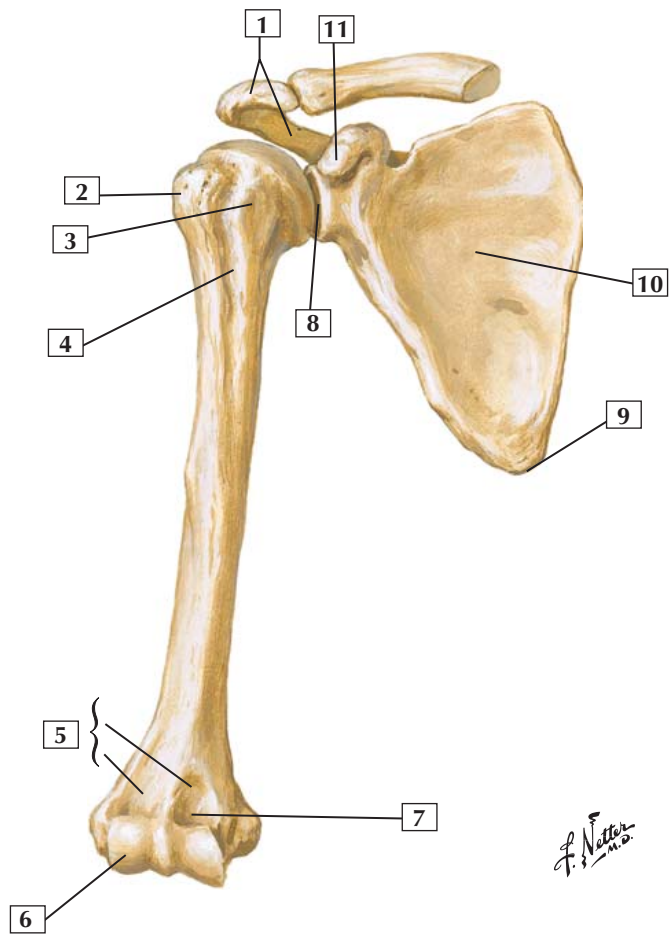
- 6-57** Brachial Plexus: Schema
- 6-58** Radial Nerve in Arm and Nerves of Posterior Shoulder
- 6-59** Nerves of Upper Limb
- 6-60** Nerves of Hand

Vessels

- 6-61** Cutaneous Nerves and Superficial Veins of Shoulder and Arm



- 6-62** Cutaneous Nerves and Superficial Veins of Forearm
- 6-63** Arteries Around Scapula
- 6-64** Brachial Artery and Anastomoses
- 6-65** Arteries of Hand: Palmar View



F. Netter M.D.

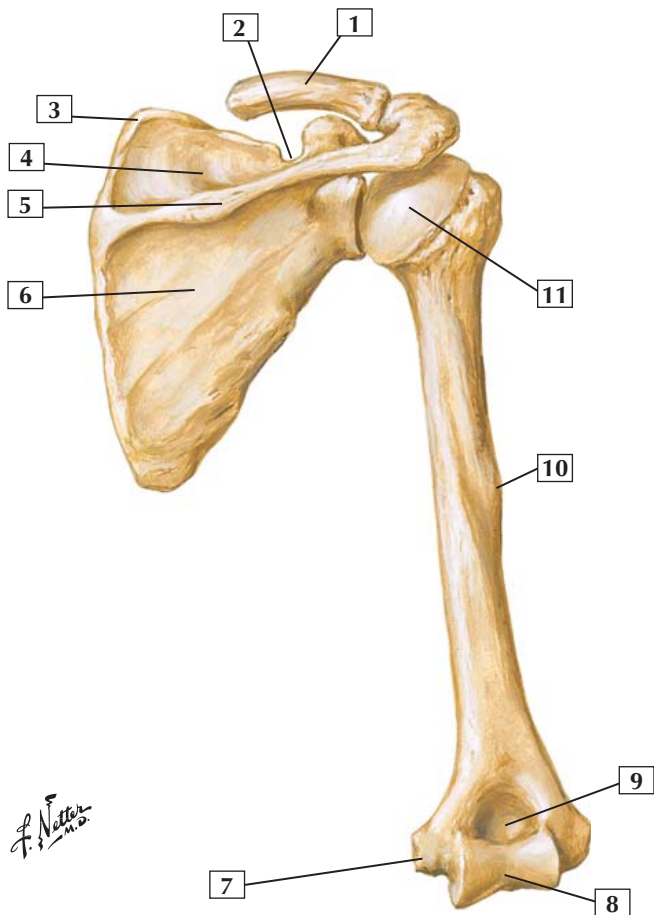
1. Acromion
2. Greater tubercle
3. Lesser tubercle
4. Intertubercular sulcus
5. Condyles (Medial; Lateral)
6. Capitulum
7. Coronoid fossa
8. Glenoid cavity of scapula
9. Inferior angle
10. Subscapular fossa
11. Coracoid process

Comment: The clavicle and scapula form the pectoral girdle, or shoulder, which connects the upper extremity to the trunk. The clavicle serves as a strut, keeping the upper limb away from the trunk and free for movement. It is vulnerable to fracture.

The scapula, or shoulder blade, articulates with the clavicle and the head of the humerus (glenohumeral joint). Seventeen different muscles attach to the scapula. Fractures of the scapula are uncommon.

The humerus is a long bone. Its proximal end forms part of the shoulder joint, and its distal end contributes to the elbow joint. The surgical neck of the humerus (the region just below the lesser tubercle) is a common fracture site. Fractures at this site may injure the axillary nerve of the brachial plexus.

Clinical: Fractures of the clavicle are common, especially in children. The fracture usually results from a fall on an outstretched hand or from direct trauma and commonly occurs in the middle third of the clavicle.



F. Netter M.D.

1. Clavicle (cut)
2. Suprascapular notch
3. Superior angle
4. Supraspinous fossa
5. Spine
6. Infraspinous fossa
7. Medial epicondyle
8. Trochlea
9. Olecranon fossa
10. Deltoid tuberosity
11. Head of humerus

Comment: Posteriorly, the scapula displays a prominent spine that separates the supraspinous and infraspinous fossae.

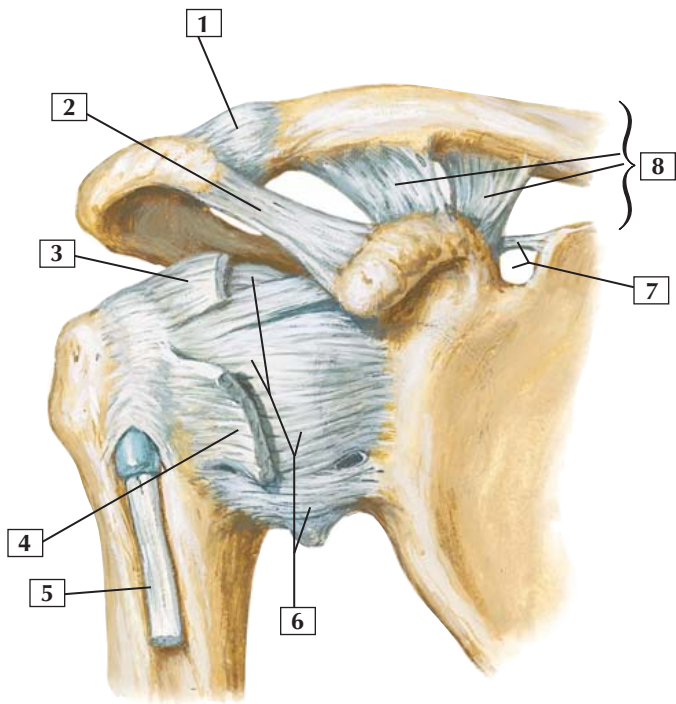
The clavicle is the first bone to ossify but the last bone to fuse and is formed by intramembranous ossification. It is one of the most commonly fractured bones.

Midshaft on the humerus is the deltoid tuberosity, the insertion point for the deltoid muscle.

Distally, the depression above the trochlea is called the olecranon fossa, which accommodates the olecranon of the ulna when the elbow is extended fully.

Clinical: Fractures of the scapula are relatively uncommon. Fractures of the surgical neck of the humerus are common and may injure the axillary nerve from the brachial plexus. A midshaft fracture of the humerus may injure the radial nerve.

Anterior view



*F. Netter
M.D.*

Shoulder (Glenohumeral) Joint: Anterior View

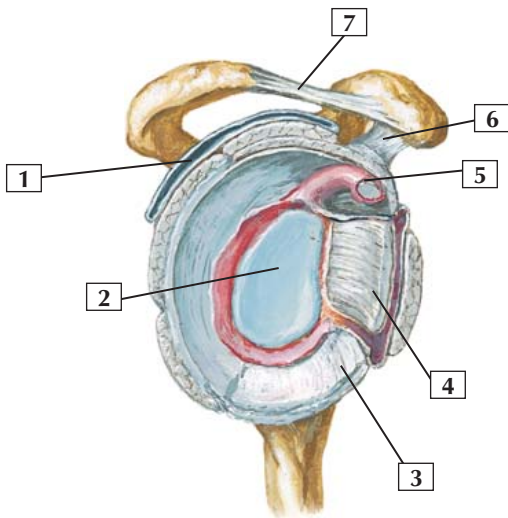
1. Acromioclavicular joint capsule (incorporating acromioclavicular ligament)
2. Coracoacromial ligament
3. Supraspinatus tendon (cut)
4. Subscapularis tendon (cut)
5. Biceps brachii tendon (long head)
6. Capsular ligaments
7. Superior transverse scapular ligament and suprascapular notch
8. Coracoclavicular ligament (Trapezoid ligament; Conoid ligament)

Comment: The shoulder is a multiaxial synovial ball-and-socket (spheroidal) joint. Movements include abduction and adduction, flexion and extension, and rotation and circumduction. The shallow glenoid cavity of the scapula permits extensive movement at the shoulder but also makes this joint vulnerable to dislocation. The 4 tendons of the rotator cuff muscles help stabilize the joint.

Also shown is the acromioclavicular joint, a synovial plane joint between the acromion and clavicle. This joint permits gliding movement as the arm is raised and the scapula rotates.

Clinical: Because of the wide range of motion at the shoulder and its rather shallow glenoid cavity, this joint is the most dislocated joint in the body. This glenohumeral joint usually dislocates in an anterior direction (subcoracoid dislocation) and can place the axillary and musculocutaneous nerves of the brachial plexus at risk for injury.

Joint opened: lateral view



*F. Netter
M.D.*

Shoulder (Glenohumeral) Joint: Lateral View

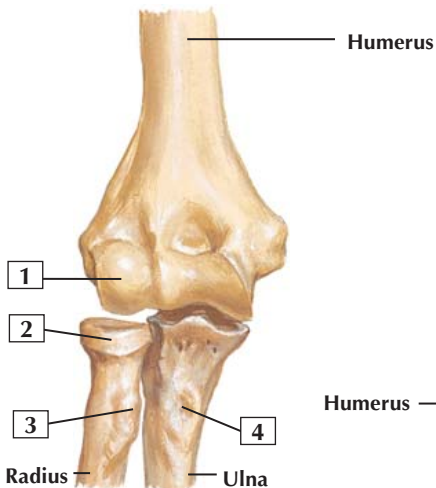
1. Subdeltoid bursa
2. Glenoid cavity (cartilage)
3. Inferior glenohumeral ligament
4. Middle glenohumeral ligament
5. Biceps brachii tendon (long head)
6. Coracohumeral ligament
7. Coracoacromial ligament

Comment: The glenoid cavity is deepened by the presence of the glenoid labrum (lip). The joint is stabilized by a capsule, ligaments, and the 4 tendons of the rotator cuff muscles. The 4 tendons of the rotator cuff muscles reinforce the joint posteriorly, superiorly, and midanteriorly (subscapularis tendon). Most shoulder dislocations occur anteriorly, where there is less support.

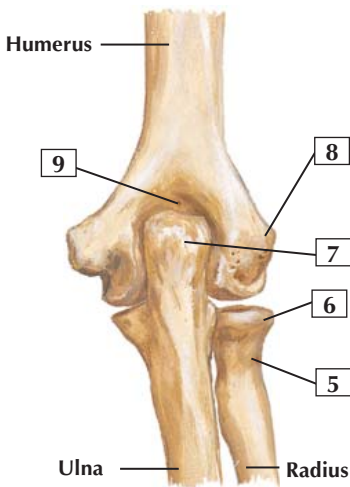
Blood is supplied to the shoulder by branches of the suprascapular, humeral circumflex, and scapular circumflex arteries.

Clinical: Bursa are synovial-lined, fluid-filled enclosed cushions that protect tendons and ligaments from injury related to frictional movement over adjacent bony projections or other rough surfaces.

Right elbow



In extension: anterior view



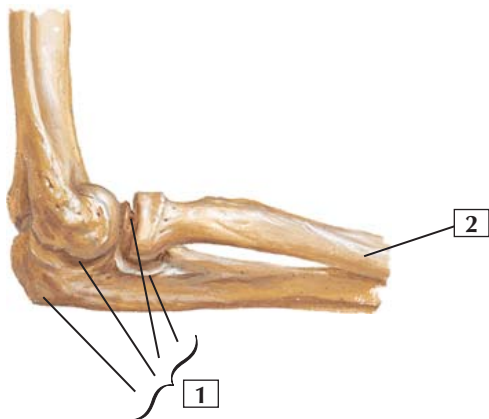
In extension: posterior view

F. Netter M.D.

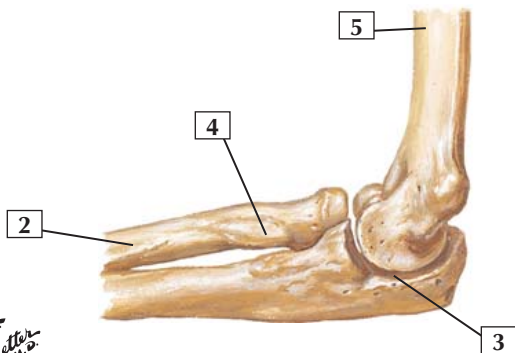
1. Capitulum
2. Head
3. Tuberosity
4. Tuberosity
5. Neck
6. Head
7. Olecranon
8. Lateral epicondyle
9. Olecranon fossa

Comment: The elbow bones include the humerus and the 2 bones of the forearm: the radius and ulna. The ulna lies more medially in the forearm and is the longer of the 2 bones. The point of the elbow that can be easily felt is the olecranon, located posteriorly and proximally on the ulna.

Clinical: Dislocations of the elbow joint are 3rd in frequency after shoulder and finger dislocations and usually result from a fall on an outstretched hand. Posterior dislocations are the most common type.



In 90° flexion: lateral view



In 90° flexion: medial view

F. Netter M.D.

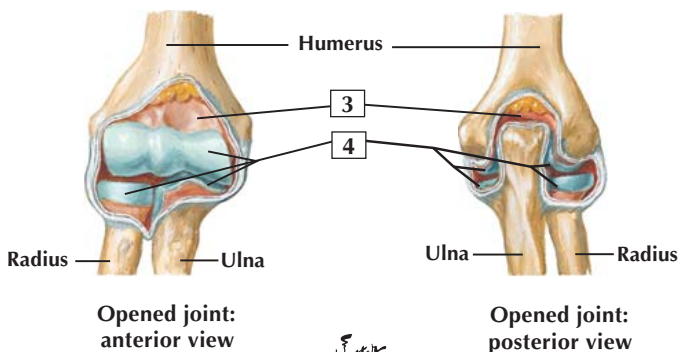
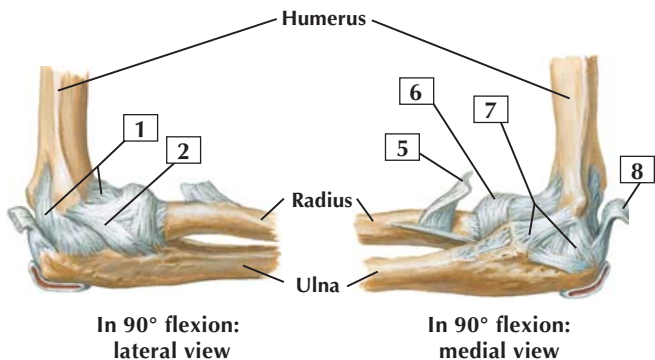
1. Ulna (Radial notch; Coronoid process; Trochlear notch; Olecranon)
2. Radius
3. Trochlear notch
4. Tuberosity
5. Humerus

Comment: The bones of the elbow include the humerus and the 2 bones of the forearm: the radius and ulna. The ulna lies more medially in the forearm and is the longer of the 2 bones. The point of the elbow that can be easily felt is the olecranon, located posteriorly and proximally on the ulna.

Clinical: Dislocations of the elbow may be accompanied by fractures of the humeral epicondyle, olecranon (ulna), radial head, or coronoid process of the ulna. The median or ulnar nerves of the brachial plexus, or both, may be injured in elbow dislocations or fractures.

Fractures of the proximal radius usually involve the head or neck of the radius.

Ulnar fractures often occur from a direct blow or forced pronation of the forearm and involve the shaft.



F. Netter M.D.

1. Joint capsule
2. Radial collateral ligament
3. Synovial membrane
4. Articular cartilage
5. Biceps brachii tendon
6. Anular ligament of radius
7. Ulnar collateral ligament
8. Triceps brachii tendon

Comment: The elbow joint forms a uniaxial synovial hinge (ginglymus) joint that includes the humeroradial joint (between the capitulum of the humerus and the head of the radius) and the humeroulnar joint (between the trochlea of the humerus and the trochlear notch of the ulna). The joint also includes a proximal uniaxial radioulnar synovial (pivot) joint that participates in supination and pronation (rotation). Movements about the elbow include flexion and extension.

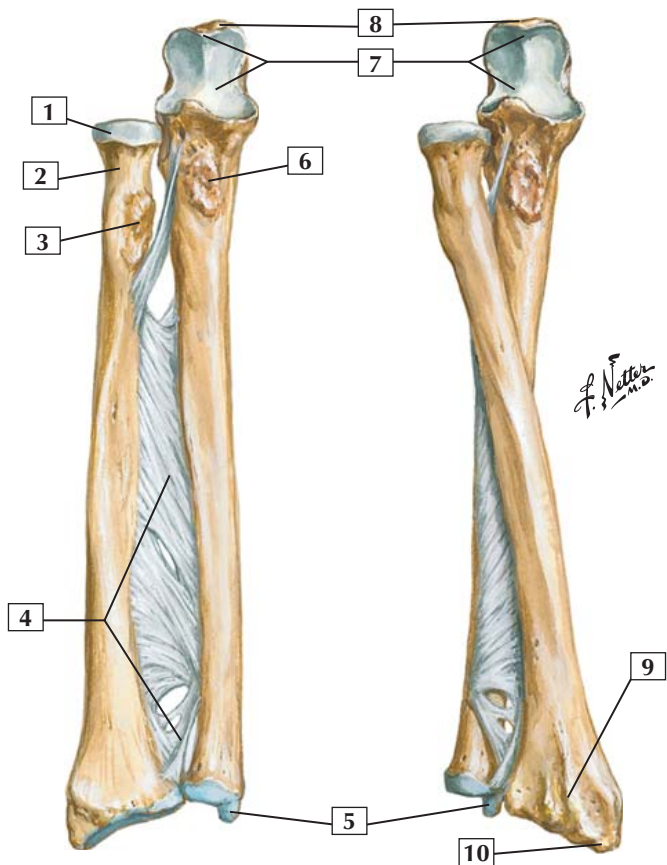
The joint is stabilized by the laterally placed radial collateral ligament and medially placed triangular ulnar collateral ligament. The anular ligament holds the head of the radius in place.

Blood is supplied to the elbow by branches of the brachial artery and recurrent collateral branches of the radial and ulnar arteries.

Clinical: A strong pull on the forearm, especially in children, can pull the head of the radius out of the anular ligament, resulting in a dislocation of the proximal radioulnar joint.

Right radius and ulna
in supination: anterior view

Right radius and ulna in
pronation: anterior view



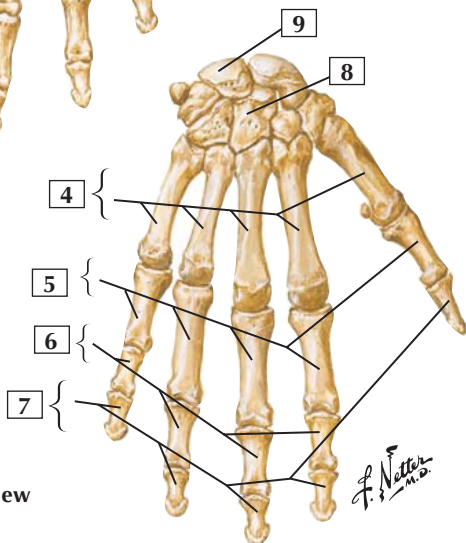
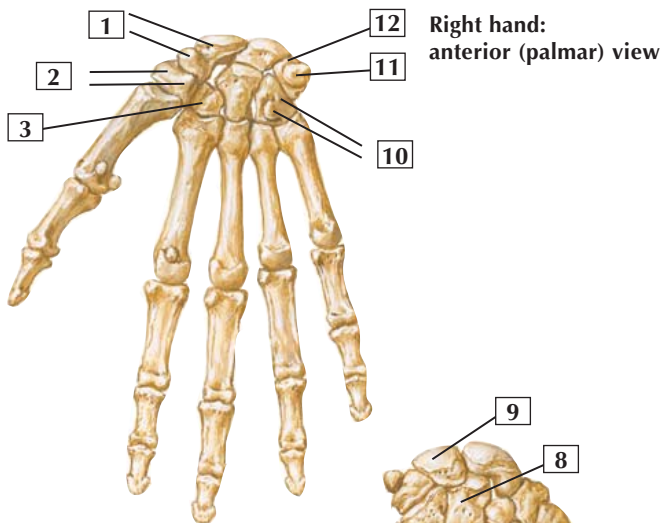
1. Head
2. Neck
3. Radial tuberosity
4. Interosseous membrane
5. Styloid process of ulna
6. Ulnar tuberosity
7. Trochlear notch
8. Olecranon
9. Dorsal tubercle
10. Styloid process

Comment: The bones of the forearm include the medially placed and longer ulna and the laterally placed radius.

Along the length of the forearm, the radius and ulna are connected by the interosseous membrane, which contributes to the radioulnar joint, a fibrous (syndesmosis) joint. The interosseous membrane divides the forearm into anterior and posterior muscular compartments.

Distally, the radius and the ulna display styloid processes.

Clinical: A Colles' fracture is a fracture of the distal radius, commonly occurring from a fall on an outstretched hand. In such fractures, the distal fragment of the radius is forced proximally and dorsally, resulting in a "dinner fork" deformity.

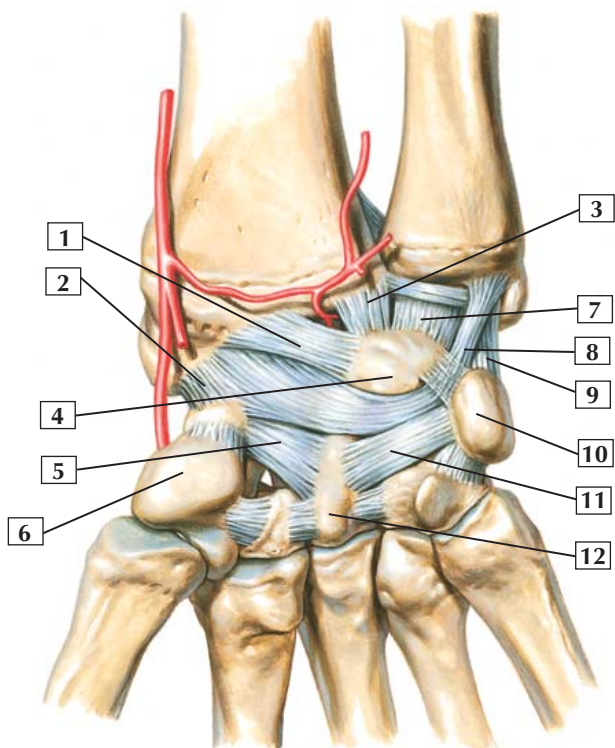


1. Scaphoid and Tubercle
2. Trapezium and Tubercle
3. Trapezoid
4. Metacarpal bones
5. Proximal phalanges
6. Middle phalanges
7. Distal phalanges
8. Capitate
9. Lunate
10. Hamate and Hook
11. Pisiform
12. Triquetrum

Comment: Bones of the wrist and hand include the 8 carpal bones; 5 metacarpal bones (1 for each digit); and, for digits 2 through 5, proximal, middle, and distal phalanges. The 1st digit, or thumb, has only a proximal phalanx and a distal phalanx.

The scaphoid, lunate, and triquetrum articulate with the distal radius to form the radiocarpal wrist joint.

Clinical: The scaphoid is the most commonly fractured carpal. The scaphoid lies just below the “anatomic snuffbox” (dorsal region at the base of the thumb), so pain and swelling is common over this area. The 5th metacarpal is the most commonly fractured metacarpal, and the distal phalanx of the middle finger is the most commonly fractured digit of the hand.



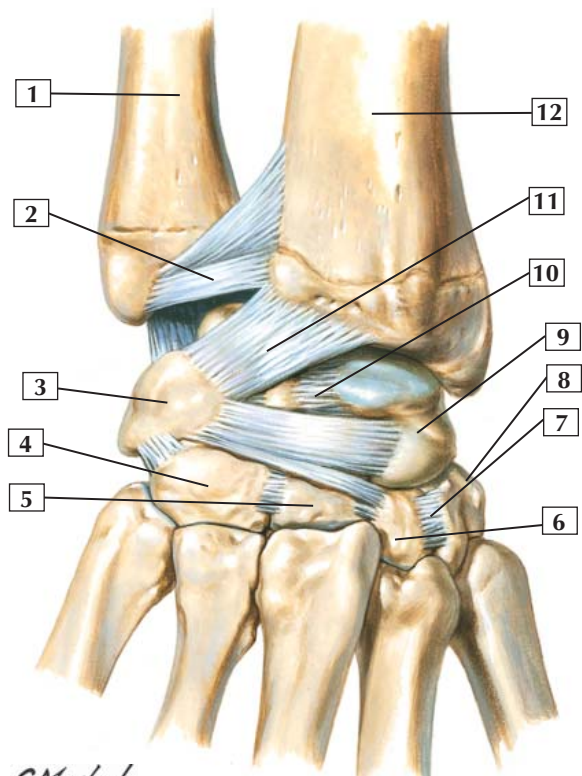
C. Machado
M.D.

1. Long radiolunate ligament
2. Radioscaphocapitate ligament
3. Short radiolunate ligament
4. Lunate
5. Scaphocapitate ligament
6. Trapezium
7. Ulnolunate ligament
8. Ulnocapitate ligament
9. Ulnotriquetral ligament
10. Pisiform
11. Triquetrocapitate ligament
12. Capitate

Comment: The wrist, or radiocarpal joint, is an ellipsoid biaxial synovial joint formed by the distal end of the radius (an articular disc) and the scaphoid, lunate, and triquetrum carpal bones. This joint is reinforced by radial and ulnar collateral ligaments and by dorsal and palmar (volar) radiocarpal ligaments. The joint permits flexion, extension, abduction, adduction, and circumduction.

Anatomists often simply lump these ligaments into a palmar radiocarpal ligament (long and short radiolunate and radioscaphocapitate ligaments: 1-3 in the list above), a palmar ulnocarpal ligament (ulnolunate, ulnocapitate and ulnotriquetral ligaments), and various intercarpal and metacarpal ligaments. However, hand surgeons classify these ligaments more precisely based on their attachments.

The carpometacarpal joint of the thumb is a biaxial saddle (sellar) joint (with trapezium). It provides flexion and extension, abduction and adduction, and circumduction. The other 4 carpometacarpal joints are plane synovial joints that permit gliding movements.



C. Machado
—M.D.—

1. Ulna
2. Dorsal radioulnar ligament
3. Triquetrum
4. Hamate
5. Capitate
6. Trapezoid
7. Trapeziotrapezoid ligament
8. Trapezium
9. Scaphoid
10. Scapholunate ligament
11. Dorsal radiocarpal ligament
12. Radius

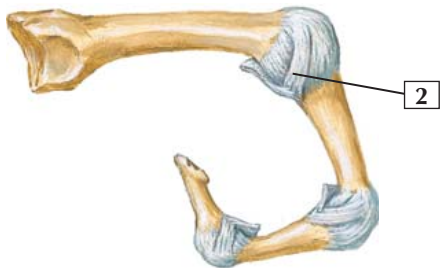
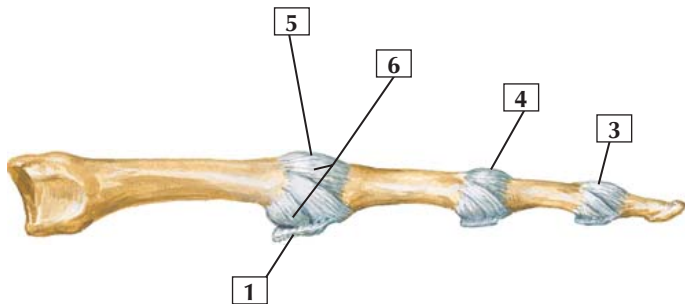
Comment: Proximal to the wrist lies the distal radioulnar joint, which is a uniaxial synovial pivot (trochoid) joint between the ulna and the ulnar notch of the radius. It allows for pronation and supination (rotation).

The wrist, or radiocarpal joint, is an ellipsoidal biaxial synovial joint formed by the distal end of the radius (an articular disc) and the scaphoid, lunate, and triquetrum carpal bones. Movements at the wrist include flexion, extension, abduction, adduction, and circumduction.

Anatomists often simplify these ligaments into a dorsal radiocarpal ligament, dorsal carpometacarpal ligaments, and intercarpal ligaments. However, hand surgeons classify these ligaments more precisely based on their attachments.

Between the proximal and distal rows of carpal bones lies the midcarpal (intercarpal) joints, synovial plane joints. These joints permit some gliding and sliding movements.

In extension:
medial view



In flexion:
medial view

*F. Netter
M.D.*

WWW.YAZDANPRESS.COM

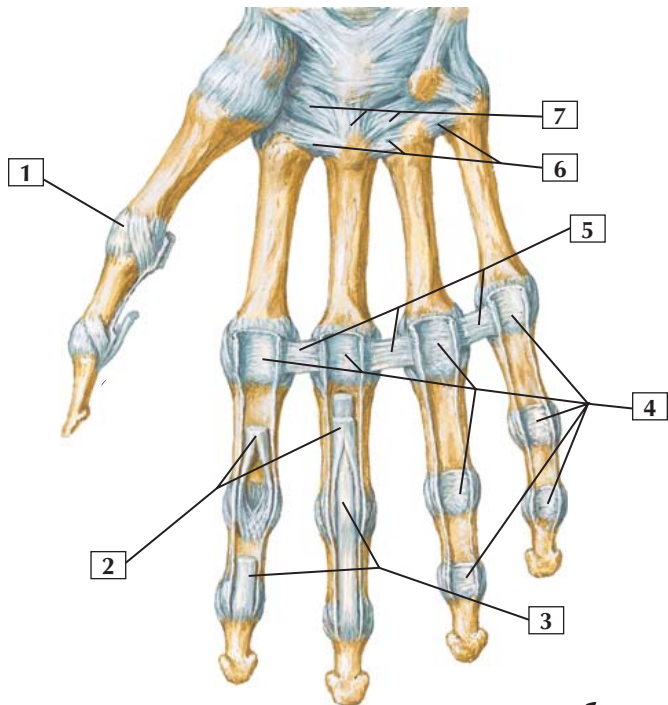
Metacarpophalangeal and Interphalangeal Ligaments: Medial Views

1. Palmar ligament (plate)
2. Collateral ligament
3. Distal interphalangeal joint
4. Proximal interphalangeal joint
5. Metacarpophalangeal joint
6. Joint capsule

Comment: The metacarpophalangeal joints are biaxial condyloid synovial joints that participate in flexion and extension, abduction and adduction, and circumduction. The capsule is supported by the collateral and palmar (volar) ligaments. The collateral ligaments are tight in flexion and loose in extension.

The interphalangeal joints (proximal interphalangeal and distal interphalangeal) are uniaxial synovial hinge joints that participate in flexion and extension. Ligaments similar to the metacarpophalangeal joints reinforce these joints. The palmar ligaments prevent hyperextension.

Clinical: Dorsal dislocation of the proximal interphalangeal joint is fairly common. Palmar and rotational dislocations are uncommon but can occur. Distal dislocations or fractures of the distal interphalangeal joint may occur from a direct blow to the fingertip (mallet finger), such as from a baseball or volleyball, often resulting in extensor tendon damage.



*F. Netter
M.D.*

WWW.YAZDANPRESS.COM

Metacarpophalangeal and Interphalangeal Ligaments: Anterior View

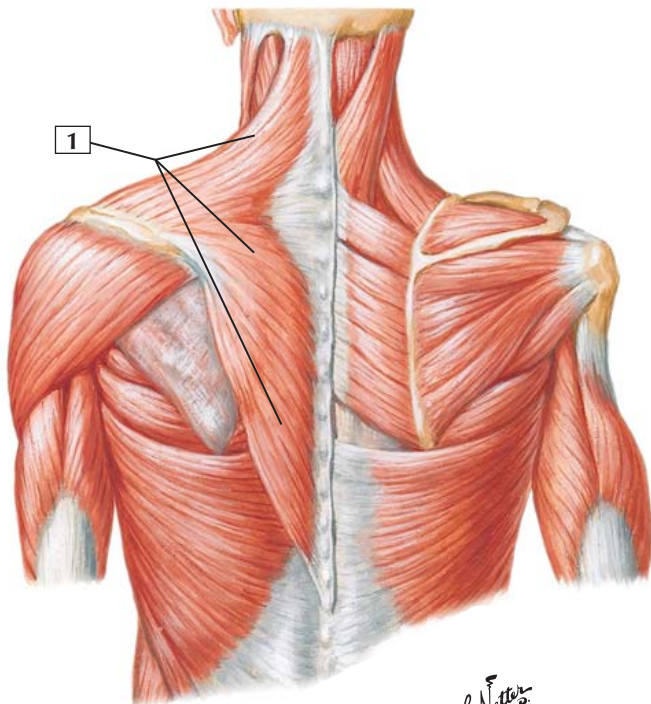
1. Joint capsule
2. Flexor digitorum superficialis tendons (cut)
3. Flexor digitorum profundus tendons
4. Palmar ligaments (plates)
5. Deep transverse metacarpal ligaments
6. Palmar metacarpal ligaments
7. Palmar carpometacarpal ligaments

Comment: The metacarpophalangeal joints are biaxial condyloid synovial joints that participate in flexion and extension, abduction and adduction, and circumduction. These joints are reinforced by the palmar (volar) ligaments and 2 collateral ligaments on either side.

The interphalangeal joints for digits 2 through 5 include a proximal interphalangeal joint and a distal interphalangeal joint. These joints are uniaxial synovial hinge joints that are reinforced by palmar ligaments and 2 collateral ligaments. They permit flexion and extension. The palmar ligaments prevent hyperextension.

Clinical: Fractures of the metacarpals can occur from direct blows (boxer fractures) and can not only disrupt the bones and ligaments but also affect the pull of the muscle tendons that attach to the metacarpals. These fractures need to be carefully set so that optimal finger function can be achieved after injury and physical therapy.

Posterior view



1. Trapezius

Origin (proximal): External occipital protuberance and medial third of the superior nuchal line of occipital bone, ligamentum nuchae, spinous processes of the 7th cervical vertebra and all 12 thoracic vertebrae.

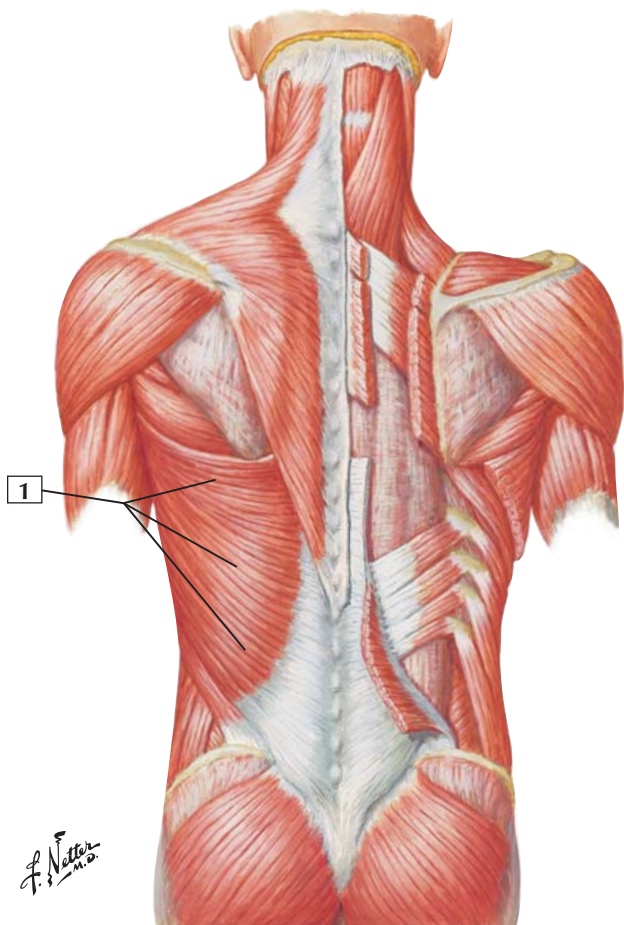
Insertion (distal): Superior fibers insert into the posterior border of the lateral third of the clavicle. Middle fibers insert into the medial margin of the acromion and posterior border of the scapular spine. Inferior fibers converge to end in an aponeurosis inserted into the scapular spine.

Action: The upper and lower fibers act primarily to rotate the scapula for full abduction of the upper extremity. The upper fibers, acting alone, elevate the shoulder and brace the shoulder girdle when a weight is being carried by the shoulder or hand. Central fibers run horizontally and retract the shoulder. Lower fibers draw the scapula downward. When both muscles act together, the scapula can be adducted and the head drawn directly backward.

Innervation: Motor supply is from the spinal accessory nerve (CN XI). Proprioceptive fibers are from the 3rd and 4th cervical nerves.

Comment: The trapezius, in contrast to the other shoulder muscles, does not receive nerve fibers from the brachial plexus.

Clinical: The trapezius can be tested by having a patient elevate the shoulder against resistance (the upper portion of the contracting muscle can be felt). This tests the integrity of the spinal accessory nerve (CN XI) innervating this muscle.



1. Latissimus dorsi

Origin (proximal): Arises from a broad aponeurosis of the posterior layer of the thoracolumbar fascia, the spinous processes of the lower 6 thoracic vertebrae, and fleshy digitations of the caudal-most 3 or 4 ribs. The muscle also may attach to the iliac crest.

Insertion (distal): The fibers converge as the muscle curves around the lower border of the teres major and twists on itself. They end as a tendon that inserts into the intertubercular groove of the humerus.

Action: Extends, adducts, and medially rotates the humerus (arm).

Innervation: Thoracodorsal nerve (C6-8).

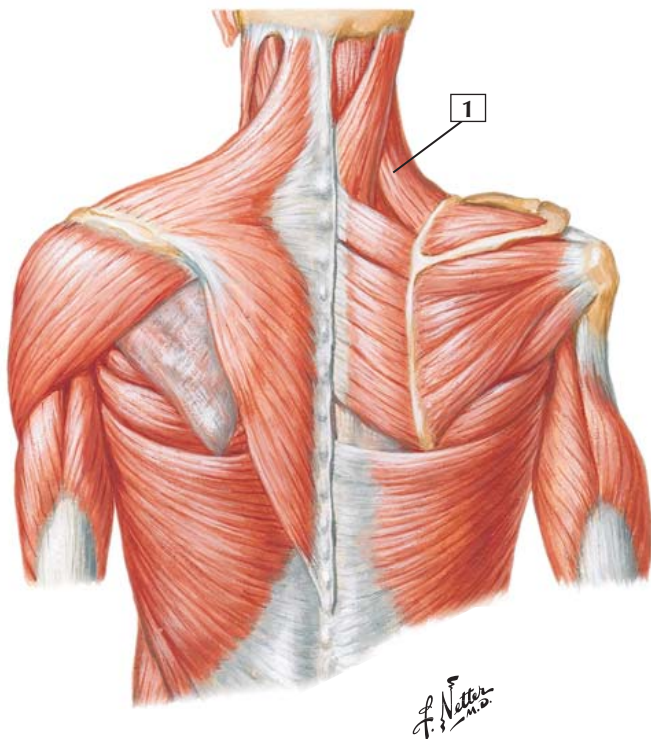
Comment: With the upper extremity fixed, the latissimus dorsi elevates the trunk when the arms are stretched above the head, as in climbing.

The origin of the muscle from the thoracic vertebrae and lower ribs may vary.

The blood supply is by the thoracodorsal artery, a branch of the subscapular artery (which arises from the axillary artery).

Clinical: The latissimus dorsi is tested clinically by having the patient raise the arm horizontal to the body with the elbow flexed, as if signaling someone to “stop.” Then the patient is asked to adduct the arm against resistance to test the muscle’s strength and the integrity of the thoracodorsal nerve. The muscle can also be felt to contract over the patient’s back when the patient is asked to cough.

Posterior view



1. Levator scapulae

Origin (proximal): Arises from the transverse processes of the first 4 cervical vertebrae.

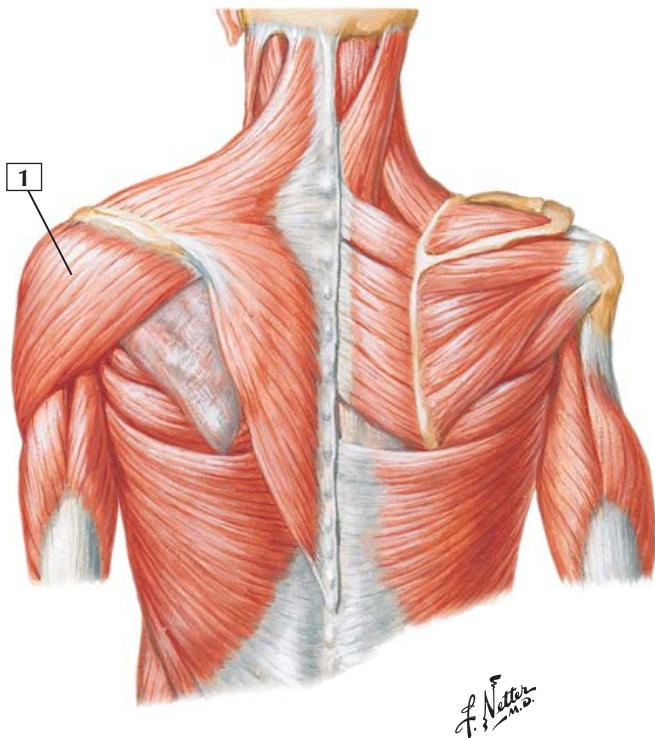
Insertion (distal): Inserts into the superior portion of the medial (vertebral) border of the scapula.

Action: Elevates the superior angle of the scapula and tends to draw it medially. Also rotates the scapula so that the glenoid cavity is tilted inferiorly. When the scapula is held in a fixed position, the levator scapulae bends the neck laterally and rotates it slightly toward the same side.

Innervation: By the 3rd and 4th cervical nerves from the cervical plexus and by a branch from the dorsal scapular nerve (C5) to the muscle's lower fibers.

Comment: Contraction of the levator scapulae helps shrug the shoulders. The blood supply to the muscle comes largely from the transverse cervical artery of the thyrocervical trunk.

Posterior view



1. Deltoid

Origin (proximal): Arises from the lateral third of the clavicle, the superior surface of the acromion, and the spine of the scapula.

Insertion (distal): The fibers converge in a thick tendon that is attached to the deltoid tuberosity on the lateral aspect of the shaft of the humerus.

Action: The principal function is abduction of the arm at the shoulder in a movement initiated together with the supraspinatus muscle. The clavicular portion of the muscle rotates the arm medially and helps the pectoralis major flex the arm at the shoulder. The spinous portion rotates the arm laterally and helps the latissimus dorsi extend the arm at the shoulder.

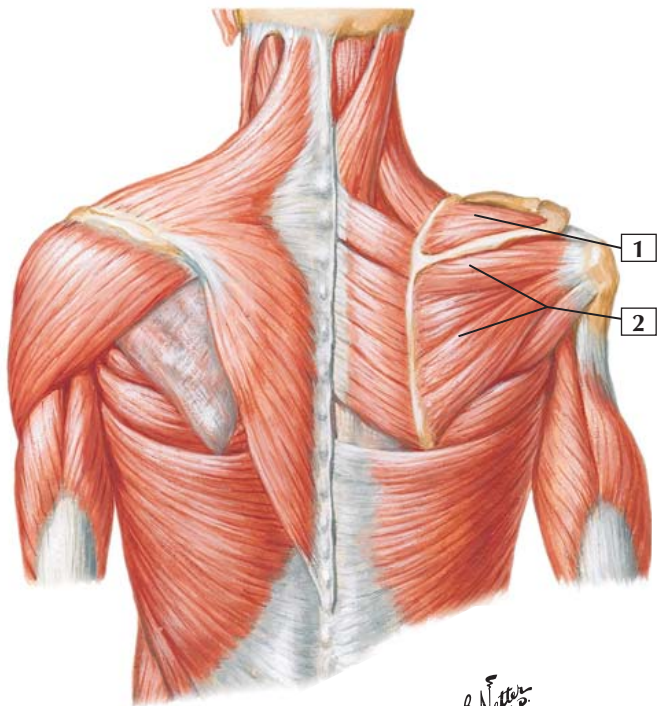
Innervation: Axillary nerve (C5 and C6).

Comment: The deltoid is a thick, triangular muscle with coarse fibers. It covers the shoulder joint anteriorly, posteriorly, and laterally. The multipennate central portion of the muscle is most active in abduction.

The blood supply is largely via the thoracoacromial artery and also via the anterior and posterior humeral circumflex arteries, which arise from the axillary artery.

Clinical: To test the deltoid muscle strength and the integrity of the axillary nerve, have the patient abduct the upper limb against resistance (the middle fibers of the muscle should be seen to contract). The posterior fibers can be seen to contract if the patient tries to retract the abducted upper limb against resistance.

Posterior view



WWW.YAZDANPRESS.COM

Supraspinatus Muscle and Infraspinatus Muscle

1. Supraspinatus muscle
2. Infraspinatus muscle

Origin (proximal): The supraspinatus muscle occupies the supraspinous fossa, originating from the medial two-thirds and arising from the strong, supraspinatus fascia. The infraspinatus occupies most of the infraspinous fossa; it arises from the medial two-thirds and from the infraspinatus fascia.

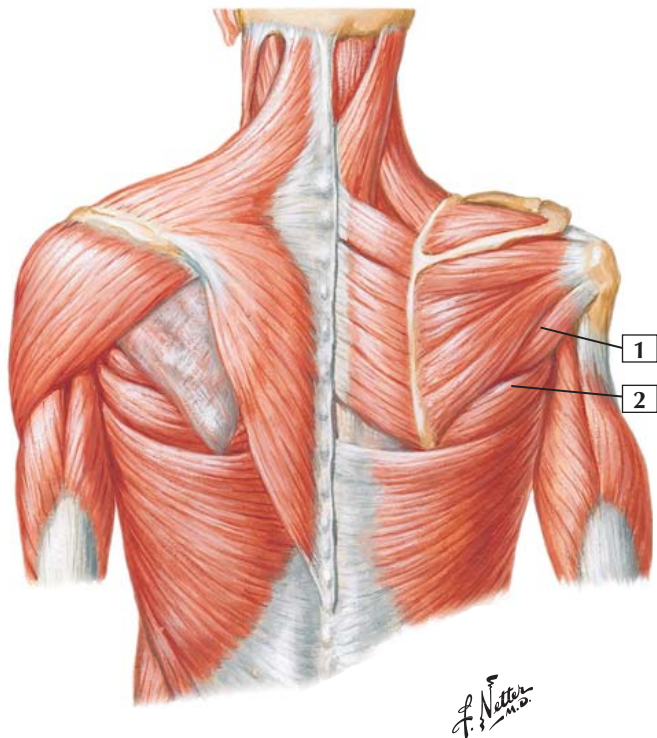
Insertion (distal): Fibers of the supraspinatus converge to form a tendon that inserts into the superior facet on the greater tubercle of the humerus. The infraspinatus fibers also converge to form a tendon, which inserts into the middle facet on the greater tubercle of the humerus. The tendons of the 2 muscles adhere to each other.

Action: The supraspinatus strengthens the shoulder joint by drawing the humerus toward the glenoid fossa. With help from the deltoid, it initiates abduction at the shoulder and is a lateral rotator of the humerus (arm). The infraspinatus strengthens the shoulder joint by bracing the head of the humerus in the glenoid fossa. It is also a lateral rotator of the humerus.

Innervation: Both by the suprascapular nerve (C5 and C6).

Clinical: Repeated abduction and flexion of the shoulder (as in the throwing motion) may cause wear and tear on the tendons as they rub on the acromion and coracoacromial ligament. This action can lead to rotator cuff tears or rupture. The tendon of the supraspinatus is the most vulnerable to injury.

Posterior view



1. Teres minor
2. Teres major

Origin (proximal): The teres minor originates from the lateral border of the scapula. The teres major arises from the dorsal surface of the inferior angle of the scapula.

Insertion (distal): The teres minor inserts into the inferior facet on the greater tubercle of the humerus. The teres major inserts into the medial lip of the intertubercular groove of the humerus.

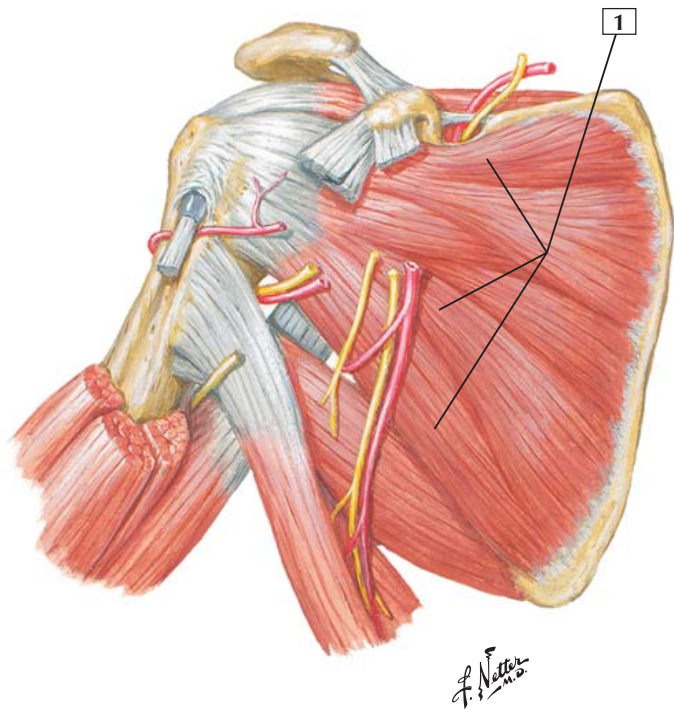
Action: The teres minor rotates the arm laterally and weakly adducts the arm at the shoulder. Similar to the other 3 rotator cuff muscles, it draws the humerus toward the glenoid fossa, strengthening the shoulder joint. The teres major helps extend the arm from the flexed position, and it adducts and medially rotates the arm at the shoulder.

Innervation: The teres minor is supplied by the axillary nerve (C5 and C6), whereas the teres major is innervated by the lower subscapular nerve (C6 and C7).

Comment: The teres minor is 1 of the 4 rotator cuff muscles, and it helps stabilize the shoulder joint. Often, it is inseparable from the infraspinatus muscle.

Clinical: The teres major is tested clinically by having the patient adduct the horizontally elevated arm against resistance while viewing the contraction of the muscle as it passes from the scapula to the humerus. The integrity of the subscapular nerve is also tested by this action.

Anterior view



1. Subscapularis

Origin (proximal): Arises from the medial two-thirds of the subscapular fossa and from the lower two-thirds of the lateral border of the scapula.

Insertion (distal): The fibers converge in a tendon that is inserted into the lesser tubercle of the humerus and the anterior portion of the shoulder joint capsule.

Action: As a rotator cuff muscle, the subscapularis helps stabilize the shoulder joint and prevents anterior displacement of the humerus. It also medially rotates and adducts the humerus (arm) at the shoulder.

Innervation: Upper and lower subscapular nerves (C5 and C6).

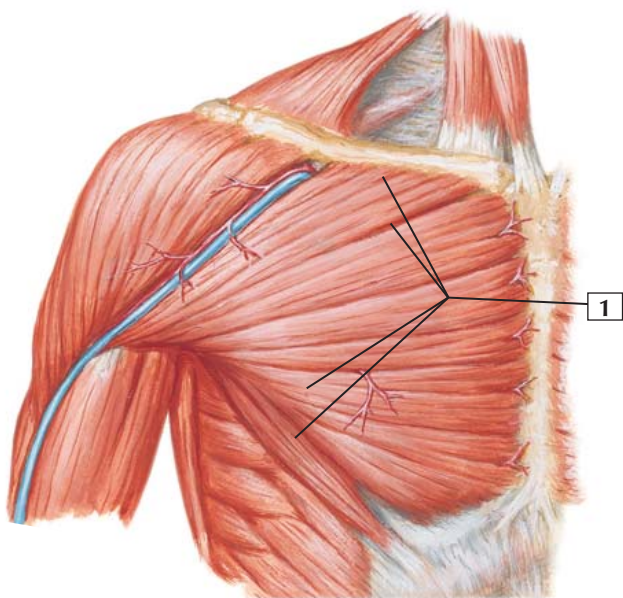
Comment: The tendon of the muscle is separated from the neck of the scapula by the subscapular bursa.

Along with the supraspinatus, infraspinatus, and teres minor muscles, the subscapularis is the 4th muscle of the rotator cuff group. Not all of these muscles actually rotate the head of the humerus in the shoulder joint, but they all help strengthen the joint.

The subscapularis and serratus anterior muscles together form a functional (physiologic) articulation of the shoulder called the scapulothoracic joint. The joint is between the muscles, the scapula, and the loose connective tissue trapped between these 2 muscles, which permits a gliding movement of the scapula on the chest wall. Scapular movements at this joint include elevation, depression, protraction, retraction, and rotation.

The blood supply to the muscle is by the subscapular artery, a branch of the axillary artery.

Anterior view



*F. Netter
M.D.*

1. Pectoralis major

Origin (proximal): Arises from the sternal half of the clavicle, the upper half of the sternum, and the aponeurosis of the external abdominal oblique muscle.

Insertion (distal): The fibers converge toward the anterior wall of the axilla. All 3 parts of the muscle (clavicular, sternal, and abdominal) end as a flat tendon inserted into the intertubercular groove of the humerus.

Action: The primary action is adduction of the arm at the shoulder. The pectoralis major is also a medial rotator of the humerus, and its clavicular portion helps flex the shoulder and adduct the humerus medially across the midline. The sternocostal portion, along with the latissimus dorsi and teres major muscles, can extend—against resistance—the flexed humerus to the side of the trunk.

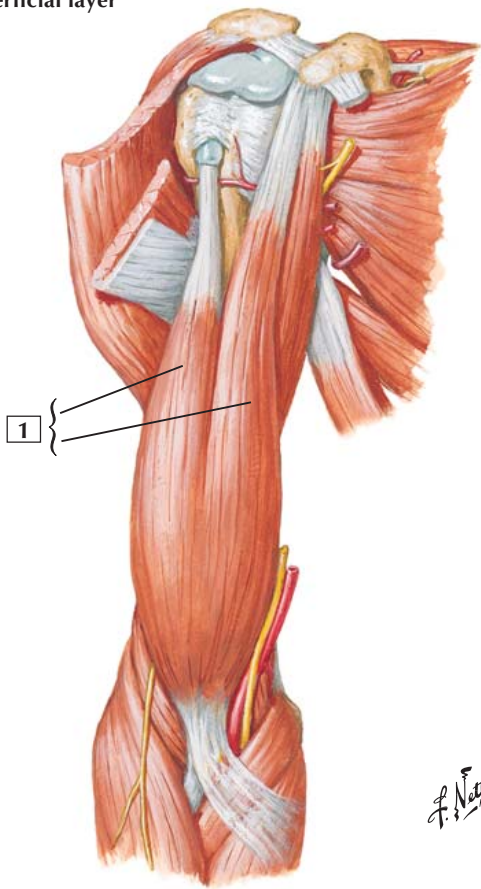
Innervation: Medial and lateral pectoral nerves (C5-8 and T1).

Comment: The converging fibers of this fan-shaped muscle course toward the insertion on the humerus, forming the anterior boundary of the axilla.

The thoracoacromial and lateral thoracic arteries supply the pectoralis major.

Clinical: The pectoralis major (sternocostal portion) is tested clinically by having the patient adduct (move toward the body) the arm from a position of 45 degrees lateral to the body wall with the elbow flexed. One can place a hand on the elbow and provide resistance against this adduction to test the muscle's strength and the integrity of the pectoral nerves.

Superficial layer



*F. Netter
M.D.*

1. Biceps brachii

Origin (proximal): The short head arises from the apex of the coracoid process of the scapula. The long head arises from the supraglenoid tubercle of the scapula.

Insertion (distal): Both muscle bellies join to form a flattened tendon that is inserted into the radial tuberosity. Opposite the elbow, the tendon gives off a broad aponeurosis from its medial side. This bicipital aponeurosis descends medially to fuse with the deep fascia of the forearm.

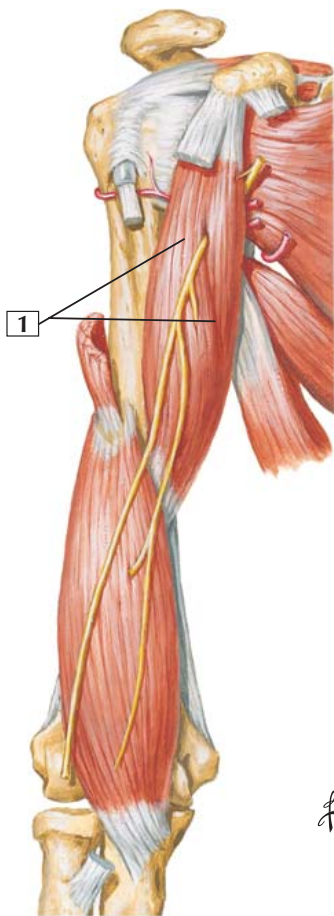
Action: With the forearm partially flexed, the biceps brachii is a powerful supinator of the forearm. It also is an important flexor of the supinated forearm. It assists other muscles, although weakly, as a flexor of the arm at the shoulder.

Innervation: Musculocutaneous nerve (C5 and C6).

Comment: As its name implies, the biceps is a fusiform muscle that has 2 heads. Its insertion by the bicipital aponeurosis allows it to flex the elbow.

The brachial artery supplies blood to this muscle.

Clinical: Tapping the biceps tendon elicits the biceps tendon reflex, testing spinal cord segments C5 and C6. The biceps is tested clinically by having a patient flex the supinated forearm against resistance and watching for the distinct contraction of the biceps in the anterior arm. This action also tests the integrity of the musculocutaneous nerve.



*F. Netter
M.D.*

1. Coracobrachialis

Origin (proximal): Arises from the apex of the coracoid process of the scapula along with the short head of the biceps brachii.

Insertion (distal): Inserts into the middle of the medial surface and border of the humerus.

Action: Flexes and adducts the arm at the shoulder.

Innervation: Musculocutaneous nerve (C6 and C7).

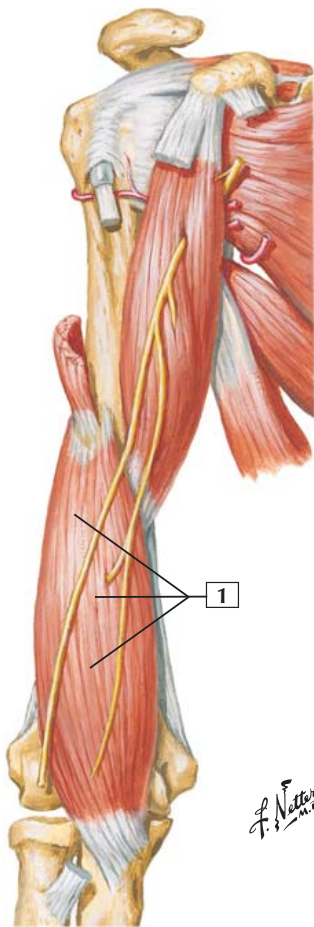
Comment: The coracobrachialis is the smallest of the 3 anterior compartment muscles of the arm.

The brachial artery supplies the coracobrachialis with blood.

As the musculocutaneous nerve leaves the brachial plexus, it usually dives into the proximal portion of the coracobrachialis muscle.

Clinical: Since the musculocutaneous nerve runs through the coracobrachialis muscle, it is vulnerable to nerve compression within the muscle and this can lead to weakness of elbow flexion (loss of some brachialis and biceps function) and hypesthesia of the lateral forearm.

Deep layer





1. Brachialis

Origin (proximal): Arises from the distal half of the anterior humerus.

Insertion (distal): Inserts into the tuberosity and the anterior surface of the coronoid process of the ulna.

Action: The brachialis is a powerful flexor of the forearm at the elbow.

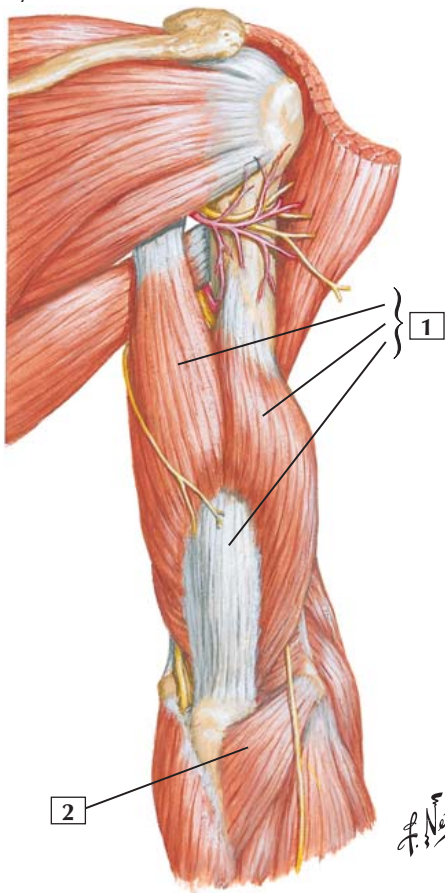
Innervation: Musculocutaneous nerve (C5 and C6). Also, the radial nerve sends a minor branch to the brachialis (C7).

Comment: Because the brachialis is covered superficially by the biceps, it is often not appreciated as the most important and powerful flexor of the forearm at the elbow. Although the muscle can participate in quick flexion, its isometric contraction maintains the flexed position, especially when a weight is applied to the forearm.

The brachial artery supplies the brachialis with blood.

Clinical: Damage to the musculocutaneous nerve proximal to the brachialis (compression injury as it passes through the coracobrachialis muscle) can lead to weakness in the brachialis and biceps brachii muscles, thus affecting elbow flexion.

Superficial layer



1. Triceps brachii
2. Anconeus

Origin (proximal): The long head of the triceps arises from the infraglenoid tubercle of the scapula. The lateral head arises from the posterior surface of the humerus. The medial head arises from the posterior surface of the humerus inferior to the radial groove.

The anconeus arises from the lateral epicondyle of the humerus.

Insertion (distal): All 3 heads of the triceps insert by a common tendon into the posterior portion of the proximal olecranon of the ulna. A band of fibers continues distally on the lateral side over the anconeus to blend with the deep fascia of the forearm.

The anconeus inserts into the lateral aspect of the olecranon and into the upper dorsal surface of the body of the ulna.

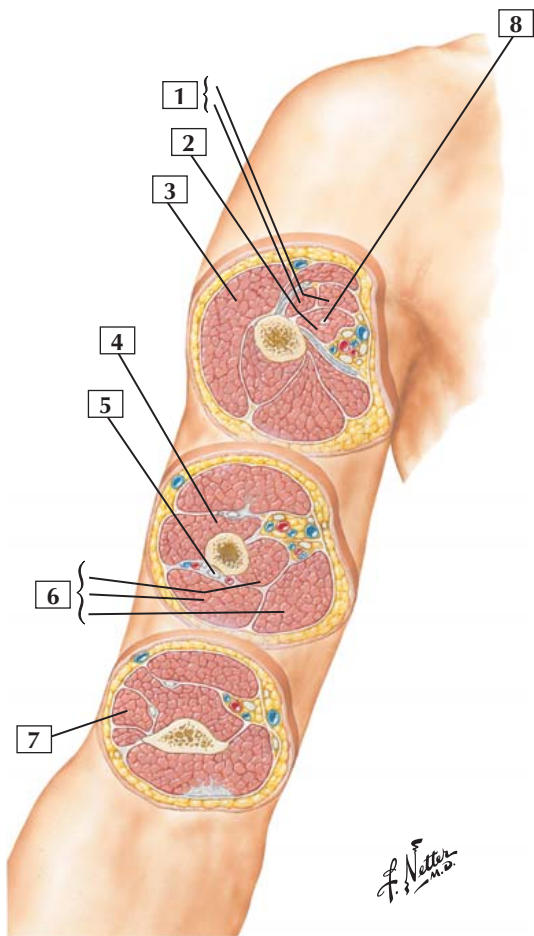
Action: The anconeus muscle and all 3 heads of the triceps extend the forearm at the elbow. The anconeus also abducts the ulna during pronation. The long head of the triceps, arising from the scapula, also can extend the humerus (arm) at the shoulder joint.

Innervation: The triceps and anconeus are supplied by the radial nerve (C7 and C8).

Comment: The medial head of the triceps is the functional counterpart of the chief flexor of the elbow, the brachialis. The medial head is misnamed; it lies deep, not medial.

The triceps receives its blood supply from the deep brachial artery.

Clinical: Tapping the triceps tendon elicits the triceps reflex, testing spinal cord segments C7 and C8.



1. Biceps brachii (Short and Long heads)
2. Coracobrachialis muscle
3. Deltoid muscle
4. Brachialis muscle
5. Radial nerve
6. Triceps brachii muscle (Medial, Lateral, and Long heads)
7. Brachioradialis muscle
8. Musculocutaneous nerve

Comment: Functionally, the arm is divided into an anterior compartment and a posterior compartment. Simplistically, the anterior compartment contains the flexors of the elbow and the posterior compartment contains the extensors of the elbow.

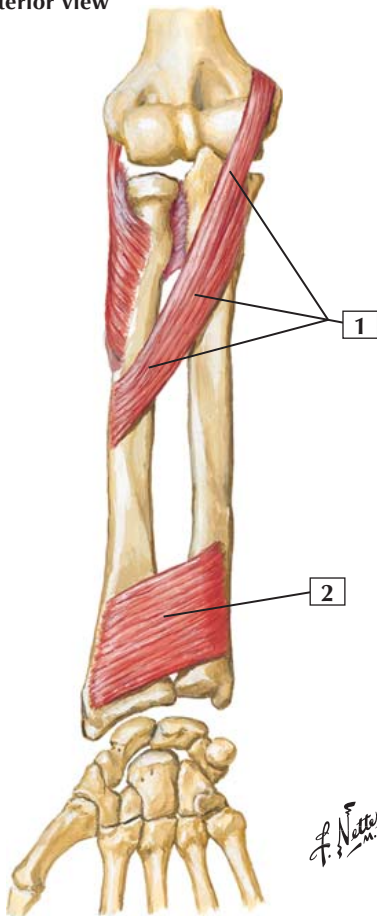
The musculocutaneous nerve innervates the muscles of the anterior, or flexor, compartment. The radial nerve innervates the muscles of the posterior, or extensor, compartment.

The anterior compartment is supplied largely by the brachial artery and its branches. The posterior compartment is supplied largely by the deep brachial (profunda brachii) artery and its branches.

The median and ulnar nerves pass through the arm in a medial neurovascular bundle compartment as they course to the forearm. These 2 nerves do not innervate muscles of the arm.

Clinical: The radial nerve passes around the shaft of the humerus to gain access to the posterior compartment of the arm. Fractures of the shaft of the humerus can place the radial nerve in jeopardy of being stretched or torn as it wraps around the humerus, affecting wrist and finger extensors.

Right forearm: anterior view
Supination



1. Pronator teres
2. Pronator quadratus

Origin (proximal): The pronator teres has 2 heads. The humeral head arises immediately above the medial epicondyle from the common flexor tendon, the intermuscular septum, and antebrachial fascia. The ulnar head arises from the medial side of the coronoid process of the ulna.

The pronator quadratus arises from the medial aspect of the anterior surface of the distal one-fourth of the ulna.

Insertion (distal): The pronator teres inserts about midway along the lateral surface of the radius.

The pronator quadratus inserts into the distal fourth of the lateral border and anterior surface of the shaft of the radius.

Action: The pronator teres rotates the radius on the ulna (pronation) and helps flex the forearm at the elbow.

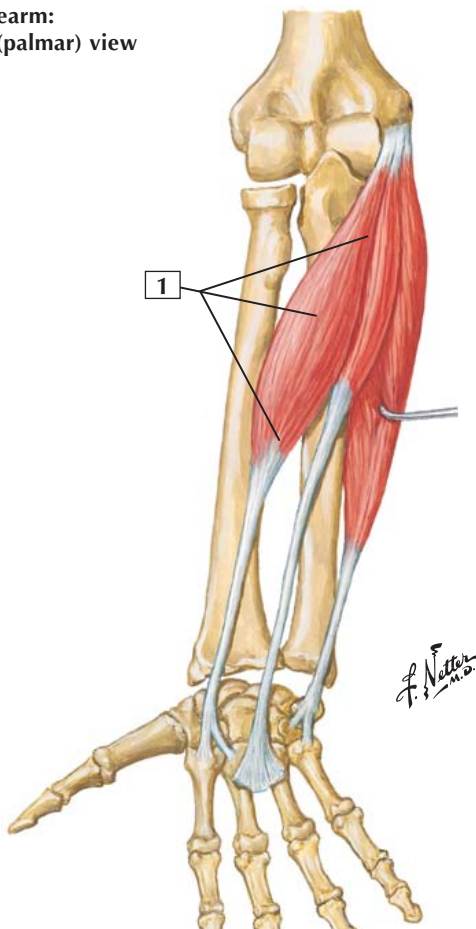
The pronator quadratus pronates the hand. It is assisted by the pronator teres when additional power is required.

Innervation: Both muscles are innervated by the median nerve (pronator teres—C6 and C7; pronator quadratus—C8 and T1).

Comment: The pronator teres is well suited for quick, powerful pronation. The pronator quadratus is the deepest muscle in the forearm, and its contraction is difficult to show.

Clinical: One clinically tests the pronator teres by grasping the patient's hand with the forearm extended and asking the patient to pronate against resistance (turn the hand downward) while watching the medial epicondyle of the humerus to see if the muscle contracts.

Right forearm:
anterior (palmar) view



1. Flexor carpi radialis

Origin (proximal): Arises from the medial epicondyle of the humerus and the antebrachial fascia.

Insertion (distal): Inserts into the base of the 2nd metacarpal bone and sends a slip to the base of the 3rd metacarpal bone.

Action: Flexes the hand at the wrist joint and aids in wrist abduction.

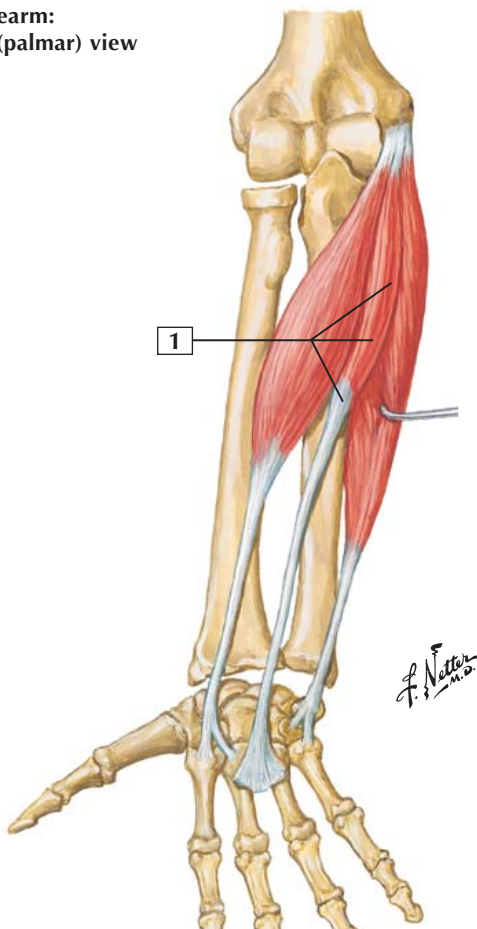
Innervation: Median nerve (C6 and C7).

Comment: The radial extensors help the flexor carpi radialis abduct the wrist.

Distally at the wrist, the radial artery pulse may be palpated just lateral to the tendon of this muscle.

Clinical: One can clinically test the flexor carpi radialis by grasping the patient's hand and having the patient flex the wrist against resistance. As the patient does this, look for the tendon of the muscle to tighten in the wrist.

Right forearm:
anterior (palmar) view



1. Palmaris longus

Origin (proximal): Arises from the medial epicondyle of the humerus by the common flexor tendon and the antebrachial fascia.

Insertion (distal): Inserts into the anterior aspect of the distal flexor retinaculum and into the palmar aponeurosis.

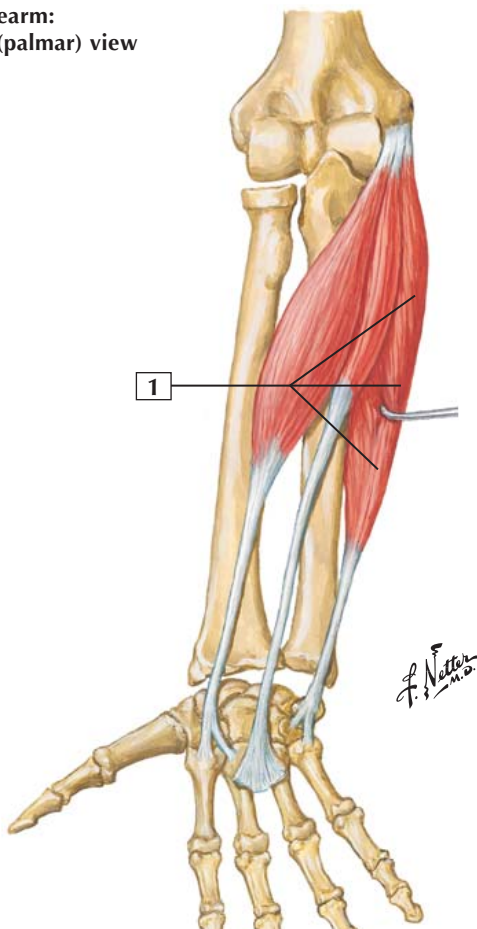
Action: Flexes the hand at the wrist and tightens the palmar aponeurosis.

Innervation: Median nerve (C6 and C7).

Comment: The palmaris longus is vestigial in humans and is absent in 10-15% of the population. In other species, this muscle retracts the claws. In humans, it acts primarily at the wrist.

Clinical: By having the patient make a tight fist, one can determine if the patient possesses the palmaris longus muscle, as its tendon will appear in the mid wrist. The median nerve lies just lateral to the tendon of this muscle before entering the carpal tunnel.

Right forearm:
anterior (palmar) view



1. Flexor carpi ulnaris

Origin (proximal): Has 2 heads. The humeral head arises from the medial epicondyle of the humerus by the common flexor tendon. The ulnar head arises from the medial margin of the olecranon and posterior border of the ulna.

Insertion (distal): Inserts into the pisiform bone, but an extension of its ligament attaches to the hook of the hamate and base of the 5th metacarpal. Several of its fibers also attach to the flexor retinaculum.

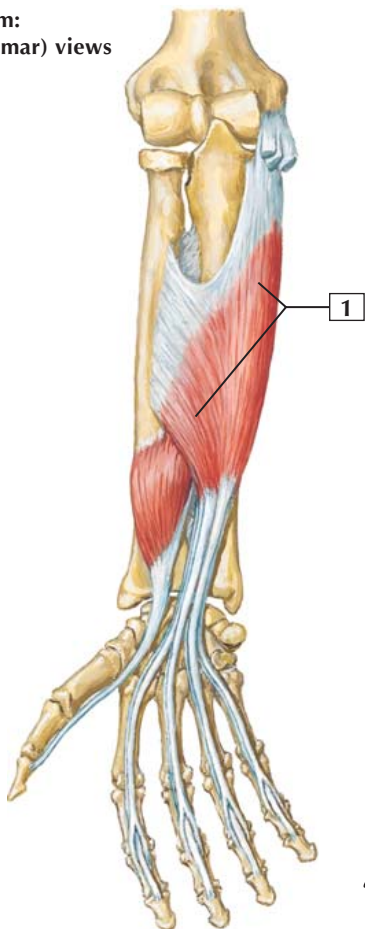
Action: Flexes and adducts the hand at the wrist.

Innervation: Ulnar nerve (C7 and C8).

Comment: The 2 heads of this muscle join just below the medial epicondyle; the ulnar nerve runs between the heads as it courses toward the wrist. The ulnar extensor helps the flexor carpi ulnaris adduct the hand at the wrist.

Clinical: As the ulnar nerve passes between the 2 heads of the flexor carpi ulnaris, the nerve can become compressed, leading to a cubital tunnel syndrome. This syndrome is second only to carpal tunnel syndrome among compression neuropathies. Compression may be especially acute as the elbow is flexed because this narrows the space between the 2 muscle heads.

Right forearm:
anterior (palmar) views



*F. Netter
M.D.*

1. Flexor digitorum superficialis

Origin (proximal): This muscle arises by 2 heads and inserts by 4 tendons. The humeroulnar head arises from the medial epicondyle of the humerus, the ulnar collateral ligament, and the coronoid process of the ulna. The radial head arises from the superior half of the anterior aspect of the radius.

Insertion (distal): Four tendons of insertion attach to the bodies of the middle phalanges of the medial 4 digits (index finger to little finger).

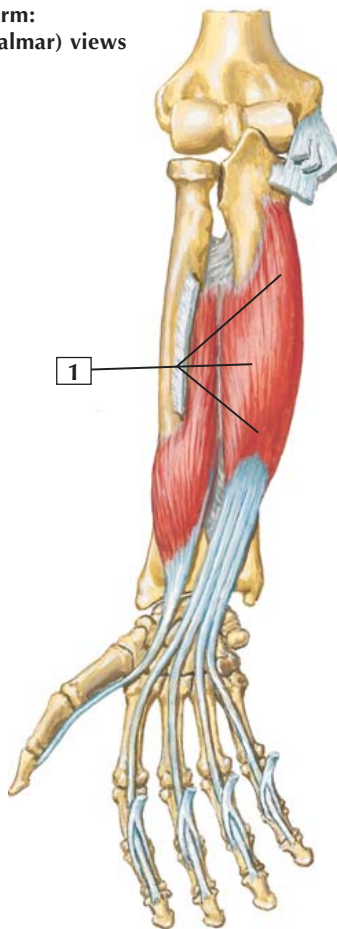
Action: This muscle acts primarily as a flexor of the proximal interphalangeal joints. It also contributes to flexion of all the joints it crosses, including the elbow, wrist, and metacarpophalangeal joints.

Innervation: Median nerve (C7, C8, and T1).

Comment: Opposite the bases of the 1st phalanges, each tendon divides to allow the corresponding tendon of the deep flexor (flexor digitorum profundus) to reach each finger. A common synovial tendon sheath, or bursa, wraps around both sets of tendons, facilitating the sliding of the tendons over one another.

Clinical: Testing this muscle is done by asking the patient to flex the index or middle finger while one holds it between the thumb and index finger in a flexed position at the proximal interphalangeal joint, thus providing resistance. As the patient tries to flex the joint and move the finger toward the palm, the muscle's strength can be assessed.

Right forearm:
anterior (palmar) views



1. Flexor digitorum profundus

Origin (proximal): Arises from the proximal three-fourths of the medial and anterior aspects of the ulna and from the interosseous membrane.

Insertion (distal): Four tendons attach to the bases of the distal phalanges of the medial 4 digits (index finger to little finger).

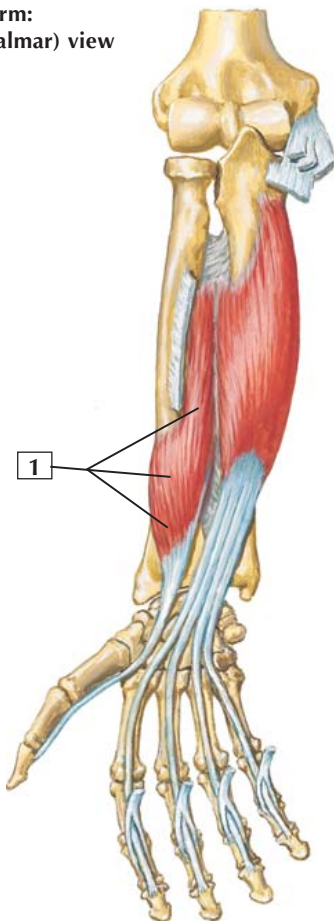
Action: The primary action is flexion of the distal interphalangeal joints. The muscle also produces some flexion at the proximal interphalangeal joints, the metacarpophalangeal joints, and the wrist because its tendons cross those joints.

Innervation: Proximal to the wrist, this muscle divides into 2 parts. The medial part is innervated by the ulnar nerve (C8 and T1). The lateral portion of the muscle is innervated by the anterior interosseous branch of the median nerve (C8 and T1).

Comment: The tendons of the flexor digitorum profundus, similar to those of the superficialis, cross the carpal canal and the palm of the hand. The 4 tendons pass through the slits of the superficialis tendons before attaching to the distal phalanges.

Clinical: This muscle is tested clinically by having the patient flex the distal interphalangeal joint against resistance as one place's the thumb and index finger on the proximal interphalangeal joint of the tested finger to keep it in extension and then hold the tip of the finger to provide resistance to flexion of the distal interphalangeal joint.

Right forearm:
anterior (palmar) view



1. Flexor pollicis longus

Origin (proximal): Anterior aspect of the radius and adjacent interosseous membrane.

Insertion (distal): Base of the distal phalanx of the thumb.

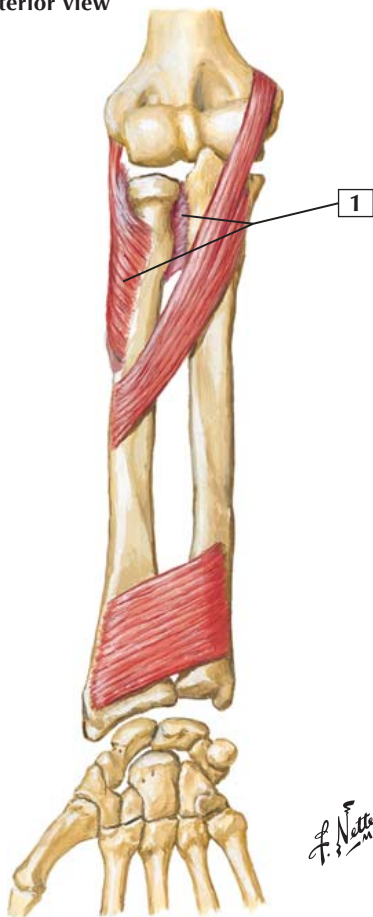Action: The primary action is flexion of the distal phalanx of the thumb. The muscle also can flex the proximal phalanx because its tendon crosses that joint.

Innervation: Median nerve (anterior interosseous branch) (C7, C8, and T1).

Comment: The tendon of this unipennate muscle belly crosses the carpal canal on the lateral or radial side of the digital flexor tendons and passes to the distal phalanx of the thumb. The tendon has its own synovial sheath.

Clinical: This muscle is tested clinically by asking the patient to flex the tip of the thumb against resistance while the examiner holds the proximal phalanx fixed between the thumb and fingers. This action not only tests the strength of muscle contraction but also tests the integrity of the median nerve, which innervates this muscle.

Right forearm: anterior view
Supination



1. Supinator

Origin (proximal): Arises from the lateral epicondyle of the humerus, the radial collateral ligament of the elbow joint, the annular ligament of the proximal radioulnar joint, the supinator fossa, and the crest of the ulna.

Insertion (distal): Inserts into the lateral, posterior, and anterior surfaces of the proximal third of the radius.

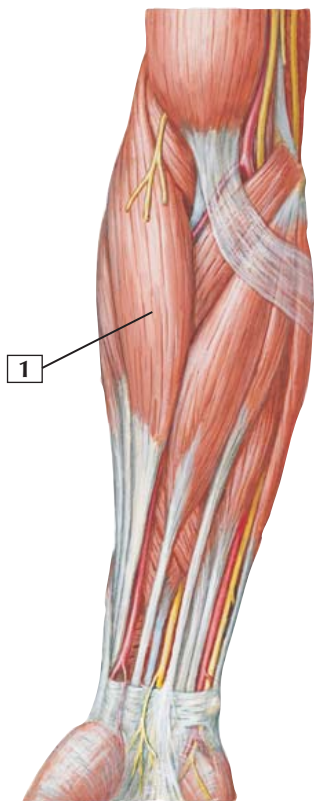
Action: The supinator rotates the radius to supinate the forearm and hand. Supination occurs whether the forearm is flexed or extended.

Innervation: Deep branch of the radial nerve (C5 and C6).

Comment: The most powerful supinator of the forearm is the biceps brachii, which acts primarily when the forearm is flexed. In contrast, the supinator can supinate a forearm that is flexed or extended.

The posterior interosseous artery passes through the supinator, serving as its major blood supply.

Clinical: The deep branch of the radial nerve (the radial nerve's motor component) can become compressed as it passes through the supinator, leading to a posterior compartment neuropathy, resulting in weakened extension of the wrist and fingers. The supinator is tested clinically by having the patient supinate the extended forearm against resistance.



1. Brachioradialis

Origin (proximal): Proximal two-thirds of the lateral supracondylar ridge of the distal humerus and intermuscular septum.

Insertion (distal): Lateral aspect of the distal radius just proximal to the styloid process.

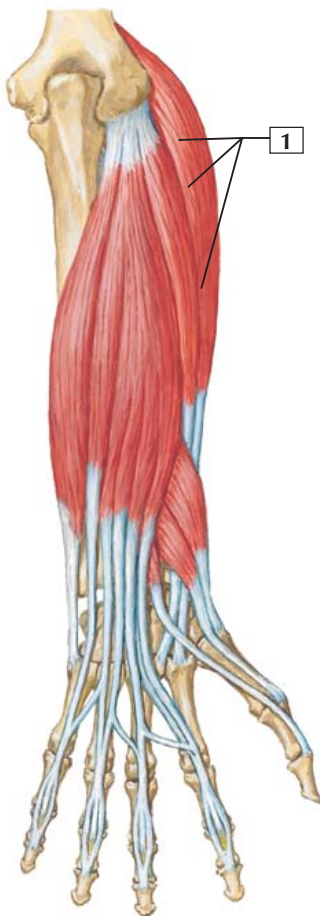
Action: Accessory flexor of the forearm at the elbow.

Innervation: Radial nerve (C5 and C6), before it divides into its superficial and deep branches.

Comment: The brachioradialis is a unique muscle in that it is a muscle of the posterior compartment of the forearm (radial nerve innervated) but is not an extensor or supinator. It is a weak flexor of the forearm at the elbow and is most efficient as a flexor when the forearm is in mid pronation.

Clinical: If one tests forearm flexion against resistance in the mid-pronated position, the brachioradialis is easily seen as a muscle bulge over the lateral epicondyle of the elbow. Pain over the lateral epicondyle is often referred to as “tennis elbow,” but this muscle pain, usually from overexertion, can be caused by a number of actions, including playing tennis or golf or lifting heavy objects (e.g., a suitcase) by a handle.

Right forearm:
posterior
(dorsal) view



1. Extensor carpi radialis longus

Origin (proximal): Lateral supracondylar ridge of the humerus.

Insertion (distal): Attaches to the base of the 2nd metacarpal.

Action: Extends and abducts the hand at the wrist joint.

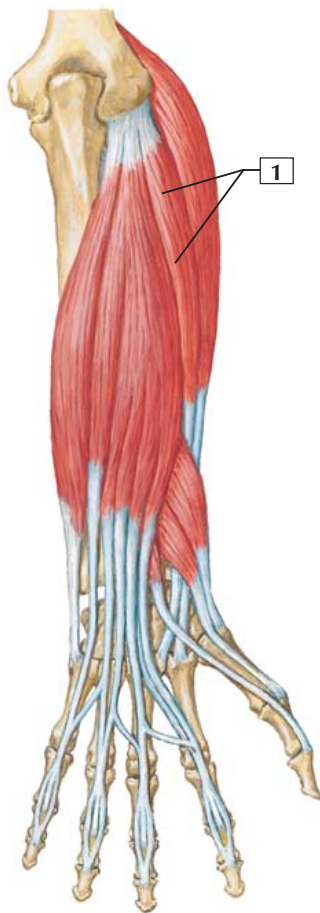Innervation: Radial nerve (C6 and C7).

Comment: This muscle arises just distal to the brachioradialis muscle. Its belly ends in the proximal third of the forearm. Its flat tendon continues distally along the lateral border of the radius beneath the abductor pollicis longus and extensor pollicis brevis muscles.

This muscle also acts synergistically during flexion of the fingers by extending the hand at the wrist to give additional strength when the hand grasps an object. This action is essential for a power grip.

Clinical: This muscle is tested clinically by having the patient extend and abduct the hand at the wrist against resistance. This requires that the examiner holds the patient's fist and applies resistance to the lateral aspect of the wrist while having the patient try to bend the fist laterally (abduct or move it toward the thumb side of the wrist) and extend the wrist simultaneously.

Right forearm:
posterior
(dorsal) view



F. Netter M.D.

1. Extensor carpi radialis brevis

Origin (proximal): Lateral epicondyle of the humerus.

Insertion (distal): Base of the 3rd metacarpal bone.

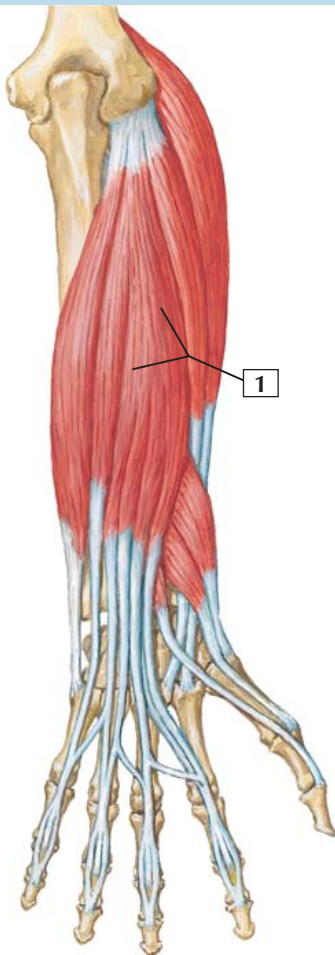
Action: Extends and abducts the hand at the wrist joint.

Innervation: Radial nerve (deep branch) (C7 and C8).

Comment: This muscle is shorter and thicker than the extensor carpi radialis longus, which partially covers it. Occasionally, both muscles form a single belly that gives rise to 2 tendons. This muscle is important for a power grip (a power grip requires wrist extension).

Clinical: This muscle acts along with the extensor carpi radialis longus and is tested clinically along with that muscle. The patient is asked to extend and abduct the hand at the wrist against resistance. This action not only tests these two muscles but also tests the integrity of the radial nerve (its deep branch).

Right forearm:
posterior
(dorsal) view



1. Extensor digitorum

Origin (proximal): Lateral epicondyle of the humerus.

Insertion (distal): Extensor expansions of the medial 4 digits (index finger to little finger).

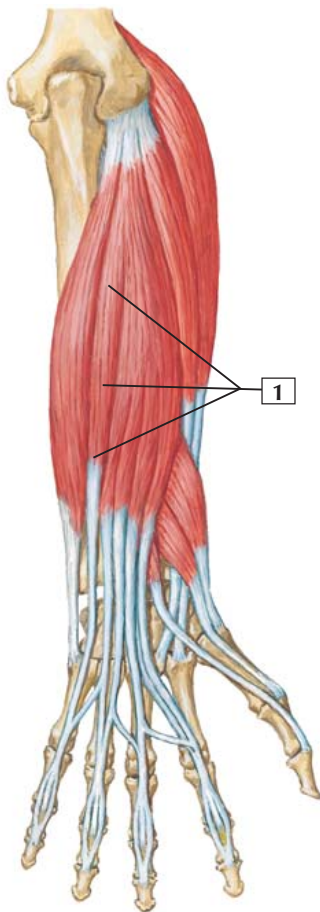
Action: Extension at the metacarpophalangeal and interphalangeal joints. This muscle also participates in wrist extension when the fingers are extended.

Innervation: Radial nerve (posterior interosseous branch) (C7 and C8).

Comment: The tendons of the extensor digitorum pass through the extensor retinaculum and to the extensor expansions of the medial 4 digits. Occasionally, this muscle has only 3 tendons instead of 4. Often, the extensor digiti minimi is attached to the extensor digitorum.

Clinical: This muscle is tested clinically by having the patient extend the fingers against resistance. This is best done as one supports the patient's pronated hand with one hand and provides resistance to the fingers across the metacarpophalangeal joints with the other hand. The contracting muscle belly will bulge out along the lateral forearm (little finger side in the pronated position).

Right forearm:
posterior
(dorsal) view



1. Extensor digiti minimi

Origin (proximal): Lateral epicondyle of the humerus.

Insertion (distal): Extensor expansion of the 5th digit.

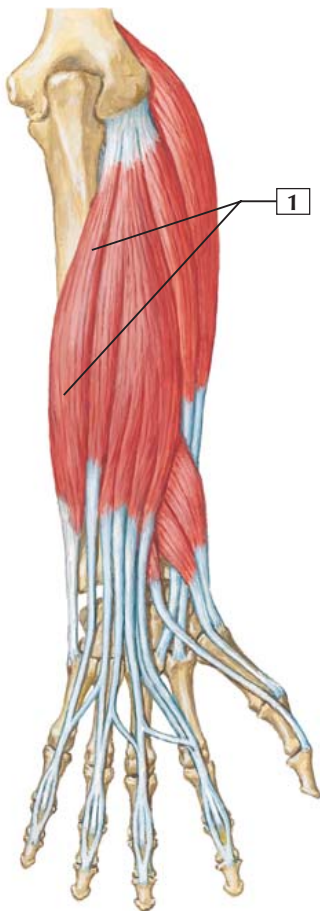
Action: Extends the 5th digit at the metacarpophalangeal and interphalangeal joints. This muscle also participates in wrist extension when the fingers are extended.

Innervation: Radial nerve (posterior interosseous branch) (C7 and C8).

Comment: This slender muscle is often connected to the larger extensor digitorum.

Clinical: This small muscle acts with many of the other finger and wrist extensors and usually will not be tested clinically as an individual muscle, because its isolated action is difficult to ascertain.

Right forearm:
posterior
(dorsal) view



1. Extensor carpi ulnaris

Origin (proximal): This muscle has 2 heads. One head arises from the lateral epicondyle of the humerus, and the other arises from the posterior border of the ulna.

Insertion (distal): Attaches to the medial side of the base of the 5th metacarpal.

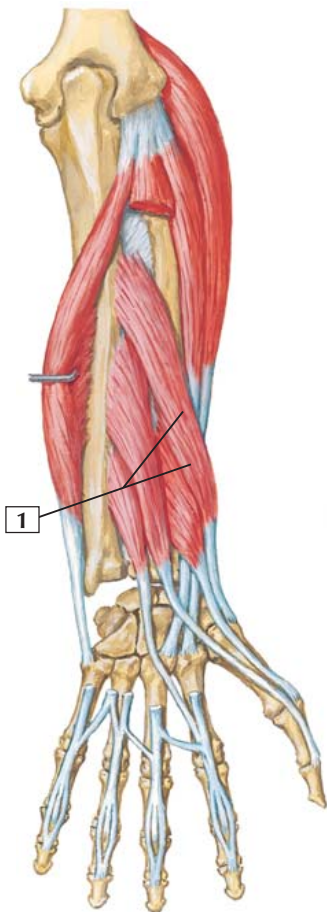
Action: Extends and adducts the hand at the wrist joint.

Innervation: Radial nerve (posterior interosseous branch) (C7 and C8).

Comment: Similar to the extensor carpi radialis longus and brevis muscles, the extensor carpi ulnaris acts as a synergist to the finger flexors because it keeps the wrist extended to give additional strength when the hand grasps an object. This action is essential for a power grip.

Clinical: Clinically, this muscle is tested by having the patient extend and adduct the wrist against resistance. The examiner can hold the patient's pronated fist and provide resistance against wrist extension and adduction (movement toward the little finger side of the wrist). The bulging contracted muscle belly will be evident along the medial forearm and its tendon at the wrist.

Right forearm:
posterior
(dorsal) view



1. Abductor pollicis longus

Origin (proximal): Posterior aspect of the ulna, radius, and interosseous membrane.

Insertion (distal): Attaches to the base of the first metacarpal bone.

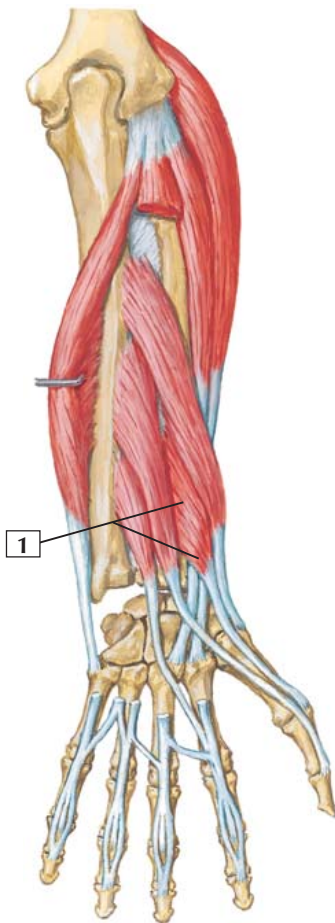
Action: Abducts, extends, and laterally rotates the thumb at the carpometacarpal joint. It also may contribute to abduction of the wrist.

Innervation: Radial nerve (posterior interosseous branch) (C7 and C8).

Comment: When the thumb is abducted, the tendon of the abductor pollicis longus becomes prominent and forms the lateral boundary of the “anatomic snuff box.”

Clinical: This muscle is tested clinically by having the patient supinate the hand (palm up) and extend the forearm at the elbow. Then place a finger on the lateral aspect of the patient’s extended thumb for resistance and ask the patient to try to move the thumb toward the elbow (abduct). While the patient does this, look for the tendon of the muscle running to the base of the thumb’s metacarpal bone.

Right forearm:
posterior
(dorsal) view



1. Extensor pollicis brevis

Origin (proximal): Arises from the posterior surface of the radius and the interosseous membrane.

Insertion (distal): Attaches to the base of the proximal phalanx of the thumb.

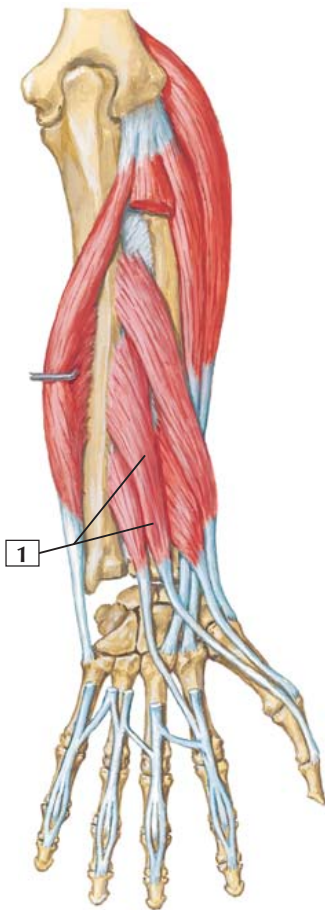
Action: Extends the proximal phalanx of the thumb at the metacarpophalangeal joint. By its continued action, it also can extend the first metacarpal bone at the carpometacarpal joint.

Innervation: Radial nerve (posterior interosseous branch) (C7 and C8).

Comment: This short extensor of the thumb courses with the abductor pollicis longus muscle. The tendons of the 2 muscles form part of the lateral boundary of the “anatomic snuff box.”

Clinical: One can test this muscle clinically by having the patient supinate the extended hand and then attempt to extend the thumb (the hitch-hiking thumb position) against resistance. In addition to testing the strength of the muscle, the tendon of the muscle also should be visible and palpable over the dorsal surface of the thumb’s metacarpophalangeal joint.

Right forearm:
posterior
(dorsal) view



Extensor Pollicis Longus

1. Extensor pollicis longus

Origin (proximal): Posterior surface of the middle third of the ulna and the interosseous membrane.

Insertion (distal): Attaches to the base of the distal phalanx of the thumb.

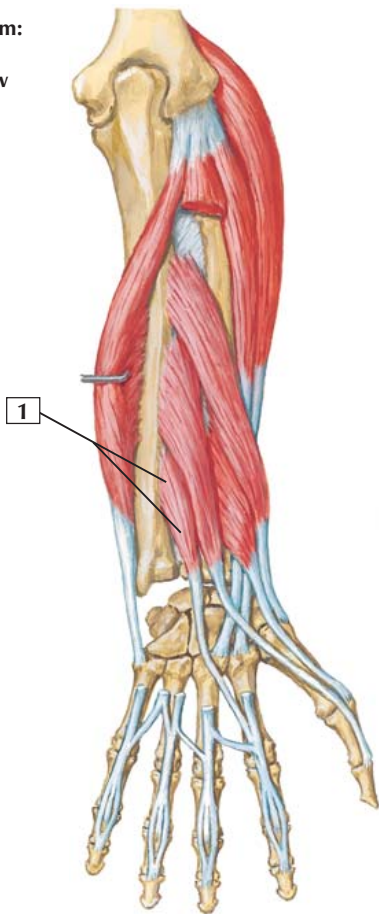
Action: Extends the distal phalanx of the thumb at the metacarpophalangeal and interphalangeal joints. Because it runs in an oblique fashion, it can contribute to abduction of the thumb.

Innervation: Radial nerve (posterior interosseous branch) (C7 and C8).

Comment: The tendon of the extensor pollicis longus forms the medial or ulnar border of the “anatomic snuff box.”

Clinical: The radial artery can be found within the anatomic snuffbox, and its pulse may be palpated at that point. The anatomic snuff box is bounded laterally by the tendons of the abductor pollicis longus and extensor pollicis brevis muscles and medially by the extensor pollicis longus tendon. The scaphoid carpal bone lies in the floor of the snuff box; fracture from a fall on the outstretched hand will present as pain and swelling in the snuff box (the scaphoid is the most commonly fractured carpal bone).

Right forearm:
posterior
(dorsal) view



*F. Netter
M.D.*

1. Extensor indicis

Origin (proximal): Posterior surface of the ulna and the interosseous membrane.

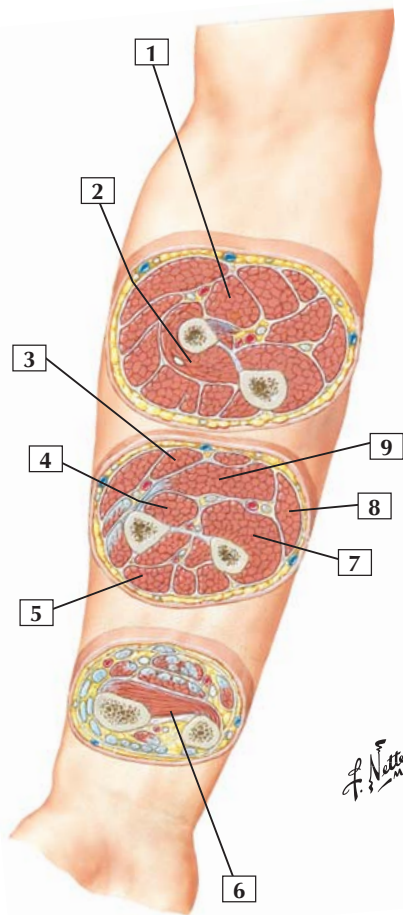
Insertion (distal): Extensor expansion of the 2nd digit.

Action: Extends all the joints of the index finger. Can help other extensors extend the wrist.

Innervation: Radial nerve (posterior interosseous branch) (C7 and C8).

Comment: This narrow, elongated muscle lies medial and parallel to the extensor pollicis longus muscle. It permits the index finger to extend independently of the other fingers.

Clinical: Along with the extensor digitorum muscle, this muscle provides independent extension of the index finger, such that the other digits may be flexed while still extending the index finger (pointing at someone). This maneuver is more difficult to do with any of the other fingers.



1. Pronator teres
2. Supinator
3. Flexor carpi radialis
4. Flexor pollicis longus
5. Extensor digitorum
6. Pronator quadratus
7. Flexor digitorum profundus
8. Flexor carpi ulnaris
9. Flexor digitorum superficialis

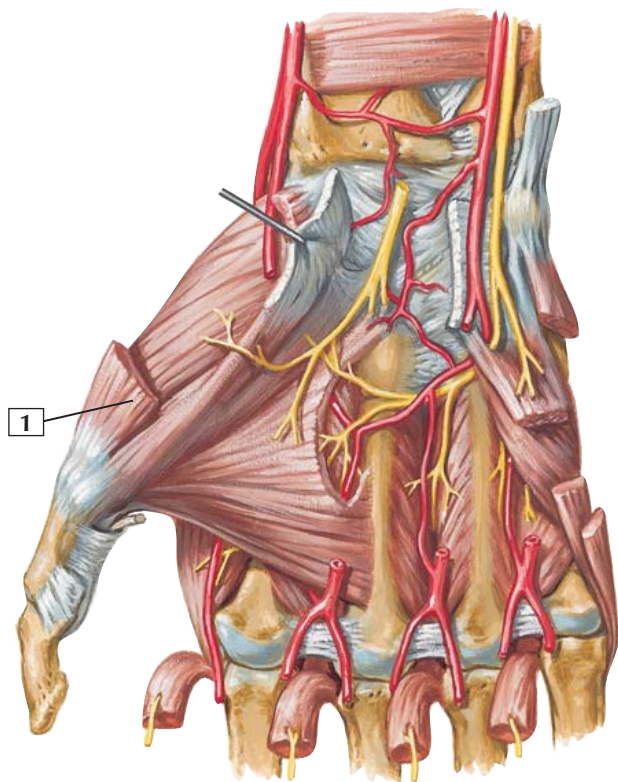
Comment: Muscles of the forearm are divided into an anterior compartment and a posterior compartment. Muscles in the anterior compartment are largely flexors at the wrist and of the fingers. Muscles in the posterior compartment generally are extensors at the wrist and of the fingers.

Muscles of the anterior, or flexor, compartment of the forearm are innervated largely by the median nerve and its branches. Only the flexor carpi ulnaris and the medial half of the flexor digitorum profundus are innervated by the ulnar nerve and its branches.

Muscles of the posterior compartment of the forearm are innervated by the radial nerve and its branches.

Clinical: Rarely do muscles act alone but contract and function on a joint by acting together. Therefore, it is important to think of them in compartments based on their function (e.g., extensors or flexors) and know which nerve and vessels supply the muscles of that compartment.

Anterior (palmar) view



C. Machado
—M.D.

1. Abductor pollicis brevis

Origin (proximal): Arises from the flexor retinaculum and the tubercles of the scaphoid and trapezium bones.

Insertion (distal): Inserts into the lateral side of the base of the proximal phalanx of the thumb.

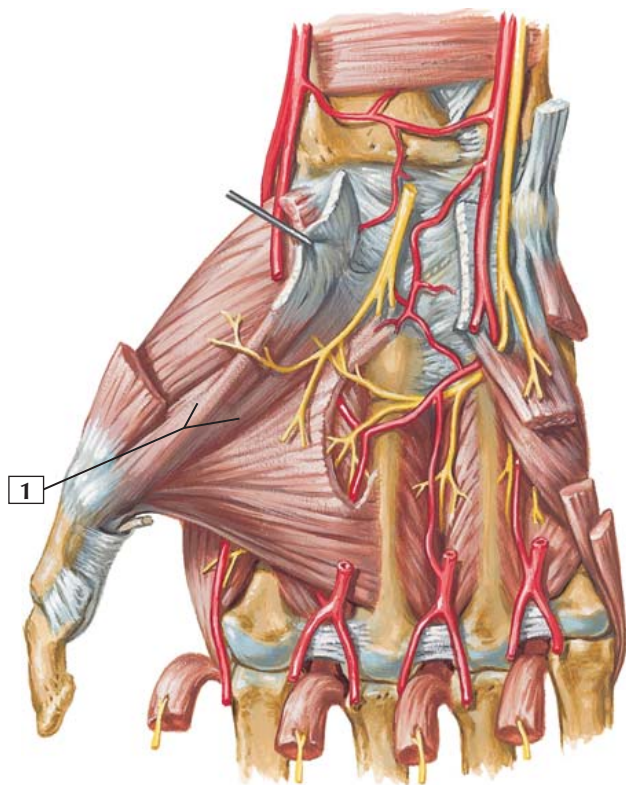
Action: Abducts the thumb at the carpometacarpal and metacarpophalangeal joints.

Innervation: Recurrent branch of the median nerve (C8 and T1).

Comment: This muscle is 1 of the 3 muscles that make up the thenar muscles at the base of the thumb. The thenar muscles are all innervated by the recurrent branch of the median nerve.

Clinical: This muscle is tested clinically by having the patient abduct the thumb against resistance. Abduction of the thumb involves moving it at right angles to the palm toward the elbow in the supinated position. Look for the bulging of the muscle belly in the thenar eminence.

Anterior (palmar) view



C. Machado
—M.D.

1. Flexor pollicis brevis

Origin (proximal): This muscle has 2 heads. The superficial head arises from the flexor retinaculum and the trapezium bone. The deep head arises from the floor of the carpal canal, which overlies the trapezoid and capitate bones.

Insertion (distal): The 2 heads join in a common tendon that inserts on the lateral side of the first metacarpal bone and base of the proximal phalanx. The tendon of insertion contains the radial sesamoid bone of the metacarpophalangeal joint.

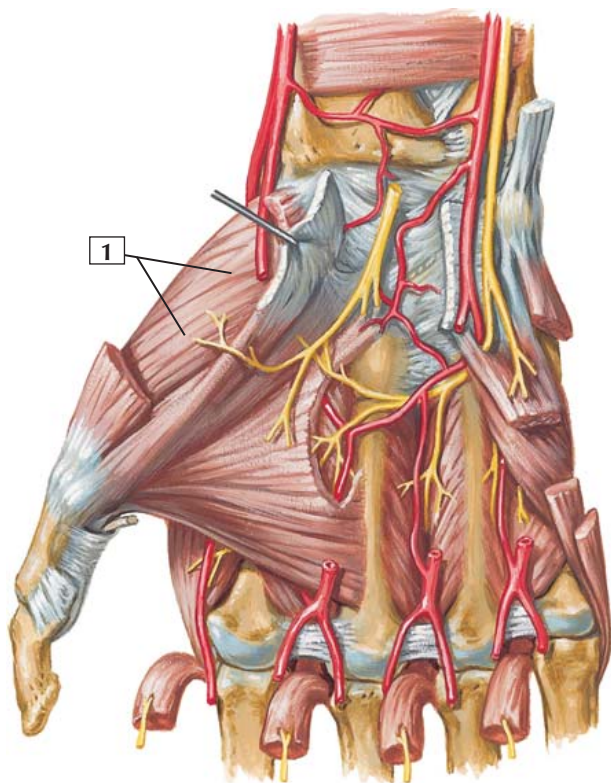
Action: Flexes the proximal phalanx of the thumb at the metacarpophalangeal joint and indirectly rotates the metacarpal bone of the thumb medially at the carpometacarpal joint.

Innervation: Recurrent branch of median nerve (C8 and T1).

Comment: This muscle is 1 of the 3 muscles that make up the thenar muscles at the base of the thumb. The thenar muscles are all innervated by the recurrent branch of the median nerve.

Clinical: The recurrent branch of the median nerve lies somewhat superficial in the palm before diving into the belly of the flexor pollicis brevis muscle. Lacerations across the palm and thenar eminence may sever this important branch, as it innervates 3 of the 4 thenar muscles. Therefore, one must carefully test the integrity of these muscles in hand lacerations.

Anterior (palmar) view



C. Machado
—M.D.

1. Opponens pollicis

Origin (proximal): Arises from the flexor retinaculum and the trapezium bone.

Insertion (distal): Attaches to the lateral side of the 1st metacarpal bone.

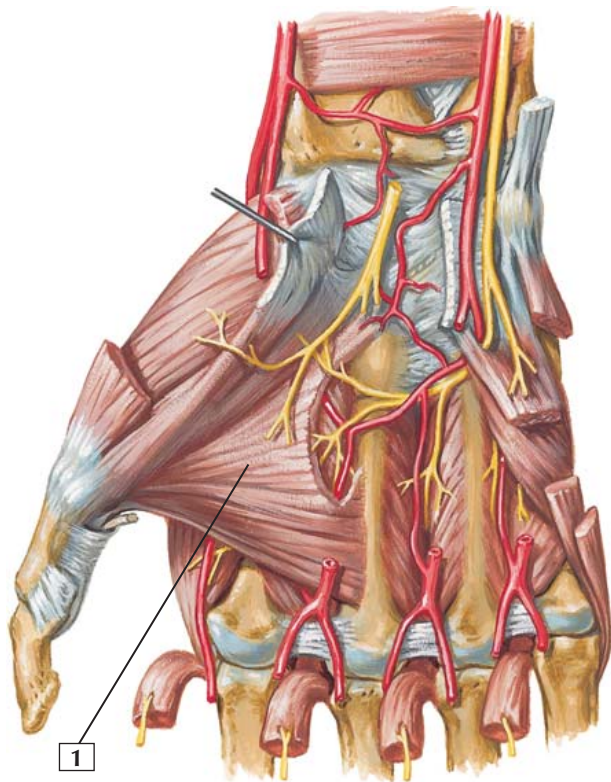
Action: Pulls and rotates the 1st metacarpal in a medial fashion across the palm, opposing the thumb against the fingers.

Innervation: Recurrent branch of the median nerve (C8 and T1).

Comment: This muscle is 1 of the 3 muscles that make up the thenar muscles at the base of the thumb. The thenar muscles are all innervated by the recurrent branch of the median nerve.

Clinical: This muscle is tested clinically by asking the patient to touch the base of the little finger with the thumb while resistance is provided to the palmar side of the base of the thumb.

Anterior (palmar) view



C. Machado
—M.D.

1. Adductor pollicis

Origin (proximal): The proximal fibers make up the oblique head and arise from the bases of the 2nd and 3rd metacarpals and the capitate bone. The transverse head arises from the anterior surface of the body of the 3rd metacarpal bone.

Insertion (distal): Both heads of this muscle converge on a sesamoid bone on the medial or ulnar side of the metacarpophalangeal joint. They attach to the base of the proximal phalanx of the thumb.

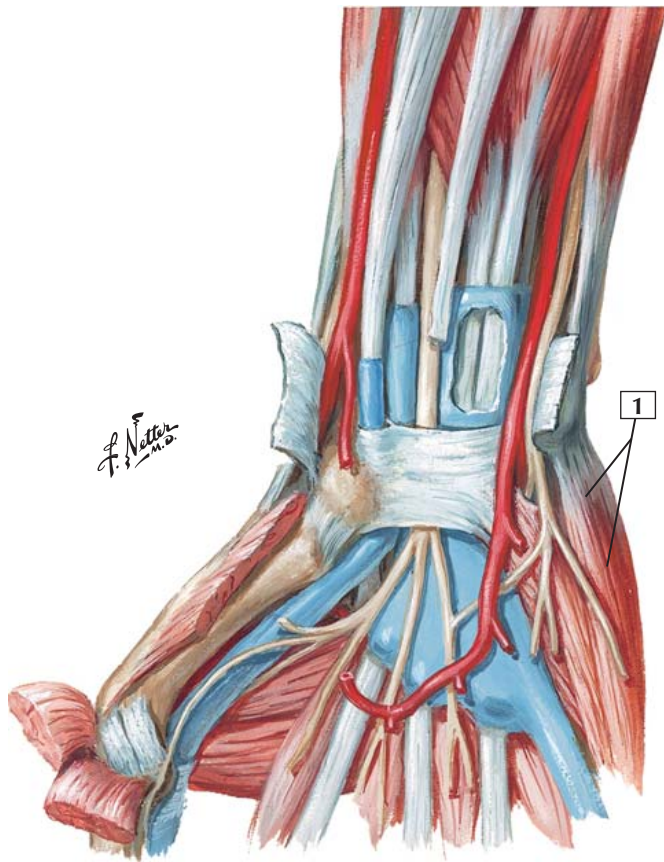
Action: Adducts the proximal phalanx of the thumb toward the middle digit.

Innervation: Deep branch of the ulnar nerve (C8 and T1).

Comment: This muscle is not considered a thenar muscle and, although it acts on the thumb, it is innervated by the ulnar nerve.

Clinical: This muscle is tested clinically by asking the patient to adduct the thumb against resistance. This is done by having the patient place the thumb in a fully abducted position (at right angles to the supinated palm, sticking straight up in the air) and then by providing resistance as the patient tries to move the thumb back into an adducted position (flat in the palm just lateral to the index finger).

Palmar view



1. Abductor digiti minimi

Origin (proximal): Arises from the pisiform bone and the tendon of the flexor carpi ulnaris muscle.

Insertion (distal): Attaches to the medial side of the base of the proximal phalanx of the 5th digit.

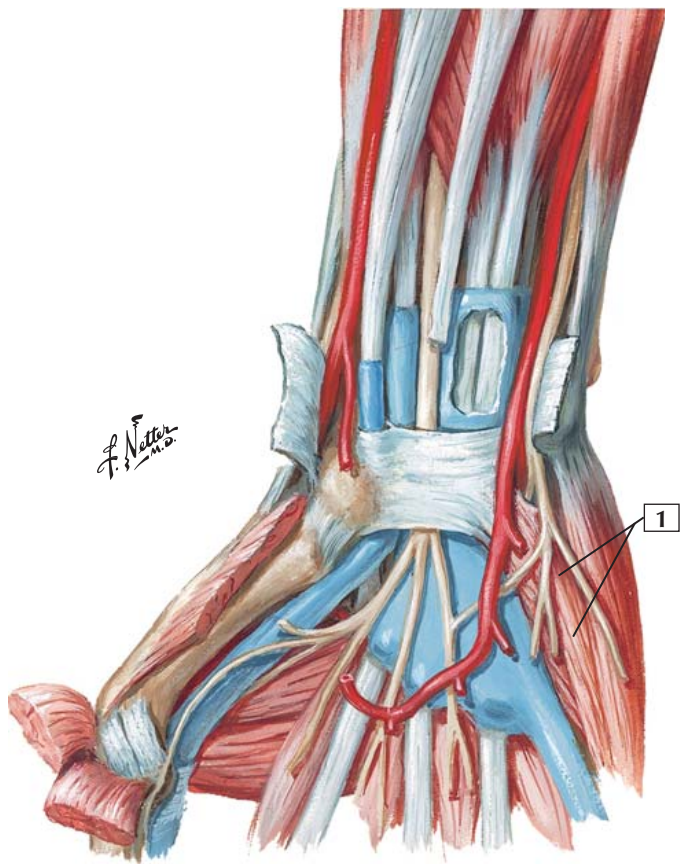
Action: Abducts the 5th digit.

Innervation: Deep branch of the ulnar nerve (C8 and T1).

Comment: This muscle is 1 of the 3 muscles that make up the hypothenar muscles, which constitute the intrinsic muscles of the little finger. All are innervated by deep branches of the ulnar nerve and supplied by deep branches of the ulnar artery.

Clinical: This muscle is tested clinically by having the patient abduct the little finger against resistance. With the palm supinated and fingers extended and together, ask the patient to abduct the little finger (move it medially away from the palm and other fingers) while providing resistance.

Palmar view



1. Flexor digiti minimi brevis

Origin (proximal): Arises from the hook of the hamate bone and the flexor retinaculum.

Insertion (distal): Inserts into the medial aspect of the base of the proximal phalanx of the little finger, as does the abductor digiti minimi.

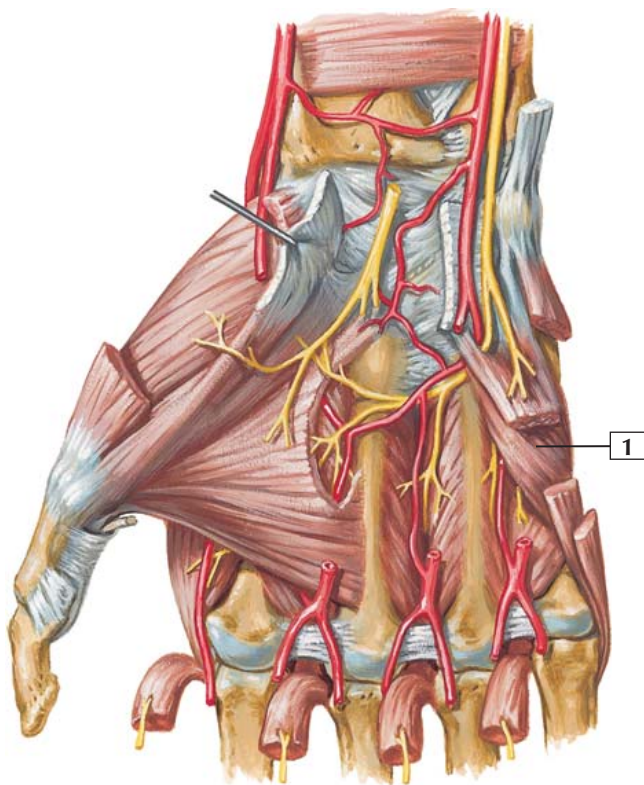
Action: Flexes the proximal phalanx of the 5th digit at the metacarpophalangeal joint.

Innervation: Deep branch of the ulnar nerve (C8 and T1).

Comment: This muscle is 1 of the 3 muscles that make up the hypothenar muscles, which constitute the intrinsic muscles of the little finger. All are innervated by deep branches of the ulnar nerve and supplied by deep branches of the ulnar artery.

Clinical: This muscle is tested clinically by asking the patient to flex the little finger at the metacarpophalangeal joint against resistance. It helps to hold the middle three fingers in an extended position while the patient tries to flex the fifth digit, which should be extended at the interphalangeal joints.

Anterior (palmar) view



C. Machado
— M.D.

1. Opponens digiti minimi

Origin (proximal): Arises from the hook of the hamate bone and the flexor retinaculum.

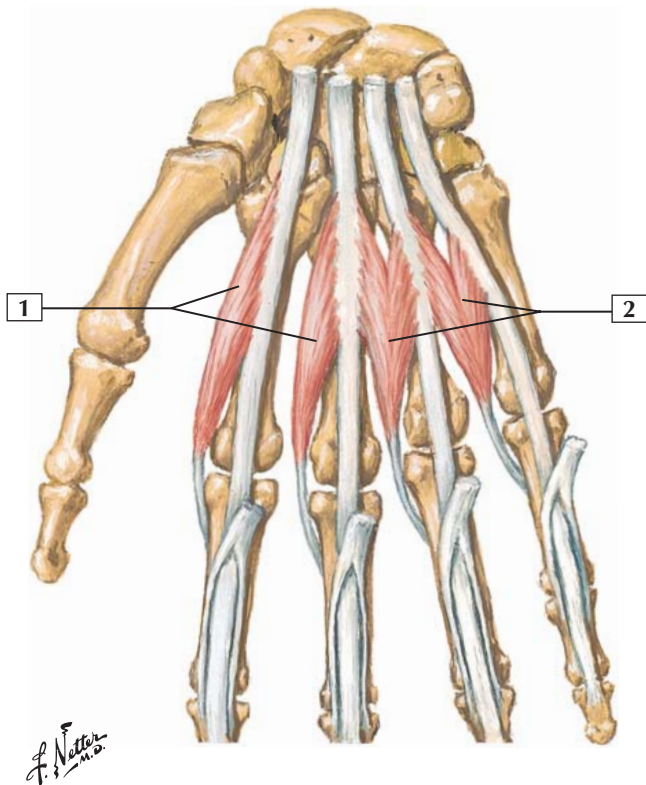
Insertion (distal): Inserts on the palmar surface of the body of the 5th metacarpal.

Action: Abducts, flexes, and laterally rotates the 5th metacarpal, enhancing the cupping of the hand, increasing the power of the grip, and opposing the little finger to the thumb.

Innervation: Deep branch of the ulnar nerve (C8 and T1).

Comment: This muscle is 1 of the 3 muscles that make up the hypothenar muscles, which constitute the intrinsic muscles of the little finger. All of these muscles are innervated by deep branches of the ulnar nerve and supplied by deep branches of the ulnar artery.

Clinical: To clinically test opposition, have the patient touch the tips of the thumb and little finger together and then, with a finger on the patient's thenar and hypothenar eminence, try to pull the opposed fingers apart to test the strength of the opponens muscles.



Lumbrical Muscles

1. Lumbrical muscles 1 and 2
2. Lumbrical muscles 3 and 4

Origin (proximal): Lumbricals 1 and 2 arise from the 2 lateral tendons of the flexor digitorum profundus. Lumbricals 3 and 4 arise from the 3 medial tendons of the flexor digitorum profundus.

Insertion (distal): Attach to the lateral sides of the extensor expansions of digits 2 through 5 (index finger to little finger).

Action: Flex the metacarpophalangeal joints and extend the interphalangeal joints.

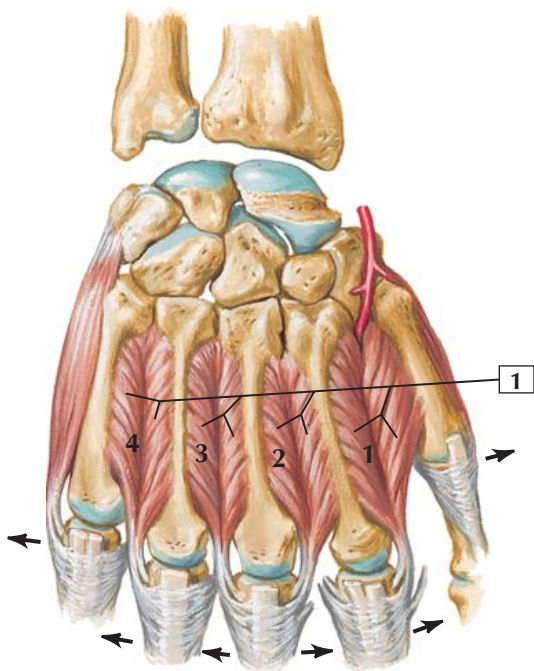
Innervation: Lumbricals 1 and 2 are innervated by the median nerve (C8 and T1). Lumbricals 3 and 4 are innervated by a deep branch of the ulnar nerve (C8 and T1).

Comment: Because of the way the lumbricals pass by the proximal interphalangeal joint, they prevent the extensor digitorum from hyperextending the joint.

The lumbrical muscles may exhibit considerable variation in their attachments.

Clinical: The lumbricals can be tested clinically by having the patient flex the 4 medial metacarpophalangeal joints against resistance while keeping the interphalangeal joints extended.

Posterior
(dorsal) view



1. Dorsal interosseous muscles

Origin (proximal): The 4 dorsal interosseous muscles are bipennate. They arise by 2 heads from adjacent sides of the metacarpal bones.

Insertion (distal): Each interosseous muscle inserts into the base of the proximal phalanx and into the aponeurosis that forms the extensor expansion of digits 2 through 4.

Action: Abducts the fingers from an imaginary longitudinal line through the middle finger (*arrows*). Also, the dorsal interossei flex the fingers at the metacarpophalangeal joints and aid in extension of the 2 distal phalanges at the interphalangeal joints.

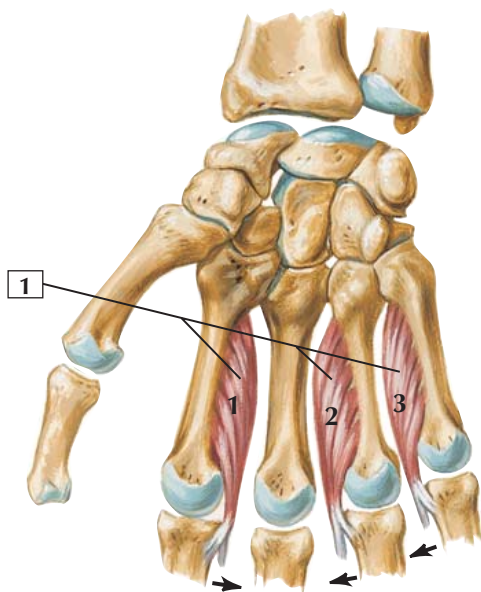
Innervation: Deep palmar branch of the ulnar nerve (C8 and T1).

Comment: The 1st dorsal interosseous is the largest. It fills the space between the metacarpal bones of the thumb and index finger and is sometimes referred to as the “pinch” muscle. The 1st dorsal interosseous also is used with the adductor pollicis muscle during a precision grip.

Dorsal interosseous muscles are not associated with the thumb or little finger; these digits possess their own abductors.

Clinical: The dorsal interossei are clinically tested by holding the adducted extended fingers together and asking the patient to spread the fingers against this resistance.

Anterior
(palmar) view



1. Palmar interosseous muscles

Origin (proximal): The 3 palmar interossei arise from the palmar surfaces of the metacarpal bones of digits 2, 4, and 5.

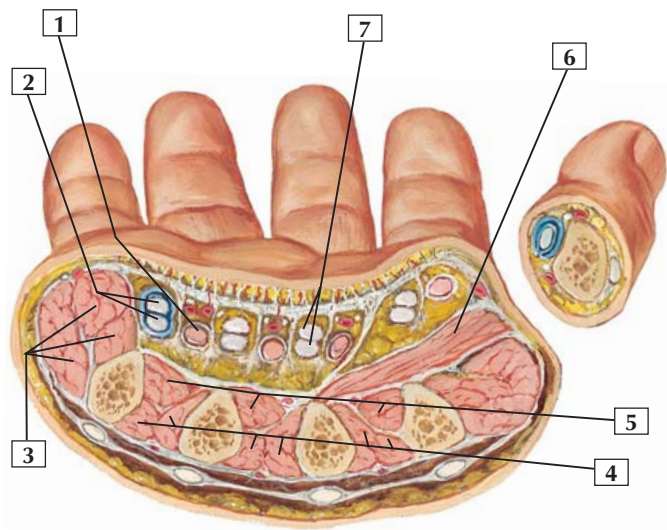
Insertion (distal): Tendons of the palmar interossei insert into the extensor expansions of the digits and bases of the proximal phalanges of digits 2, 4, and 5.

Action: The palmar interossei adduct the fingers at the metacarpophalangeal joint, moving them toward an imaginary line through the axis of the middle finger (*arrows*). They also assist in flexing the proximal phalanx at the metacarpophalangeal joint and aid in extension of the 2 distal phalanges at the interphalangeal joints.

Innervation: Deep branch of the ulnar nerve (C8 and T1).

Comment: The 3 unipennate palmar interossei are smaller than the 4 dorsal interossei.

Clinical: The palmar interossei are tested clinically by placing a sheet of paper between 2 adjacent fingers and, with the patient holding the paper between the adducted fingers, trying to pull the paper away. With weakened adduction, the patient will have difficulty holding the sheet of paper between the fingers.



F. Netter M.D.

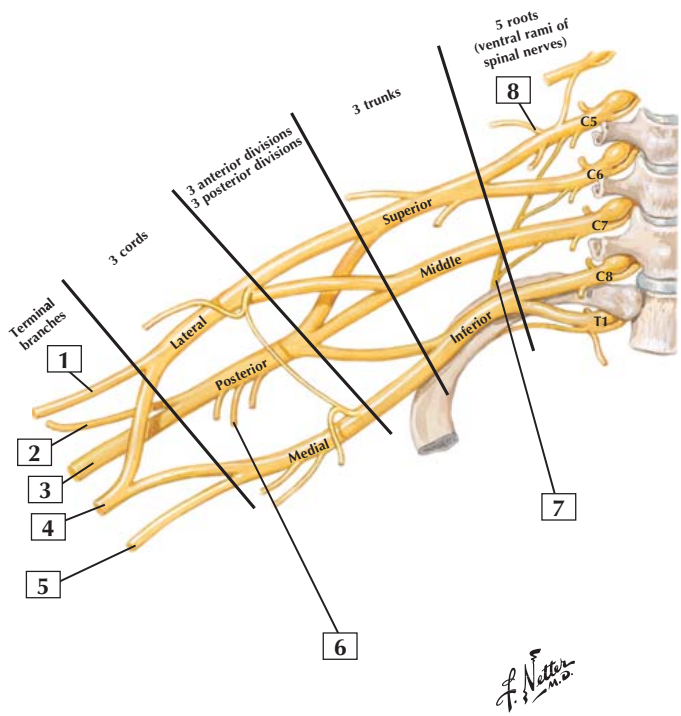
1. Lumbrical muscle in its fascial sheath
2. Flexor tendons to 5th digit in common flexor sheath (ulnar bursa)
3. Hypothenar muscles
4. Dorsal interosseous muscles
5. Palmar interosseous muscles
6. Adductor pollicis muscle
7. Profundus and superficialis flexor tendons to 3rd digit

Comment: Muscles at the base of the thumb compose the thenar cone, or eminence.

Intrinsic muscles at the base of the 5th digit make up the hypothenar eminence.

The palmar interosseous muscles adduct the middle 3 fingers, whereas the dorsal interosseous muscles abduct the middle 3 fingers. Together, the interossei also flex the metacarpophalangeal joint and, because of their insertion into the extensor expansion, extend the proximal and distal interphalangeal joints.

Clinical: Several potential spaces exist in the palm and can become sites of infection. The thenar space exists just anterior to the adductor pollicis muscle. The midpalmar space exists posterior (deep) to the central compartment that contains the long flexor tendons and lumbrical muscles.



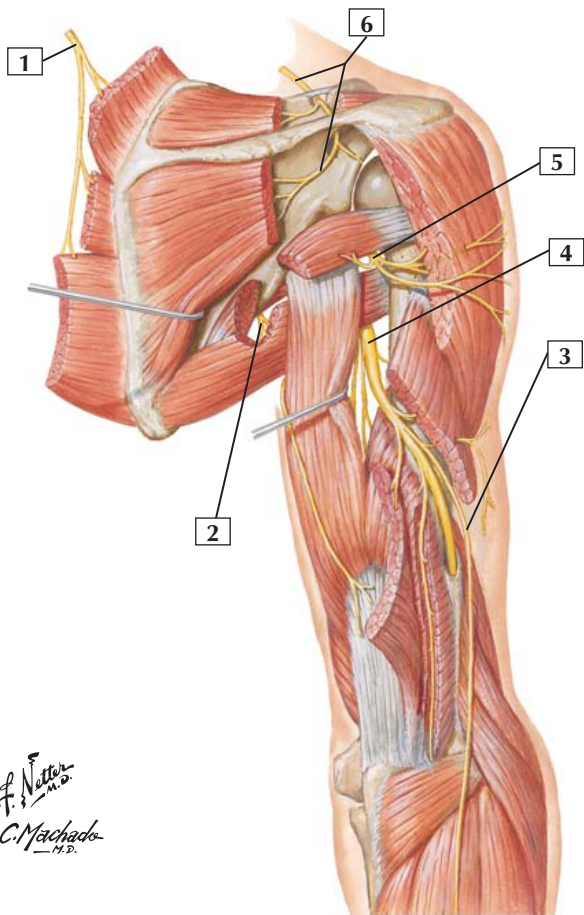
1. Musculocutaneous nerve (C5-7)
2. Axillary nerve (C5-6)
3. Radial nerve (C5-8, T1)
4. Median nerve (C5-8, T1)
5. Ulnar nerve (C7-8, T1)
6. Thoracodorsal (middle subscapular) nerve (C6-8)
7. Long thoracic nerve (C5-7)
8. Dorsal scapular nerve (C5)

Comment: The brachial plexus is formed by the ventral rami of C5-T1 spinal nerves. Its branches supply muscles of the shoulder, including superficial muscles on the back and anterior thoracic wall and all the muscles of the upper extremity.

The 5 roots of the brachial plexus give rise to 3 trunks and to 3 anterior and 3 posterior divisions, which coalesce into 3 cords: the lateral, posterior, and medial cords (named for their relationships to the axillary artery). The 3 cords give rise to 5 terminal branches.

The ventral rami of the spinal nerves that contribute fibers to each of the previously listed branches may vary from individual to individual, so it is wise to use caution in assigning absolute nerve components to each branch. This accounts for the variability seen in textbook descriptions of these nerves.

Clinical: Upper plexus injuries (C5-6) (Erb's palsy) affect largely the muscles of the shoulder and arm and present as an extended elbow and flexed wrist (wristdrop) but a normal grasp. Lower plexus injuries (C7-T1) (Klumpke's palsy) affect primarily muscles of the forearm and hand; the patient has a weak grasp due to the loss of flexion.



F. Netter
M.D.
C. Machado
M.D.

WWW.YAZDANPRESS.COM

Radial Nerve in Arm and Nerves of Posterior Shoulder

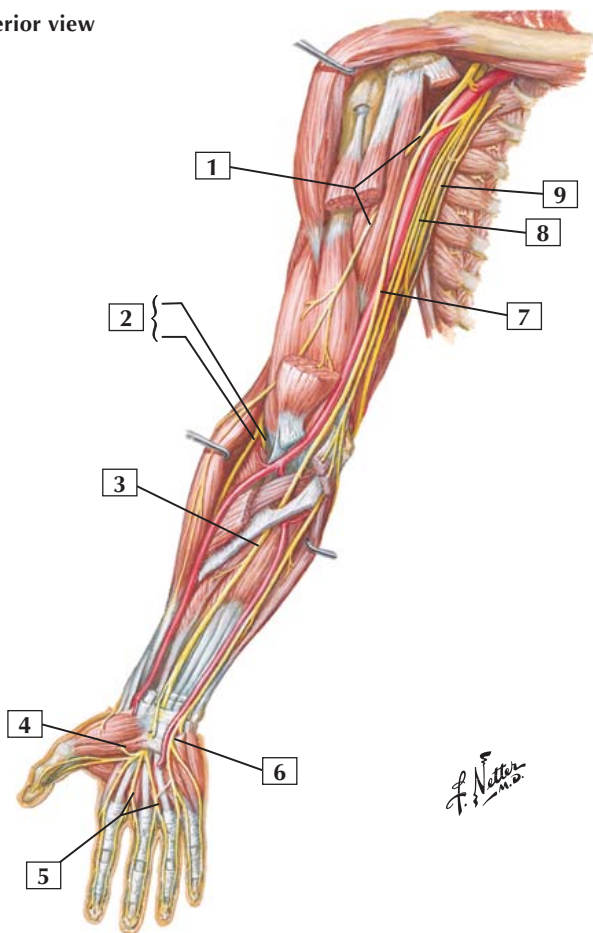
1. Dorsal scapular nerve (C5)
2. Lower subscapular nerve (C5-6)
3. Posterior cutaneous nerve of forearm
4. Radial nerve (C5-8, T1)
5. Axillary nerve (C5-6)
6. Suprascapular nerve (C5-6)

Comment: Branches of the brachial plexus innervate the shoulder and arm muscles. Prominent among these branches are the dorsal scapular nerve, the suprascapular nerve, the lower subscapular nerve, and 2 of the 5 terminal branches of the brachial plexus: the axillary nerve and the radial nerve.

The radial nerve innervates the extensor compartment of the arm and courses posteriorly to the shaft of the humerus, running with the deep brachial artery. In the arm, this nerve innervates the triceps and anconeus muscles.

Clinical: The radial nerve is vulnerable to stretching or tearing in fractures of the shaft of the humerus and can be compressed by tourniquets that are too tight or by direct compression (Saturday night palsy) leading to weakened elbow, wrist and finger extension, and supination. Wristdrop is a common clinical sign if the forearm extensor muscles are affected.

Anterior view



*F. Netter
M.D.*

1. Musculocutaneous nerve
2. Radial nerve (Deep branch; Superficial branch)
3. Median nerve
4. Recurrent (motor) branch of median nerve to thenar muscles
5. Common palmar digital branches of median nerve
6. Superficial branch of ulnar nerve
7. Median nerve
8. Ulnar nerve
9. Radial nerve

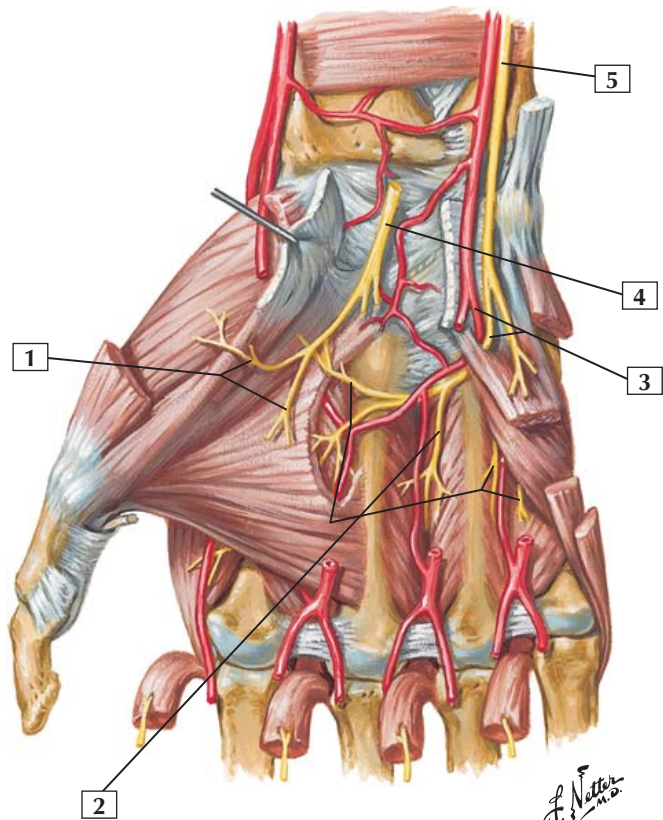
Comment: Nerves of the arm, forearm, and hand are derived from the 5 terminal branches of the brachial plexus. The musculocutaneous nerve innervates the flexors of the elbow, which are contained in the arm's anterior compartment. The radial nerve innervates the arm's posterior compartment, which contains muscles that extend the elbow.

In the forearm, the radial nerve also innervates the extensors of the wrists and digits, and the median nerve innervates most of the flexors of the wrist and digits (although the ulnar nerve innervates $1\frac{1}{2}$ muscles).

The median and ulnar nerves innervate the intrinsic muscles of the hand, although the ulnar nerve predominates (innervates the hypothenar muscles, 2 lumbricals, the adductor pollicis, and all the interossei).

Clinical: Median nerve injury can affect wrist and finger flexion and in particular, the ability to effectively use the thumb, index, and middle fingers. Ulnar nerve injury can present as a claw hand and an inability to effectively use the ring and little fingers, as well as a loss of abduction and adduction of the 2nd to 5th digits.

Anterior (palmar) view



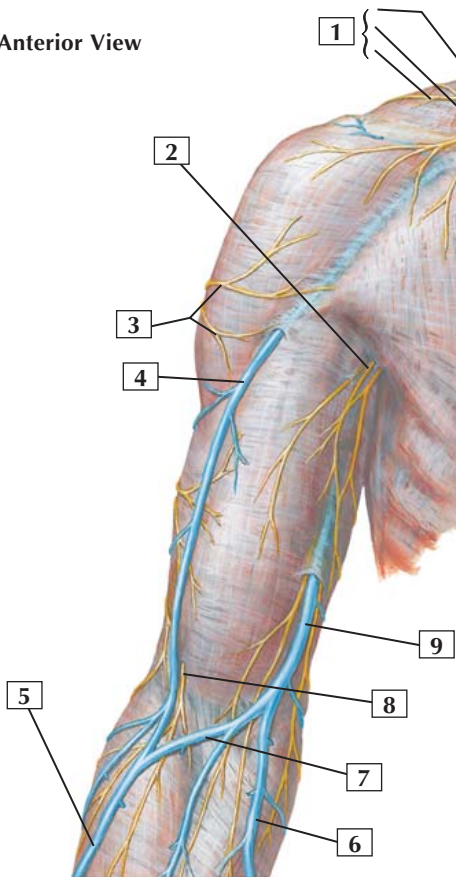
1. Branches of median nerve to thenar muscles and to 1st and 2nd lumbrical muscles
2. Branches from deep branch of ulnar nerve to 3rd and 4th lumbrical muscles and to all interosseous muscles
3. Deep palmar branch of ulnar artery and deep branch of ulnar nerve
4. Median nerve (cut)
5. Ulnar nerve

Comment: The median and ulnar nerves innervate intrinsic muscles on the anterior (palmar) side of the hand. The median nerve innervates muscles that act on the thumb; these muscles form the thenar eminence and lumbricals of digits 2 and 3. All the other intrinsic muscles of the palmar hand are innervated by branches of the ulnar nerve.

Clinical: Sensation of the skin over the surface of the hand can vary depending on the branching of the radial, median, and ulnar sensory branches. Testing of radial sensation can only be done reliably over the dorsal web space between the thumb and index finger. Median sensation is tested reliably on the palmar (volar) aspect of the tip of the index finger. Ulnar sensation is tested reliably on the palmar aspect of the tip of the little finger.

The rich blood supply to the hand via the palmar arches means that lacerations of the palm often bleed profusely and may be difficult to control.

Anterior View



F. Netter
M.D.

WWW.YAZDANPRESS.COM

Cutaneous Nerves and Superficial Veins of Shoulder and Arm

1. Supraclavicular nerves (from cervical plexus) (Medial; Intermediate; Lateral)
2. Medial cutaneous nerve of arm
3. Superior lateral cutaneous nerve of arm (from axillary nerve)
4. Cephalic vein
5. Cephalic vein
6. Basilic vein
7. Median cubital vein
8. Lateral cutaneous nerve of forearm (terminal part of musculocutaneous nerve)
9. Basilic vein

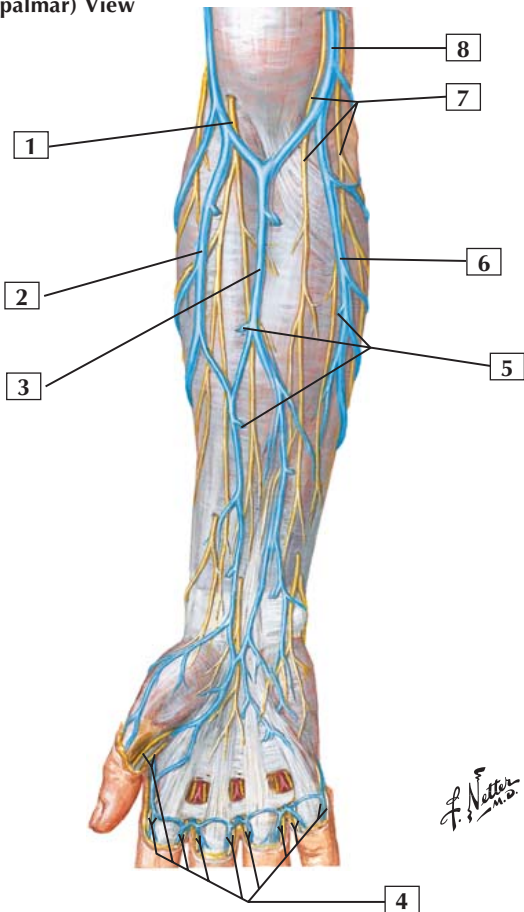
Comment: Cutaneous nerves of the shoulder arise from the supraclavicular nerves of the cervical plexus. Cutaneous nerves of the arm arise from the axillary nerve, from the radial nerve, or directly from the brachial plexus.

The largest superficial veins of the arm are the cephalic vein and the basilic vein. The cephalic vein is joined to the basilic vein by the median cubital vein, which passes anteriorly across the cubital fossa. This vein is commonly used for venipuncture.

Via perforating veins, the superficial veins communicate with deep veins accompanying the brachial artery and its branches. The superficial and deep veins of the upper limb possess valves to assist in returning blood to the heart.

The cephalic vein drains proximally into the axillary vein, and the basilic vein drains proximally into, or becomes continuous with, the axillary vein.

Anterior (palmar) View



WWW.YAZDANPRESS.COM

Cutaneous Nerves and Superficial Veins of Forearm

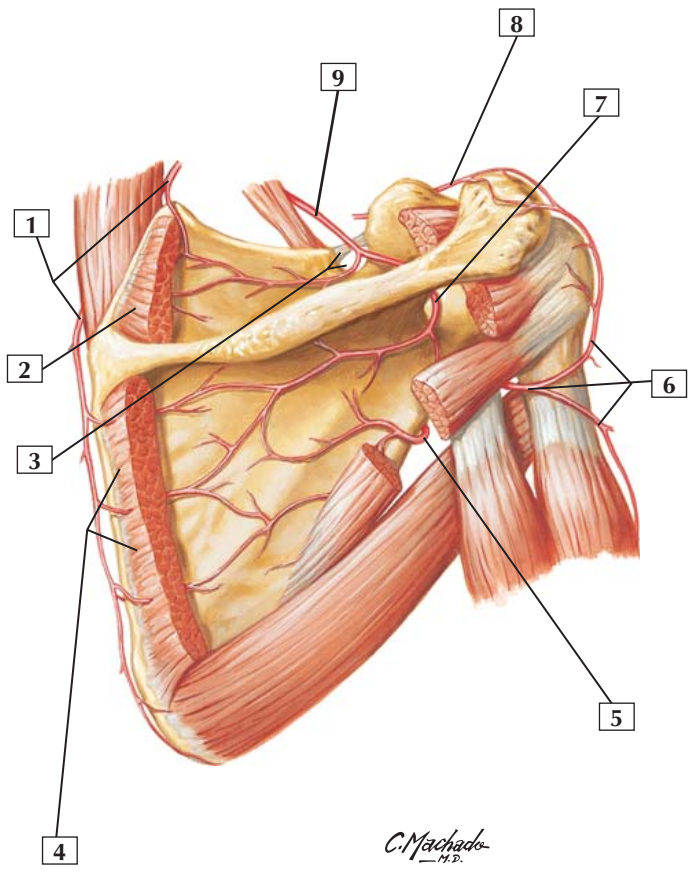
1. Lateral cutaneous nerve of forearm (from musculocutaneous nerve)
2. Cephalic vein
3. Intermediate (median) antebrachial vein
4. Proper palmar digital nerves and palmar digital veins
5. Perforating veins
6. Basilic vein
7. Anterior branch and Posterior branch of medial cutaneous nerve of forearm
8. Basilic vein

Comment: Cutaneous nerves of the forearm arise from the musculocutaneous nerve, from the radial nerve, from the ulnar nerve, or directly from the brachial plexus.

The principal superficial veins of the forearm are the cephalic vein and the basilic vein. These veins communicate in the cubital fossa via the median cubital vein.

Superficial veins communicate with deeper veins via perforating branches. The deeper veins accompany the radial and ulnar arteries and their major branches. The superficial and the deep veins of the upper limb possess valves to assist in returning blood to the heart.

Clinical: The cephalic and basilic veins begin on the dorsum of the hand; because the hand is largely used for grasping objects, the arterial blood from the palmar arches is squeezed from the palm and drains into the dorsal venous plexus and thence into the cephalic and basilic veins. If the veins were on the palm, they would be squeezed shut every time we grasped something!

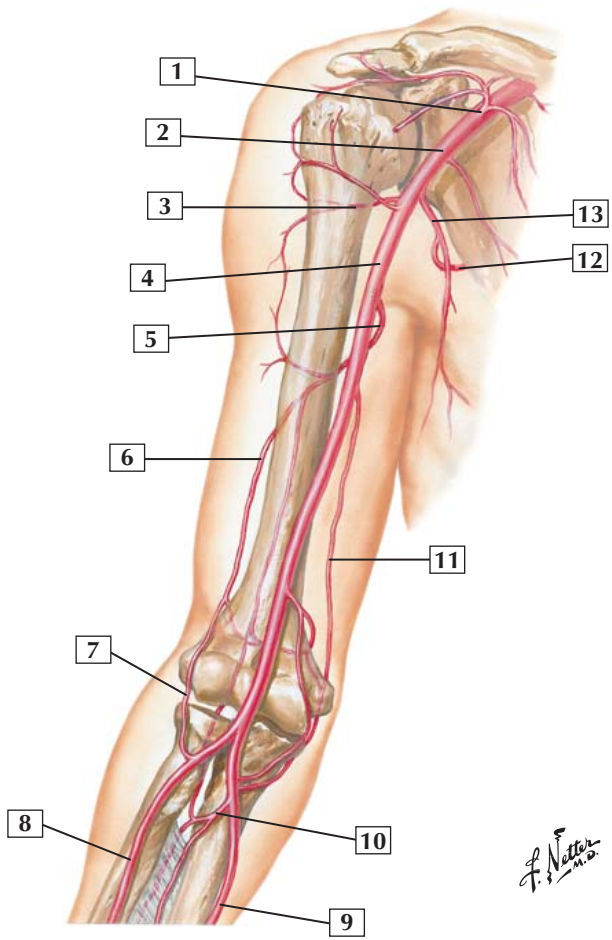


1. Dorsal scapular artery
2. Supraspinatus muscle (cut)
3. Superior transverse scapular ligament and suprascapular notch
4. Infraspinatus muscle (cut)
5. Circumflex scapular artery
6. Posterior humeral circumflex artery (in quadrangular space) and ascending and descending branches
7. Infrapinuous branch of suprascapular artery
8. Acromial branch of thoracoacromial artery
9. Suprascapular artery

Comment: Around the shoulder joint, a rich vascular anastomosis forms from branches of the thyrocervical trunk, thoracoacromial artery, subscapular artery, and posterior and anterior humeral circumflex arteries. This anastomosis not only supplies the 17 muscles attaching to the scapula and some of the shoulder muscles but also provides collateral circulation to the upper limb should the proximal part of the axillary artery become occluded.

The dorsal scapular artery (from the thyrocervical trunk) anastomoses freely across the supraspinous and infrapinuous fossae with branches from the suprascapular, posterior humeral circumflex, and circumflex scapular branch of the subscapular arteries.

Clinical: Joints tend to have rich vascular anastomoses around them to supply the muscles working on that joint and to supply the joint itself. Clinically, these anastomoses can be critical if a proximal artery is lacerated, because adjacent arteries can still supply distal tissues with blood.



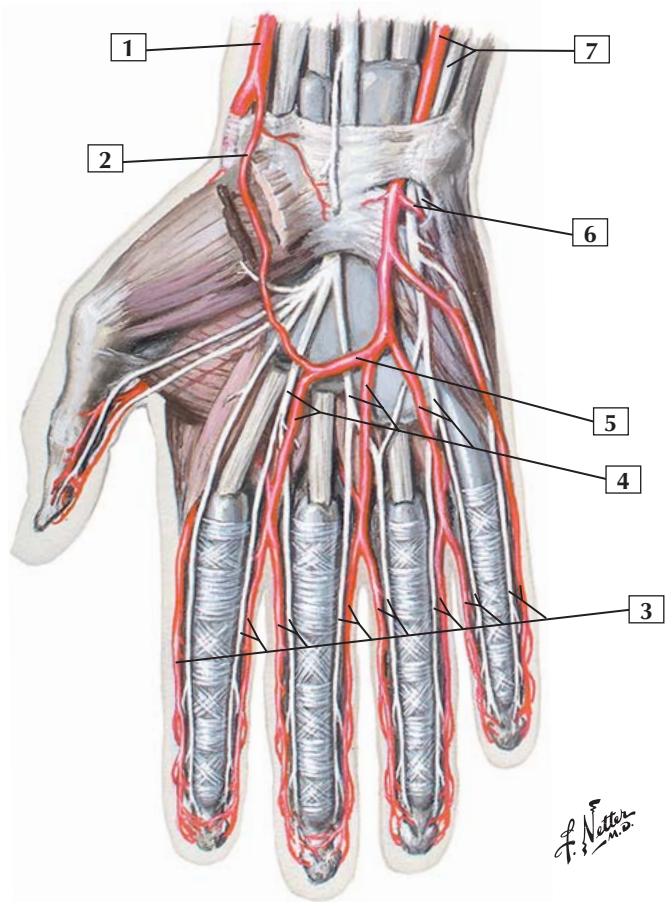
1. Thoracoacromial artery
2. Axillary artery
3. Posterior humeral circumflex artery
4. Brachial artery
5. Deep artery of arm
6. Radial collateral artery
7. Radial recurrent artery
8. Radial artery
9. Ulnar artery
10. Common interosseous artery
11. Superior ulnar collateral artery
12. Circumflex scapular artery
13. Subscapular artery

Comment: The brachial artery is a continuation of the axillary artery; it begins at the lower margin of the teres major muscle. The brachial artery provides a deep branch to the muscles of the posterior compartment of the arm. In the cubital fossa, the brachial artery divides into the radial and ulnar arteries.

The elbow joint is surrounded by a rich anastomosis of radial and ulnar recurrent and collateral arteries.

The radial nerve courses with the deep branch of the brachial artery in the arm. The ulnar nerve courses with the superior ulnar collateral artery. The median nerve courses with the brachial artery.

Clinical: As with the shoulder joint, the elbow joint also possesses a rich vascular anastomosis, providing blood to the muscles acting on the elbow joint and supplying the joint itself.



1. Radial artery
2. Superficial palmar branch of radial artery
3. Proper palmar digital nerves and arteries
4. Common palmar digital nerves and arteries
5. Superficial palmar (arterial) arch
6. Deep palmar branch of ulnar artery and deep branch of ulnar nerve
7. Ulnar artery and nerve

Comment: The superficial palmar arch is a continuation of the ulnar artery. It anastomoses with the superficial palmar branch of the radial artery. From this superficial arch arise common palmar digital arteries, which divide into proper palmar digital arteries.

A deep palmar arch exists deeper within the palm. It is the terminal part of the radial artery, and it anastomoses with the deep palmar branch of the ulnar artery. Perforating branches join the superficial and deep palmar arches.

Clinical: Allen's test is used to test the vascular perfusion distal to the wrist. The examiner's thumbs are placed lightly on the patient's ulnar and radial arteries as the patient makes a tight fist to "blanch" the palmar skin. Then, compressing the radial artery with the thumb, the examiner releases the pressure on the ulnar artery and asks the patient to open the clenched fist. Normally, the skin should turn pink immediately, indicating normal ulnar artery blood flow through the anastomotic palmar arches. Then, the test is repeated by occluding the ulnar artery to assess radial artery flow.

Bones and Joints

- 7-1** Hip (Coxal) Bone: Lateral View
- 7-2** Hip (Coxal) Bone: Medial View
- 7-3** Hip Joint: Lateral View
- 7-4** Hip Joint: Anterior and Posterior Views
- 7-5** Femur
- 7-6** Tibia and Fibula
- 7-7** Knee: Cruciate and Collateral Ligaments
- 7-8** Knee: Interior (Superior View)
- 7-9** Knee: Interior (Inferior View)
- 7-10** Bones of Foot
- 7-11** Ligaments and Tendons of Ankle: Lateral View
- 7-12** Ligaments and Tendons of Ankle: Medial View
- 7-13** Ligaments and Tendons of Foot: Plantar View

Muscles

- 7-14** Psoas Major
- 7-15** Iliacus Muscle
- 7-16** Tensor Fasciae Latae
- 7-17** Sartorius
- 7-18** Rectus Femoris
- 7-19** Vastus Lateralis
- 7-20** Vastus Intermedius
- 7-21** Vastus Medialis
- 7-22** Pectineus



- 7-23** Adductor Longus
- 7-24** Adductor Brevis
- 7-25** Obturator Externus
- 7-26** Adductor Magnus
- 7-27** Gracilis
- 7-28** Gluteus Maximus
- 7-29** Gluteus Medius
- 7-30** Gluteus Minimus
- 7-31** Piriformis
- 7-32** Superior Gemellus and Inferior Gemellus
- 7-33** Obturator Internus
- 7-34** Quadratus Femoris
- 7-35** Semitendinosus
- 7-36** Semimembranosus
- 7-37** Biceps Femoris: Short Head and Long Head
- 7-38** Thigh Muscles
- 7-39** Fibularis (Peroneus) Longus
- 7-40** Fibularis (Peroneus) Brevis
- 7-41** Tibialis Anterior
- 7-42** Extensor Hallucis Longus
- 7-43** Extensor Digitorum Longus
- 7-44** Gastrocnemius
- 7-45** Soleus
- 7-46** Plantaris
- 7-47** Popliteus

- 7-48** Flexor Hallucis Longus
- 7-49** Flexor Digitorum Longus
- 7-50** Tibialis Posterior
- 7-51** Leg: Cross Section
- 7-52** Abductor Hallucis
- 7-53** Flexor Digitorum Brevis
- 7-54** Abductor Digiti Minimi
- 7-55** Flexor Hallucis Brevis
- 7-56** Quadratus Plantae
- 7-57** Flexor Digiti Minimi Brevis
- 7-58** Lumbrical Muscles
- 7-59** Adductor Hallucis (Transverse and Oblique Heads)
- 7-60** Dorsal Interosseous Muscles
- 7-61** Plantar Interosseous Muscles

Nerves

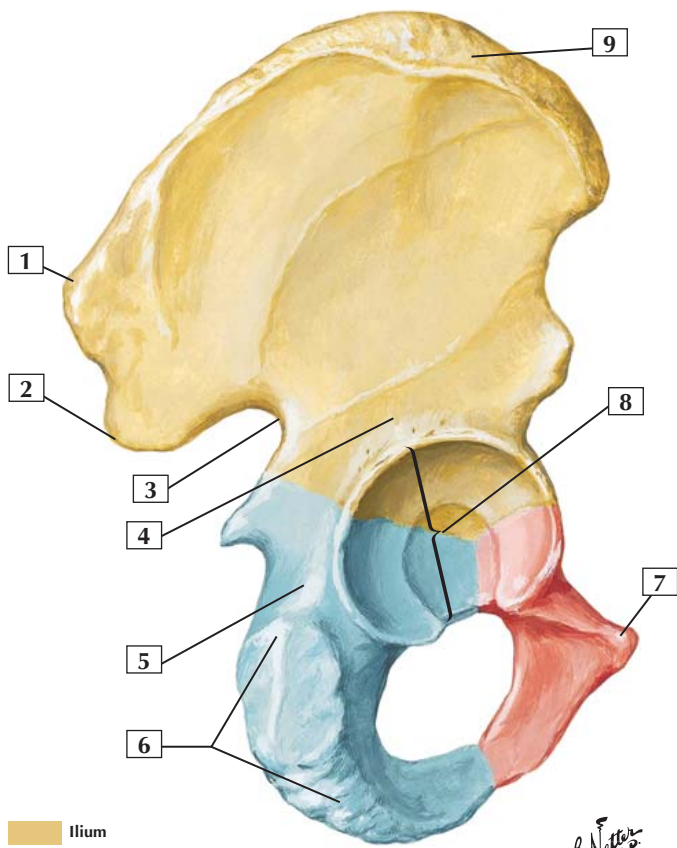
- 7-62** Lumbar Plexus
- 7-63** Nerves of Gluteal Region and Thigh: Posterior View
- 7-64** Common Fibular (Peroneal) Nerve
- 7-65** Tibial Nerve

Vessels

- 7-66** Superficial Nerves and Veins of Lower Limb: Anterior View



- 7-67** Superficial Nerves and Veins of Lower Limb:
Posterior View
- 7-68** Arteries of Thigh and Knee: Schema
- 7-69** Arteries of Leg: Anterior View
- 7-70** Arteries of Leg: Posterior View
- 7-71** Arteries of Sole of Foot



- Ilium
- Ischium
- Pubis

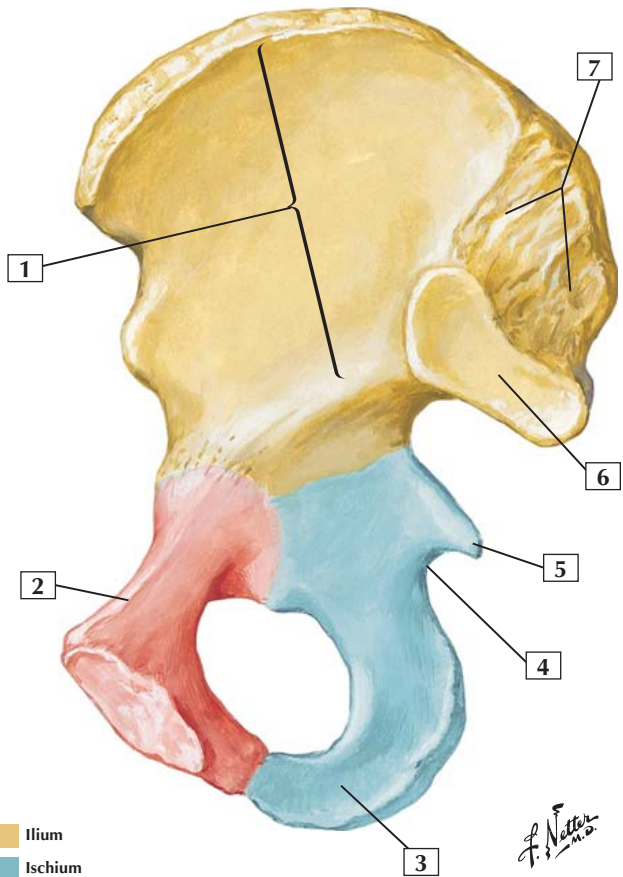
F. Netter M.D.

1. Posterior superior iliac spine
2. Posterior inferior iliac spine
3. Greater sciatic notch
4. Body of ilium
5. Body of ischium
6. Ischial tuberosity
7. Pubic tubercle
8. Acetabulum
9. Iliac crest

Comment: The hip bone consists of 3 bones: the ilium, ischium, and pubis. Before puberty, these bones are joined by cartilage, but they begin to fuse by mid adolescence and are completely fused in adulthood. All 3 fused bones contribute to the acetabulum, the cup-like cavity for articulation of the head of the femur.

The fused hip bone articulates with the femur (thigh bone) and with the vertebral column (spine). Specifically, the ilium articulates with the sacrum in a plane synovial joint that allows for little movement, in contrast to the shoulder joint, and provides great stability. This stability is important for standing, walking, and running on 2 legs (bipedalism).

Clinical: Bruising over the iliac crest, often from an athletic injury or direct trauma, is commonly referred to as a hip pointer.



- Ilium
- Ischium
- Pubis

F. Netter M.D.

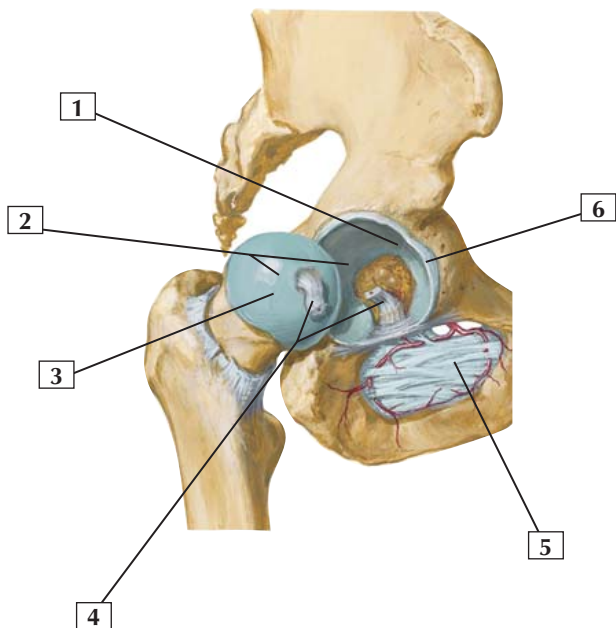
1. Wing (ala) of ilium (iliac fossa)
2. Pecten pubis (pectineal line)
3. Ramus of ischium
4. Lesser sciatic notch
5. Ischial spine
6. Articular surface (for sacrum)
7. Iliac tuberosity

Comment: The hip bone consists of 3 bones: the ilium, ischium, and pubis. Before puberty, these bones are joined by cartilage, but they begin to fuse by mid adolescence and are completely fused in adulthood.

Anteriorly, the two pubic bones articulate with one another at the pubic symphysis. A fibrocartilage disc separates the 2 bones, and this joint allows some movement.

Clinical: Forensic scientists can identify the pelvic bones of females from males by the structural adaptations observed in the pelvis for childbirth. The female pelvis is usually smaller, lighter, and thinner than its male counterpart. In females the pelvic inlet is oval and the outlet is larger, the pelvic cavity is wider and shallower, and the pubic arch is wider. The obturator foramen is usually oval or triangular in the female and round in the male.

Joint opened:
lateral view



*F. Netter
M.D.*

1. Lunate (articular) surface of acetabulum
2. Articular cartilage
3. Head of femur
4. Ligament of head of femur (cut)
5. Obturator membrane
6. Acetabular labrum (fibrocartilaginous)

Comment: The hip joint is a multiaxial ball-and-socket synovial joint between the acetabulum and the head of the femur. The acetabular labrum deepens the acetabular cavity even farther, and the fibrous joint capsule is reinforced by 3 ligaments. Within the acetabulum, the ligament of the head of the femur attaches to the femoral head and provides a pathway for a small artery derived from the obturator.

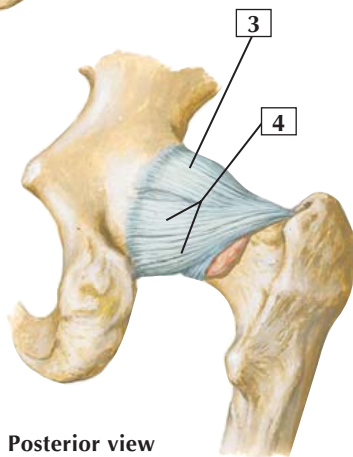
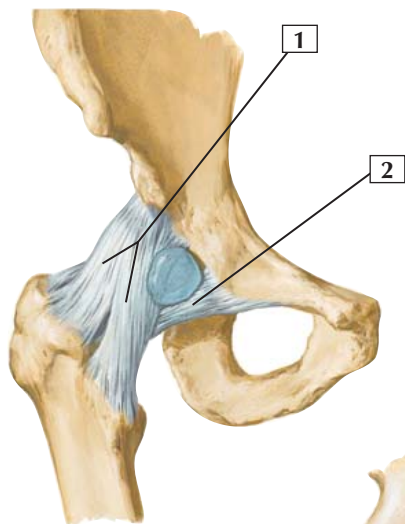
The hip participates in abduction and adduction, flexion and extension, and rotation and circumduction.

The ligament of the head of the femur contains the acetabular branch (artery of the round ligament of the femoral head) that arises from the obturator artery.

Blood is supplied to the hip by branches of the medial and lateral femoral circumflex arteries, the gluteal arteries, and the obturator.

Clinical: About 1.5 in 1000 infants are born with a congenital hip dislocation, which affects girls more than boys.

Anterior view



F. Netter M.D.

Posterior view

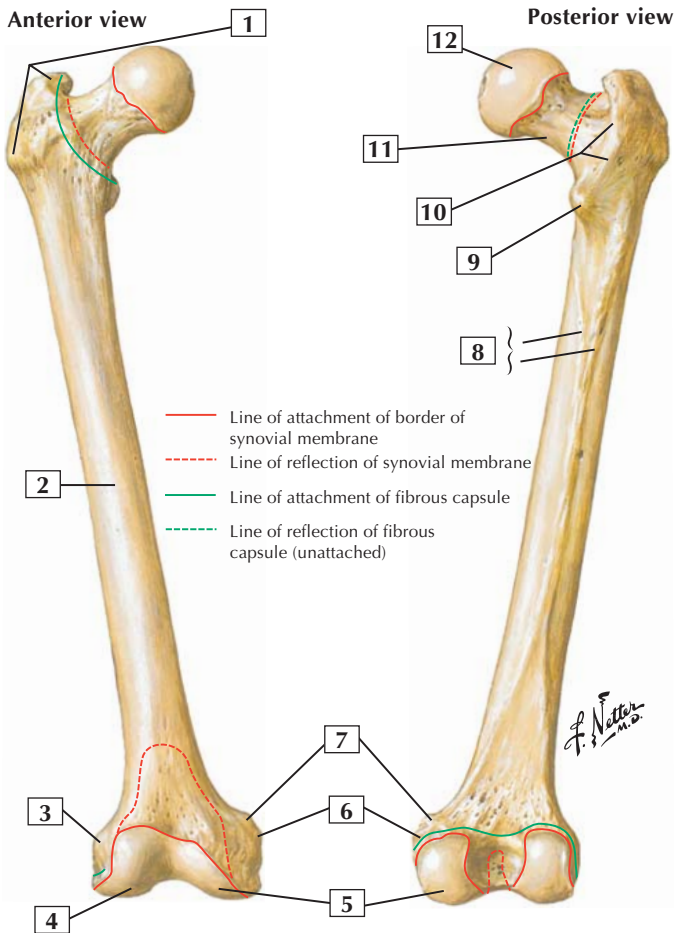
1. Iliofemoral ligament (Y ligament of Bigelow)
2. Pubofemoral ligament
3. Iliofemoral ligament
4. Ischiofemoral ligament

Comment: The hip joint is a multiaxial ball-and-socket synovial joint between the acetabulum and the head of the femur. The acetabular labrum deepens the acetabular cavity even farther, and the fibrous joint capsule is reinforced by 3 ligaments.

The iliofemoral ligament is the most important ligament reinforcing the hip joint. This ligament forms an inverted Y ligament (of Bigelow) that limits hyperextension and lateral rotation. The pubofemoral ligament limits extension and abduction, whereas the ischiofemoral ligament limits extension and medial rotation. If one notices where these ligaments attach, one can understand how they limit movement in a certain direction.

The hip participates in abduction and adduction, flexion and extension, and rotation and circumduction.

Clinical: The iliofemoral ligament is the strongest of the hip ligaments, and the ischiofemoral is the weakest of the 3 ligaments.



1. Greater trochanter
2. Shaft (body)
3. Lateral epicondyle
4. Lateral condyle
5. Medial condyle
6. Medial epicondyle
7. Adductor tubercle
8. Linea aspera (Medial lip; Lateral lip)
9. Lesser trochanter
10. Intertrochanteric crest
11. Neck
12. Head

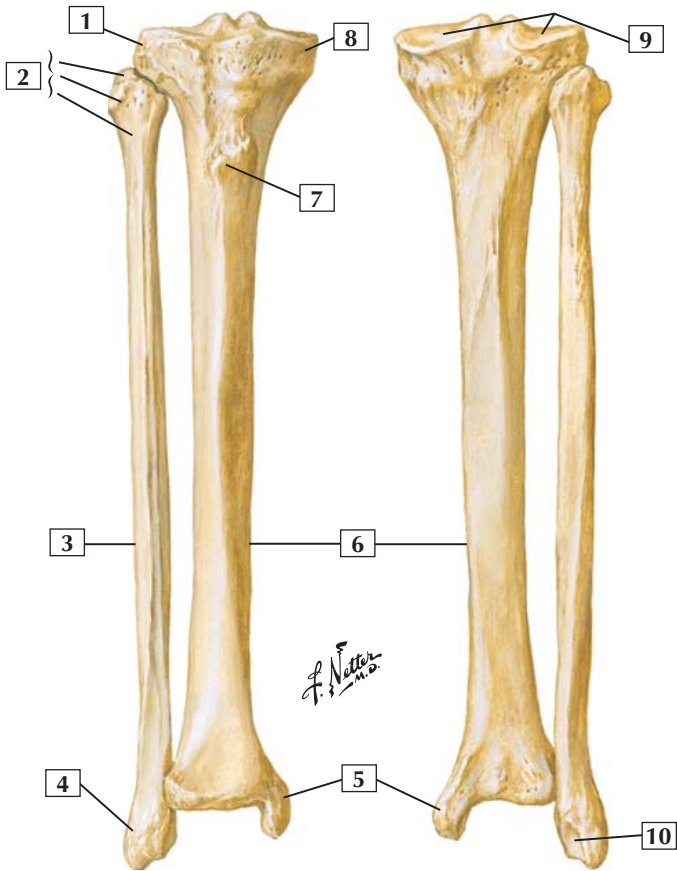
Comment: The femur, or thigh bone, is the longest bone in the body. When a person is standing, the femur transmits the weight of the body from the hip to the tibia.

The head of the femur articulates with the coxal (hip) bone at the acetabulum. The femoral neck is a common fracture site. The greater trochanter is the point of the hip and an attachment site for several of the gluteal muscles (abductors of the thigh at the hip). The lesser trochanter is an attachment site for the iliopsoas tendon, a strong flexor of the thigh at the hip.

Clinical: Femoral neck fractures are common and often occur in the young from trauma and in the elderly from osteoporosis and an associated fall. Complications are related to nonunion of the bone and avascular necrosis of the femoral head.

Anterior view

Posterior view



1. Lateral condyle
2. Apex, Head, and Neck of fibula
3. Fibula
4. Lateral malleolus
5. Medial malleolus
6. Tibia
7. Tibial tuberosity
8. Medial condyle
9. Superior articular surfaces (medial and lateral facets)
10. Malleolar fossa of lateral malleolus

Comment: The tibia articulates with the condyles of the femur and is the weight-bearing bone of the leg.

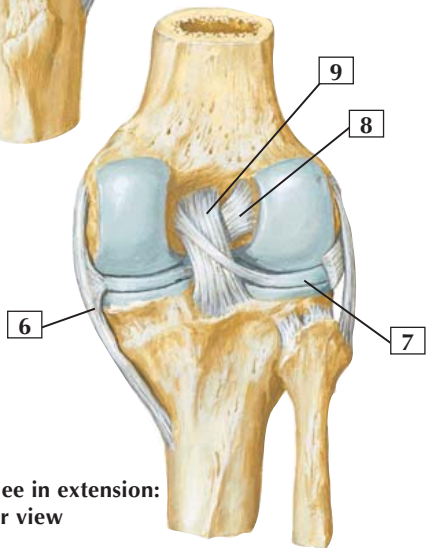
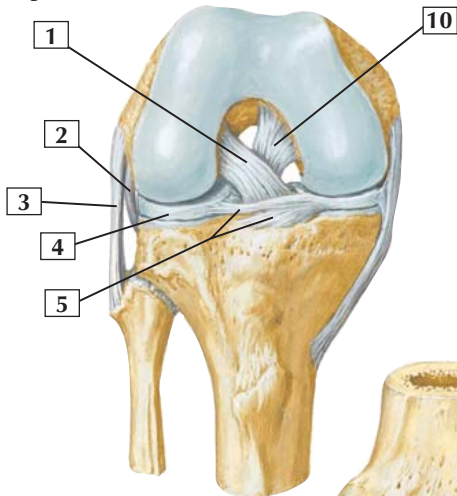
The smaller fibula lies posterolateral to the tibia. It exists largely for muscle attachment.

The tibial tuberosity is the insertion site for the patellar ligament (tendon of attachment for the quadriceps muscles of the anterior thigh that extend the leg at the knee joint).

The proximal tibiofibular joint is a plane synovial joint that permits limited gliding movement. The distal tibiofibular joint is a fibrous joint (syndesmosis), which allows almost no movement.

Clinical: Fractures of the tibial shaft are the most common fractures of a long bone. Because the tibia lies just beneath the skin along the medial border of the leg, these fractures often are open injuries (skin perforated).

Right knee in flexion: anterior view



Right knee in extension:
posterior view

*F. Netter
M.D.*

1. Anterior cruciate ligament
2. Popliteus tendon
3. Fibular collateral ligament
4. Lateral meniscus
5. Transverse ligament of knee
6. Tibial collateral ligament
7. Lateral meniscus
8. Anterior cruciate ligament
9. Posterior cruciate ligament
10. Posterior cruciate ligament

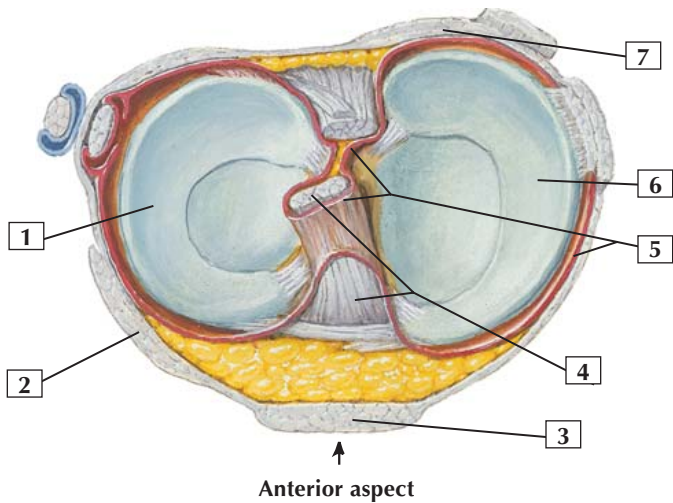
Comment: The knee is the largest and most complicated joint in the body. It is a biaxial condylar synovial joint between the condyles of the femur and tibia. It also includes a saddle joint between the femur and patella.

The knee participates in flexion and extension. When flexed, it also participates in some gliding and rotation movement. When the knee extends fully, the femur rotates slightly and medially on the tibia, pulling each of the ligaments taut and stabilizing the joint.

The menisci, the cruciate ligaments, and the transverse ligament are intracapsular ligaments. The transverse ligament binds and stabilizes the menisci.

Most of the blood supply to the knee is from genicular branches of the popliteal artery.

Clinical: The posterior cruciate ligament is shorter and stronger than the anterior cruciate; consequently, it is not torn nearly as often as the anterior cruciate ligament.



F. Netter M.D.

Knee: Interior (Superior View)

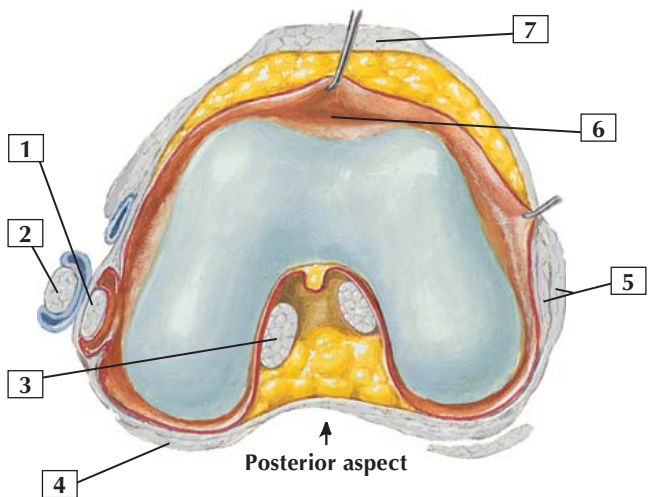
1. Lateral meniscus
2. Iliotibial tract blended into capsule
3. Patellar ligament
4. Anterior cruciate ligament
5. Synovial membrane
6. Medial meniscus
7. Oblique popliteal ligament

Comment: The knee is surrounded by a thin, fibrous capsule that is stabilized by the surrounding muscle attachments and intracapsular and extracapsular ligaments. Intracapsular ligaments include the anterior and posterior cruciate ligaments, medial and lateral menisci, and transverse ligament. Extracapsular ligaments include the medial and lateral collateral ligaments, patellar ligament, and arcuate and oblique popliteal ligaments.

Of the 2 cruciate ligaments, the anterior is the weaker and is taut when the knee is fully extended, preventing hyperextension. The posterior cruciate tightens during flexion of the knee, preventing excessive anterior displacement of the femur on the tibia or excessive posterior displacement of the tibia on the femur.

The tibial collateral ligament limits extension and abduction of the leg and is attached to the medial meniscus. The fibular collateral ligament limits extension and adduction of the leg.

Clinical: Rupture of the tibial collateral ligament, which is attached to the medial meniscus, also may tear the medial meniscus. The medial meniscus also is larger than the lateral meniscus.



*F. Netter
M.D.*

Knee: Interior (Inferior View)

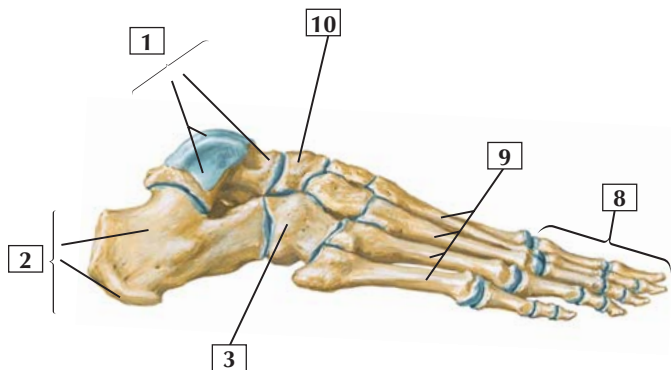
1. Popliteus tendon
2. Fibular collateral ligament
3. Anterior cruciate ligament
4. Arcuate popliteal ligament
5. Tibial collateral ligament (superficial and deep parts)
6. Suprapatellar synovial bursa
7. Patellar ligament

Comment: The knee is surrounded by a thin, fibrous capsule that is stabilized by the surrounding muscle attachments and intracapsular and extracapsular ligaments. Intracapsular ligaments include the anterior and posterior cruciate ligaments, medial and lateral menisci, and transverse ligament. Extracapsular ligaments include the medial and lateral collateral ligaments, patellar ligament, and arcuate and oblique popliteal ligaments.

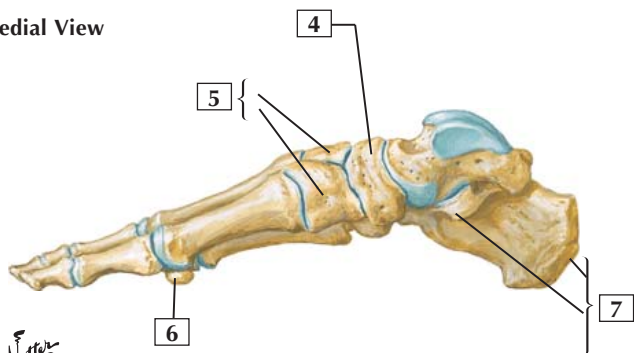
Of the 2 cruciate ligaments, the anterior is the weaker and is taut when the knee is fully extended, preventing hyperextension. The posterior cruciate tightens during flexion of the knee, preventing excessive anterior displacement of the femur on the tibia or excessive posterior displacement of the tibia on the femur.

Clinical: Rupture of the anterior cruciate ligament is a common athletic injury usually associated with a sharp turn, when the knee is twisted while the foot is firmly on the ground. The anterior drawer test assesses this injury. With an anterior cruciate ligament injury, the tibia moves anteriorly more than 5 mm, indicating a positive result. The anterior cruciate ligament normally limits knee hyperextension.

Lateral View



Medial View



F. Netter M.D.

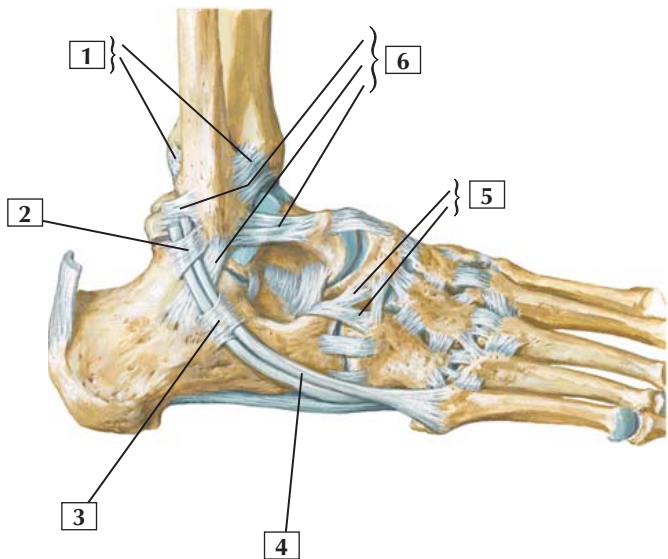
1. Talus (Head; Trochlea)
2. Calcaneus (Body; Tuberosity)
3. Cuboid
4. Navicular
5. Cuneiform bones
6. Sesamoid bone
7. Calcaneus (Tuberosity; Sustentaculum tali)
8. Phalanges
9. Metatarsal bones
10. Navicular

Comment: The bones of the foot include the 7 tarsal bones, of which only the talus articulates with the leg bones. Five metatarsal bones articulate proximally with the tarsals and distally with the phalanges. Similar to the thumb, the 1st toe (big toe) has only 2 phalanges. Toes 2 through 5 have a proximal, middle, and distal phalanx.

The trochlea of the talus (ankle bone) articulates with the tibia and fibula, and the head of the talus articulates with the navicular bone. The calcaneus (heel bone) articulates with the talus superiorly and the cuboid anteriorly.

Clinical: The calcaneus is the most commonly fractured tarsal bone. Most calcaneal fractures occur from a forceful landing on a heel, in which the talus is driven down into the calcaneus. The bone density of the calcaneus is less than that of the talus, which also contributes to its being fractured.

Right foot: lateral view



*F. Netter
M.D.*

Ligaments and Tendons of Ankle: Lateral View

1. Anterior and Posterior tibiofibular ligaments
2. Superior fibular (peroneal) retinaculum
3. Inferior fibular (peroneal) retinaculum
4. Fibularis (peroneus) brevis tendon
5. Bifurcate ligament (Calcaneonavicular ligament; Calcaneocuboid ligament)
6. Components of lateral (collateral) ligament of ankle (Posterior talofibular ligament; Calcaneofibular ligament; Anterior talofibular ligament)

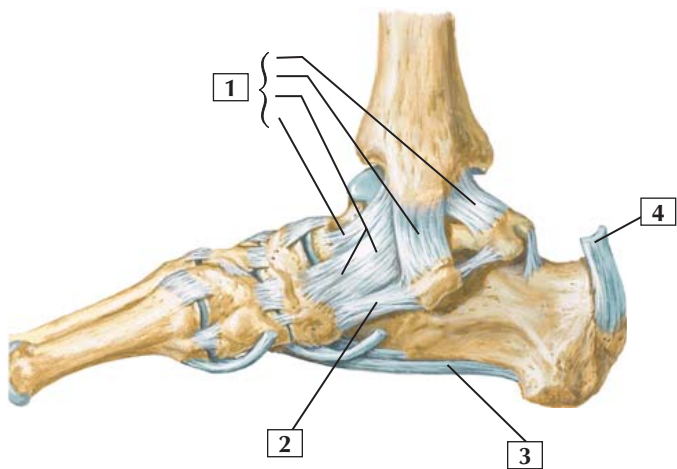
Comment: The ankle (talocrural) joint is a hinge-type (ginglymus) uniaxial synovial joint between the tibia/fibula and the trochlea of the talus. This joint permits dorsiflexion (extension) and plantarflexion. Its thin, fibrous capsule is reinforced by the medial (deltoid) ligament, which has 4 parts, and the lateral collateral ligament, which has 3 parts.

Of the tarsal joints, the talocalcaneal (subtalar) joint is a plane synovial joint between the talus and calcaneus. It permits inversion and eversion of the foot.

The talocalcaneonavicular joint is a partial ball-and-socket synovial joint between the head of the talus and the calcaneus and navicular bones (along with the calcaneocuboid joint, it forms the transverse tarsal joint). It is supported by the spring ligament and is important in gliding and rotational movements of the foot.

Clinical: The lateral collateral ligament is weak and often is sprained. It resists inversion of the foot. One or more of its parts may tear in the common inversion ankle injury; when this happens, the ligaments usually tear from anterior to posterior with the anterior talofibular ligament being torn first.

Right foot: medial view



*F. Netter
M.D.*

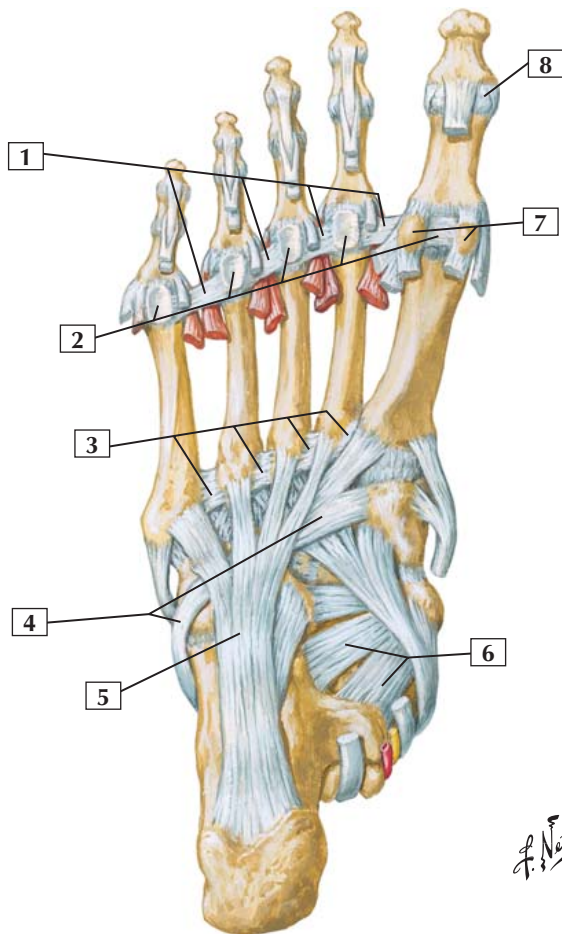
Ligaments and Tendons of Ankle: Medial View

1. Medial (deltoid) ligament of ankle (Posterior tibiotalar part; Tibiocalcaneal part; Tibionavicular part; Anterior tibiotalar part)
2. Plantar calcaneonavicular (spring) ligament
3. Long plantar ligament
4. Calcaneal (Achilles) tendon (cut)

Comment: The ankle (talocrural) joint is a hinge-type (ginglymus) uniaxial synovial joint between the tibia/fibula and the trochlea of the talus. This joint permits dorsiflexion (extension) and plantarflexion. Its thin, fibrous capsule is reinforced by the medial (deltoid) ligament, which has 4 parts, and the lateral collateral ligament, which has 3 parts.

The medial (deltoid) ligament has 4 parts and limits eversion of the foot. This ligament helps maintain the medial long arch of the foot, whereas the plantar calcaneonavicular (spring) ligament provides strong plantar support for the head of the talus (which maintains the arch of the foot).

Clinical: Many ankle injuries are caused by twisting, so that the talus rotates in a frontal plane and impinges on either the lateral or medial malleolus. This movement causes a fracture of the malleolus and places tension on the supporting ligaments of the opposite side.



F. Netter M.D.

Ligaments and Tendons of Foot: Plantar View

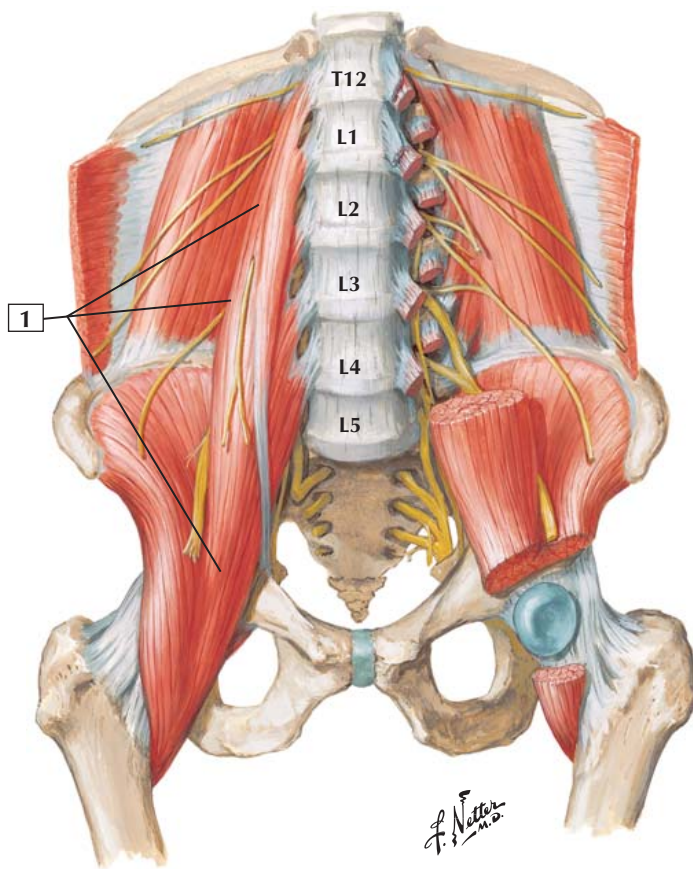
1. Deep transverse metatarsal ligaments
2. Plantar ligaments (plates)
3. Plantar metatarsal ligaments
4. Fibularis (peroneus) longus tendon
5. Long plantar ligament
6. Plantar calcaneonavicular (spring) ligament
7. Sesamoid bones
8. Interphalangeal joint

Comment: The tarsometatarsal joints are plane synovial joints. They consist of articular capsules and are strengthened by plantar, dorsal, and interosseous ligaments. They permit gliding and sliding movements.

The metatarsophalangeal joints are multiaxial condyloid synovial joints surrounded by articular capsules and strengthened by plantar and collateral ligaments. They permit flexion and extension, some abduction and adduction, and circumduction. The plantar (plate) ligaments are part of the weight-bearing surface of the foot.

The interphalangeal joints are uniaxial hinge-type (ginglymus) synovial joints that also are enclosed by capsules and strengthened by plantar and collateral ligaments. They permit flexion and extension.

Clinical: Direct trauma to the foot can result in fracture of the metatarsals and phalanges. These are usually treated by immobilization, because the fragments are often not displaced owing to the extensive ligament attachments that stabilize these joints.



1. Psoas major

Origin (proximal): Arises from the transverse processes of all 5 lumbar vertebrae and from the sides of T12-L5 vertebrae and the intervertebral discs between them.

Insertion (distal): Tapers inferiorly, crossing in front of the sacrum and sacroiliac joint to join with the iliacus muscle and to insert on the lesser trochanter of the femur.

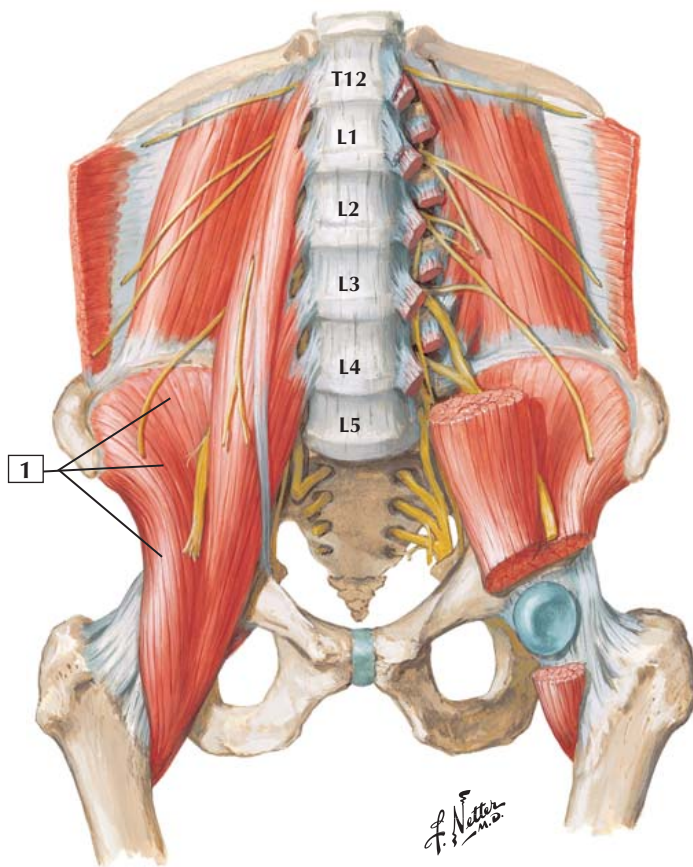
Action: With the iliacus, the psoas major flexes the thigh at the hip and is an important flexor of the trunk at the hip. Acting alone, it laterally flexes the trunk ipsilaterally.

Innervation: Ventral rami of lumbar nerves L1-3.

Comment: The psoas major and iliacus muscle are commonly referred to as the iliopsoas muscle because they act in unison. Their action is especially important in flexing the trunk against gravity, as when a person does sit-ups with the legs straight (hips extended).

About half the population has a smaller muscle, the psoas minor, on the anterior surface of the psoas major.

Clinical: The psoas major (iliopsoas complex) is tested clinically by having the patient flex the thigh at the hip joint against resistance (with the leg also flexed at the knee).



Iliacus Muscle

1. Iliacus muscle

Origin (proximal): The fan-shaped iliacus arises from the inner surface of the wing of the ilium (iliac fossa).

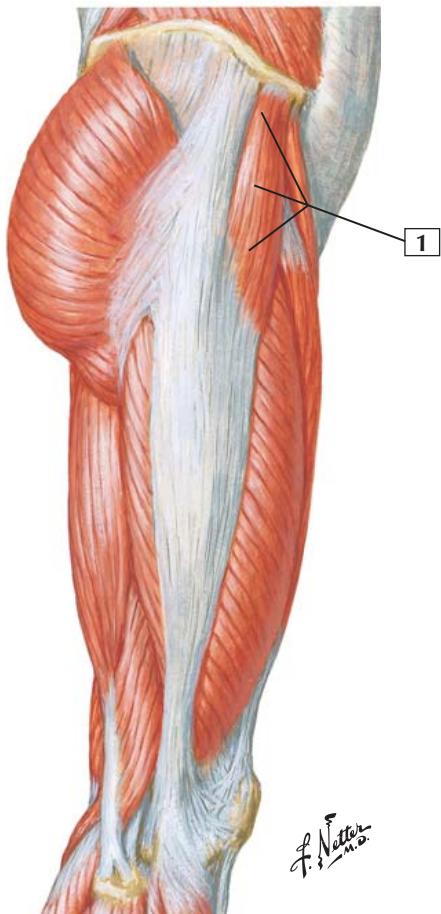
Insertion (distal): The iliacus fibers blend with those of the psoas major and insert on the lesser trochanter of the femur.

Action: The iliacus acts in unison with the psoas major muscle. The 2 muscles are often called the iliopsoas muscle. The iliopsoas flexes the thigh at the hip and is an important flexor of the trunk.

Innervation: Femoral nerve (L2, L3, and L4).

Comment: The iliacus is innervated by branches derived from the femoral nerve as this larger nerve descends to pass into the thigh.

Clinical: The iliacus muscle (iliopsoas complex) is tested clinically by having the patient flex the thigh at the hip joint against resistance (with the leg also flexed at the knee).



1. Tensor fasciae latae

Origin (proximal): Arises from the anterior superior iliac spine and the anterior portion of the iliac crest.

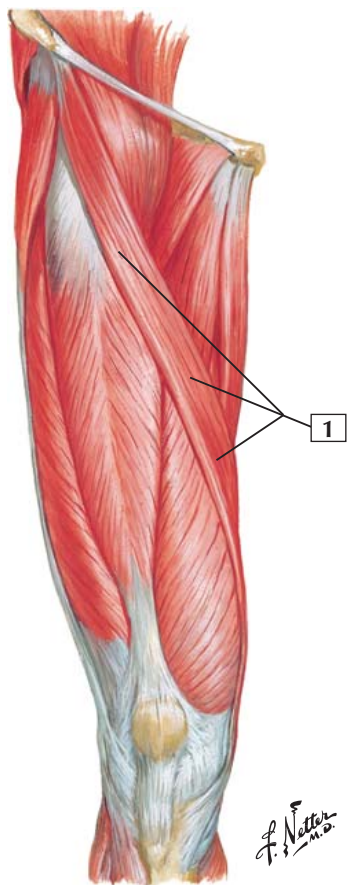
Insertion (distal): As its name suggests, this muscle inserts into the iliotibial tract. This strong tendinous tract inserts on the lateral condyle of the tibia.

Action: This muscle flexes, abducts, and medially rotates the thigh at the hip. With the assistance of the gluteus maximus, this muscle stabilizes the hip joint. The tensor fasciae latae also stabilizes the extended knee.

Innervation: Superior gluteal nerve (L4 and L5).

Comment: The chief action of the tensor fasciae latae is hip flexion. It also acts with the gluteus maximus to control anteroposterior tilting of the pelvis when one leg supports all of the body's weight. Stabilization of the hip occurs because it holds the femoral head in the acetabulum. The tensor fasciae latae also stabilizes the knee in extension.

Clinical: This muscle helps flex the thigh at the hip, assisting the iliopsoas complex and rectus femoris muscle. If the iliopsoas complex is paralyzed, the tensor fasciae latae can hypertrophy to compensate.



1. Sartorius

Origin (proximal): Arises from the anterior superior iliac spine.

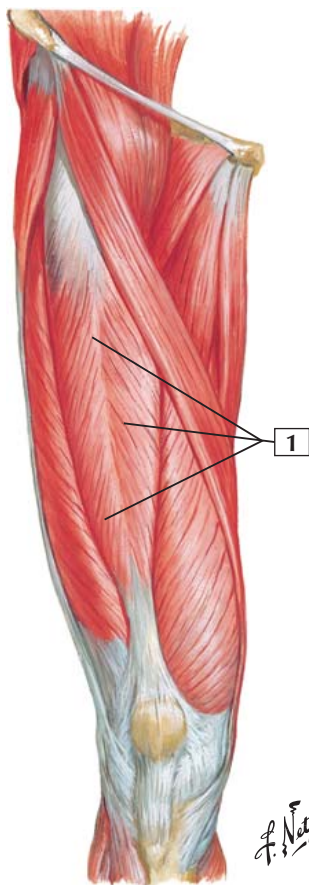
Insertion (distal): Inserts on the superior portion of the medial surface of the tibial shaft, close to the insertions of the gracilis and semitendinosus muscles.

Action: The sartorius muscle crosses the hip and knee joints. Consequently, it is a flexor, abductor, and lateral rotator of the thigh at the hip joint. It is also a flexor of the leg at the knee joint. Along with other muscles originating from the pelvis, it also helps balance the pelvis.

Innervation: Femoral nerve (L2 and L3).

Comment: *Sartorius* is Latin for “tailor.” By sitting cross-legged in a tailor’s position, one can appreciate the function of the sartorius muscle.

Clinical: The sartorius muscle is the longest muscle in the human body. Because it crosses 2 joints, it acts on both of them (hip and knee). However, despite its length, the sartorius is not a particularly strong muscle.



1. Rectus femoris

Origin (proximal): Arises by 2 separate heads: a straight head from the anterior inferior iliac spine and a reflected head from the ilium just superior to the acetabulum.

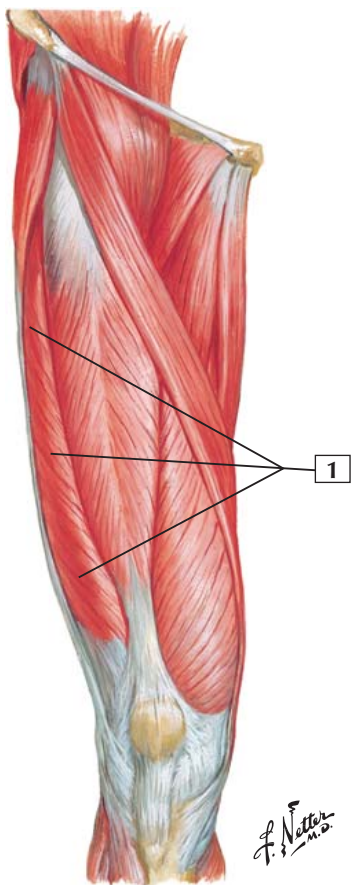
Insertion (distal): The tendons of origin combine to form a fusiform muscle belly that inserts into the quadriceps tendon. This tendon inserts into the base of the patella and, by extension of the patellar ligament, into the tibial tuberosity.

Action: This muscle acts on the knee through the patellar ligament and is an extensor of the leg at the knee joint. Because it also crosses the hip joint, it helps the iliopsoas flex the thigh at the hip.

Innervation: Femoral nerve (L2, L3, and L4).

Comment: The rectus femoris and the 3 vastus muscles form the quadriceps femoris complex. These muscles are powerful extensors of the knee. Of the 4 quadriceps muscles, only the rectus femoris crosses the hip and the knee joint.

Clinical: This muscle acts in concert with the other 3 muscles of the quadriceps femoris and is tested clinically by having the patient extend the leg, flexed at the knee, against resistance. When the thigh is also flexed at the hip during this test, one can see the contraction of the rectus femoris muscle. This muscle also may be injured in sporting events where active kicking is required; it is susceptible to injury at its origin (especially the anterior inferior iliac spine).



1. Vastus lateralis

Origin (proximal): Arises from the posterior aspect of the femur, beginning at the greater trochanter and continuing inferiorly along the lateral lip of the linea aspera of the femur.

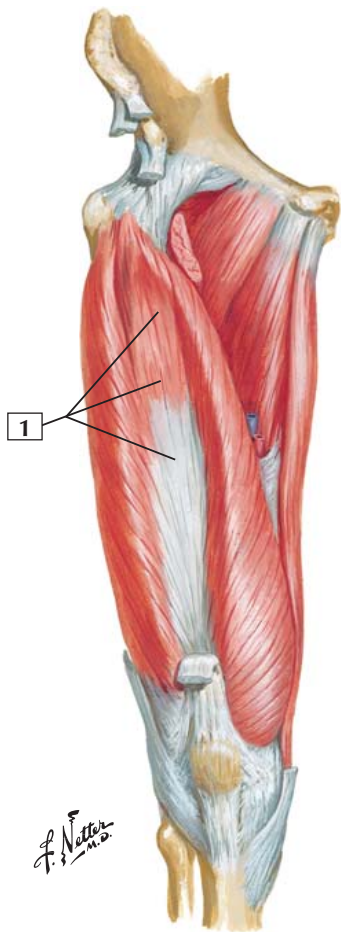
Insertion (distal): Most of the muscle inserts into the lateral patella and the tendon of the rectus femoris to form the quadriceps tendon. The patellar ligament inserts into the tibial tuberosity.

Action: Extension of the leg at the knee.

Innervation: Femoral nerve (L2, L3, and L4).

Comment: The vastus lateralis is 1 of the 4 muscles making up the quadriceps femoris extensor complex of the knee. It covers essentially the entire lateral portion of the thigh.

Clinical: This muscle acts in concert with the other 3 muscles of the quadriceps femoris and is tested clinically by having the patient extend the leg, flexed at the knee, against resistance. The vastus lateralis is the largest of the quadriceps muscles.



1. Vastus intermedius

Origin (proximal): Arises from the anterior and lateral aspects of the femoral shaft and the lateral intermuscular septum.

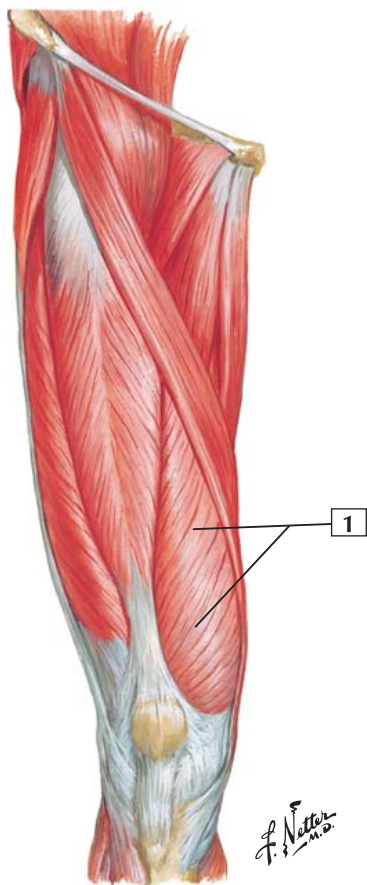
Insertion (distal): Inserts into the posterior surface of the upper border of the patella and forms part of the quadriceps tendon. The patellar tendon inserts into the tibial tuberosity.

Action: Extension of the leg at the knee joint.

Innervation: Femoral nerve (L2, L3, and L4).

Comment: The vastus intermedius is 1 of the 4 muscles of the quadriceps femoris group that makes up the extensor complex of the knee. Tapping the patellar tendon of this extensor complex elicits the knee jerk reflex and tests spinal cord segments L3 and L4.

Clinical: This muscle acts in concert with the other 3 muscles of the quadriceps femoris and is tested clinically by having the patient extend the leg, flexed at the knee, against resistance.



1. Vastus medialis

Origin (proximal): Arises from the intertrochanteric line and medial lip of the linea aspera of the femur and from the medial intermuscular septum.

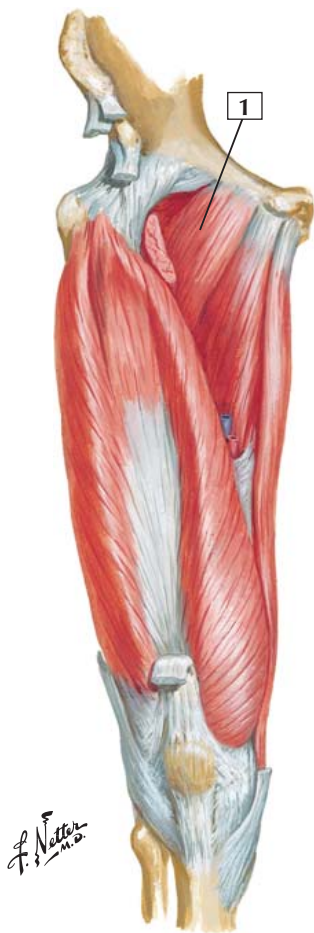Insertion (distal): Inserts into the medial border of the quadriceps tendon, but some of its inferior fibers insert directly into the medial side of the patella. The patellar tendon inserts into the tibial tuberosity.

Action: Extension of the leg at the knee joint.

Innervation: Femoral nerve (L2, L3, and L4).

Comment: The vastus medialis is 1 of the 4 muscles of the quadriceps femoris complex that extends the knee. Similar to the vastus lateralis, the vastus medialis contributes some aponeurotic fibers to the knee joint capsule.

Clinical: This muscle acts in concert with the other 3 muscles of the quadriceps femoris and is tested clinically by having the patient extend the leg, flexed at the knee, against resistance. As with the other 2 vastus muscles of the quadriceps group, it is difficult to isolate the individual movements of these muscles.



1. Pectineus

Origin (proximal): Arises from the pecten of the pubic bone.

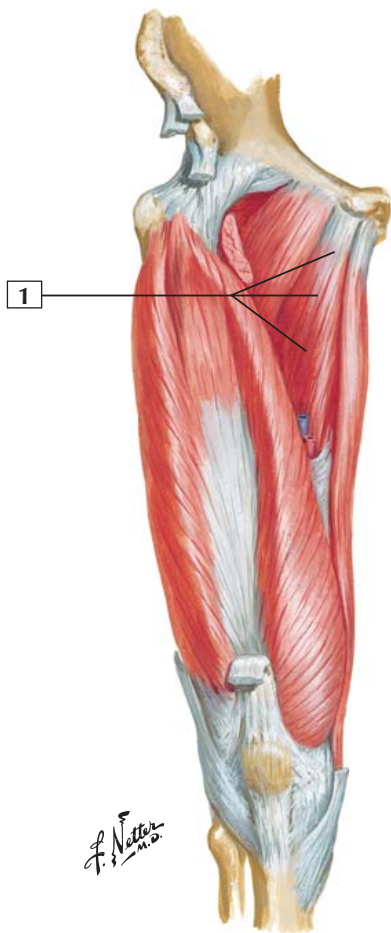
Insertion (distal): Inserts on the pectineal line of the shaft of the femur just inferior to the lesser trochanter.

Action: Adducts and flexes the thigh at the hip joint and assists with medial rotation of the thigh.

Innervation: Femoral nerve (L2 and L3) and occasionally a branch from the obturator nerve.

Comment: The pectineus muscle is medial to the iliopsoas and forms a portion of the floor of the femoral triangle. The muscle is usually flat and quadrangular.

The pectineus is unusual in that it is a muscle of the medial compartment of the thigh (adductor muscles) but is innervated largely by the femoral nerve, a nerve more often associated with the anterior compartment of the thigh (extensors of the leg at the knee).



1. Adductor longus

Origin (proximal): Arises from the body of the pubic bone, just beneath the pubic tubercle.

Insertion (distal): Inserts onto the linea aspera of the femur.

Action: Adducts the thigh, and can flex and medially rotate the thigh.

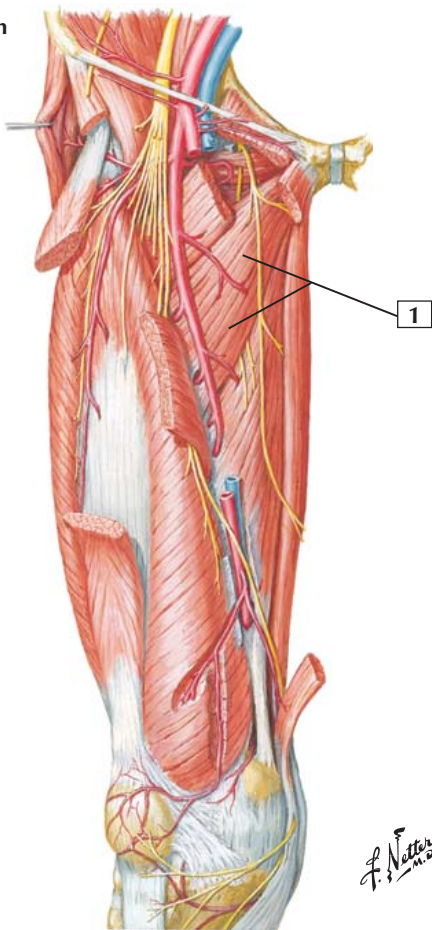
Innervation: Obturator nerve via its anterior branch (L2, L3, and L4).

Comment: The adductor longus is the most anterior of the 3 adductors. It lies within the same plane as the pectineus.

Clinical: The adductor muscles may be tested collectively by asking a patient in the supine position (on the back) whose lower limb is extended to adduct the limb while one holds the ankle to provide resistance to this movement. The adductor muscle bellies can be seen and palpated as the patient adducts the limb.

Groin injuries are common in athletes and usually involve a pulling or tearing of the proximal attachment (origin) of the anteromedial thigh muscles, especially the adductor group.

Deep dissection



1. Adductor brevis

Origin (proximal): Arises from the body and inferior ramus of the pubis.

Insertion (distal): Inserts into the pectineal line and proximal portion of the linea aspera of the femur.

Action: Adducts the thigh at the hip joint and can flex and medially rotate the thigh.

Innervation: Obturator nerve (L2, L3, and L4).

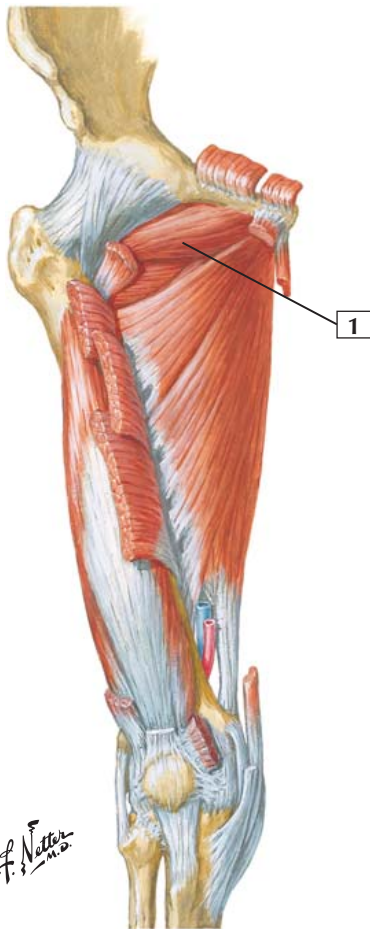
Comment: The adductor brevis, longus, and magnus are the main adductors of the hip. They are helped to a small extent by the gracilis and pectineus.

Branches of the femoral and obturator arteries supply blood to these adductors.

Clinical: The adductor muscles may be tested collectively by asking a patient in the supine position (on the back) whose lower limb is extended to adduct the limb while one holds the ankle to provide resistance to this movement. The adductor muscle bellies can be seen and palpated as the patient adducts the limb.

Groin injuries are common in athletes and usually involve a pulling or tearing of the proximal attachment (origin) of the anteromedial thigh muscles, especially the adductor group.

Deep dissection



1. Obturator externus

Origin (proximal): This flat, triangular muscle covers the outer surface of the pelvis. It arises from the margins of the obturator foramen and obturator membrane.

Insertion (distal): The fibers of this broad muscle converge and course behind the neck of the femur to insert on the intertrochanteric fossa.

Action: Laterally rotates the thigh at the hip and helps steady the head of the femur in the acetabulum of the pelvis.

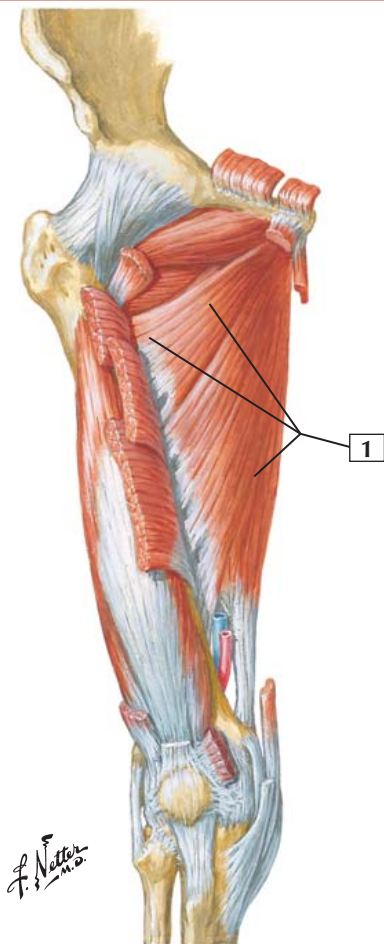
Innervation: Obturator nerve (L3 and L4).

Comment: The gluteus maximus and medius muscles help the obturator externus rotate the hip laterally.

This muscle lies deep in the medial compartment of the thigh and is visible only when the pectineus muscle is reflected.

Clinical: Although combined with the medial adductor groups of muscles, the obturator externus is really a lateral rotator of the thigh at the hip. Clinical examination of this lone muscle is difficult to separate from other muscles that are lateral rotators (some gluteal muscles).

Deep dissection



1. Adductor magnus

Origin (proximal): This large, triangular muscle arises from the inferior ramus of the pubis, the ramus of the ischium, and the ischial tuberosity.

Insertion (distal): Inserts into the gluteal tuberosity, linea aspera, medial supracondylar line, and adductor tubercle of the femur. The portion inserting on the supracondylar line is called the adductor portion. The portion inserting on the adductor tubercle of the femur is called the hamstring portion.

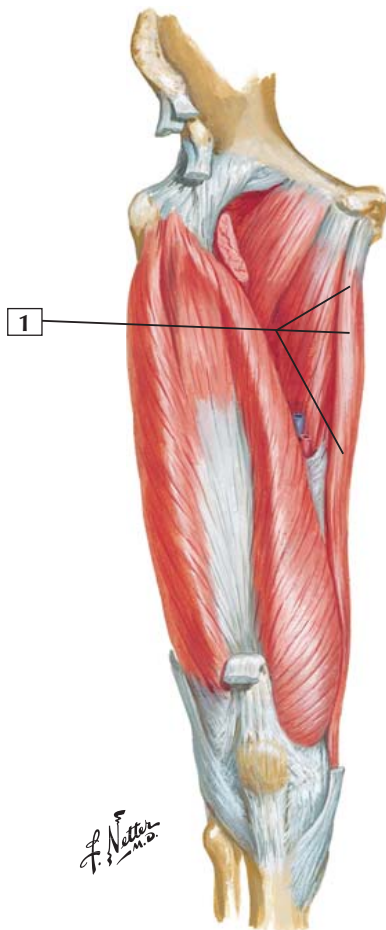
Action: This muscle is a powerful adductor of the thigh at the hip. Its superior portion weakly flexes and medially rotates the thigh. Its lower portion helps extend and laterally rotate the thigh.

Innervation: The adductor portion is innervated by the obturator nerve (L2, L3, and L4). The hamstring portion is innervated by the tibial portion of the sciatic nerve (L4).

Comment: The most superior portion of the adductor magnus is called the adductor minimus if it forms a distinct muscle, as seen in this plate.

The lowest portion of the muscle contains an opening called the adductor hiatus, which allows the femoral vessels to pass into the popliteal fossa.

Clinical: The adductor magnus, or 1 or more of the other adductors, helps to keep the lower limb positioned under the body's center of gravity (prevents one from doing the "splits") and may be easily stretched or torn when forcefully contracted, leading to a groin pull.



1. Gracilis

Origin (proximal): Arises from the body and inferior ramus of the pubis.

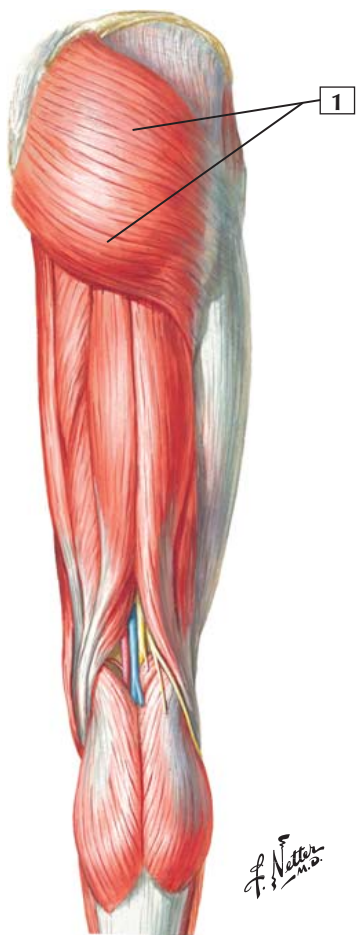
Insertion (distal): Inserts into the medial aspect of the upper portion of the tibia, just below the medial condyle.

Action: Adducts the thigh, flexes the leg at the knee, and, when the knee is flexed, is a medial rotator.

Innervation: Obturator nerve (L2 and L3).

Comment: The gracilis is a long, thin, flat muscle. It crosses the hip and the knee, acting on both joints. Below the knee, its tendon of insertion curves forward and expands, lying in close approximation to the insertions of the sartorius and semitendinosus muscles. The expanded insertion of the tendons of these 3 muscles is called the “pes anserinus” because the insertion resembles the foot of a goose.

Clinical: This muscle, along with the sartorius and semitendinosus, helps stabilize the medial aspect of the extended knee (while the tensor fasciae latae and the iliotibial tract do this on the lateral side of the extended knee). The gracilis is the weakest of the medial adductor group of muscles.



1. Gluteus maximus

Origin (proximal): This large muscle arises from the posterior gluteal line of the ilium, the dorsal surfaces of the sacrum and coccyx, and the sacrotuberous ligament.

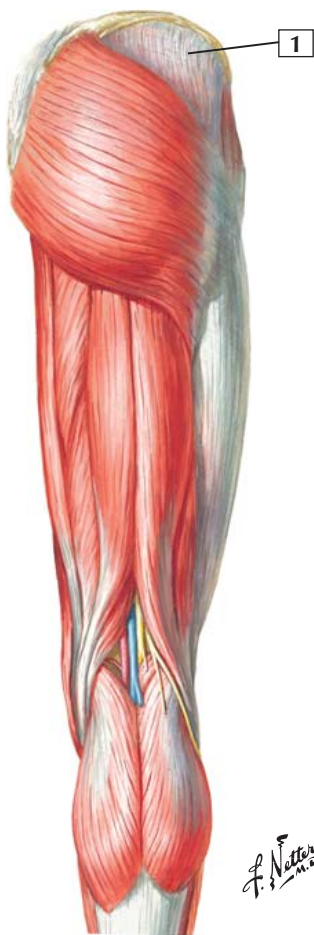
Insertion (distal): Most of this muscle's fibers insert in the iliotibial tract, but some fibers from its lower half attach to the gluteal tuberosity of the femur.

Action: This muscle is a powerful extensor and lateral rotator of the thigh at the hip joint. Its upper fibers may assist in abduction of the thigh, whereas the lower fibers adduct the thigh.

Innervation: Inferior gluteal nerve (L5, S1, and S2).

Comment: The gluteus maximus is the largest muscle in the body and the most powerful extensor of the hip. Although it is used in standing and walking, this muscle is most important as a powerful extensor at the hip when the trunk is being raised from the flexed position. The gluteus maximus is most important in hip extension when rising from a sitting position or in climbing stairs.

Clinical: One tests this muscle with the patient in a supine position with the leg extended at the knee. The underside of the ankle is held, and the patient is asked to extend the slightly raised limb at the hip against this resistance.



1. Gluteus medius

Origin (proximal): Arises from the external surface of the ilium between the anterior and posterior gluteal lines.

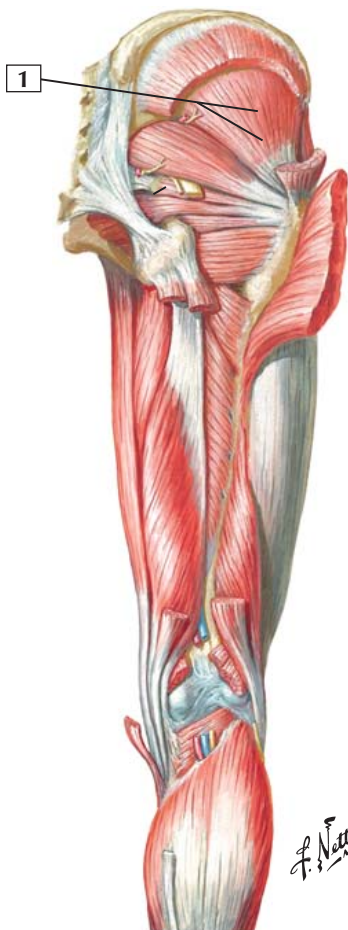Insertion (distal): Inserts into the greater trochanter of the femur.

Action: This muscle is a strong abductor and medial rotator of the thigh at the hip joint. It also steadies the pelvis on the leg when the opposite leg is raised off the ground.

Innervation: Superior gluteal nerve (L5 and S1).

Comment: The gluteus medius is a broad, thick, fan-shaped muscle that, along with the gluteus minimus, is the chief abductor of the hip and medial rotator.

Clinical: The gluteus medius and minimus are tested clinically with the patient in the supine position and the lower limb extended (straight). The examiner holds the ankle laterally and asks the patient to abduct (move laterally) the limb against this resistance. Medial rotation is tested in the supine position by having the patient internally (medially) rotate the thigh against resistance with the lower limb flexed at the hip and knee.



1. Gluteus minimus

Origin (proximal): External surface of the ilium between the anterior and inferior gluteal lines.

Insertion (distal): Greater trochanter of the femur.

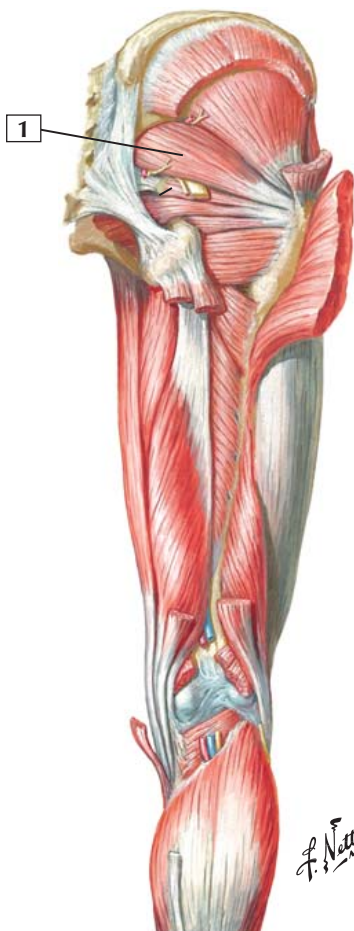
Action: The gluteus minimus abducts and medially rotates the thigh at the hip. Along with the gluteus medius, it also steadies the pelvis on the leg when the opposite leg is raised from the ground.

Innervation: Superior gluteal nerve (L5 and S1).

Comment: The gluteus minimus lies deeper than the gluteus medius. The 2 muscles are separated by deep branches of the superior gluteal neurovascular bundle.

These muscles also are important in stabilizing the hip during walking.

Clinical: The gluteus medius and minimus are tested clinically with the patient in the supine position and the lower limb extended (straight). The examiner holds the ankle laterally and asks the patient to abduct (move laterally) the limb against this resistance. Medial rotation is tested in the supine position by having the patient internally (medially) rotate the thigh against resistance with the lower limb flexed at the hip and knee.



1. Piriformis

Origin (proximal): Arises from the anterior surface of the 2nd, 3rd, and 4th sacral segments and the sacrotuberous ligament.

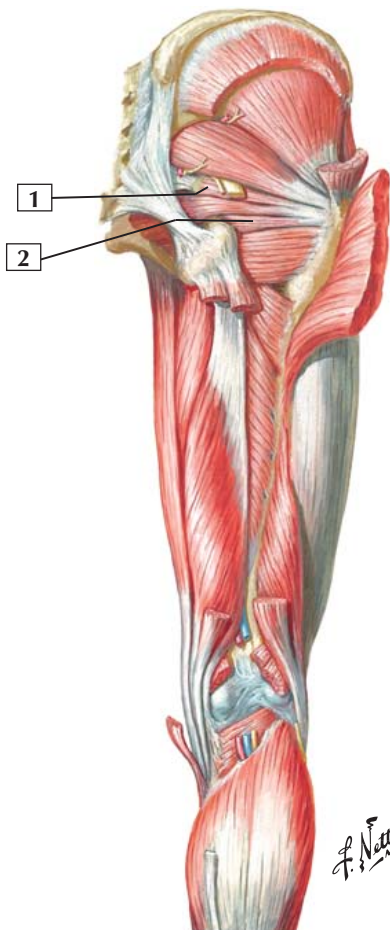Insertion (distal): Inserts by a round tendon into the greater trochanter of the femur.

Action: The piriformis abducts the flexed thigh at the hip and helps stabilize the hip joint. It also laterally rotates the extended thigh.

Innervation: Ventral rami of S1 and S2.

Comment: The piriformis is a pyramid-shaped muscle that arises within the pelvis and passes through the greater sciatic foramen as it courses to its insertion. The sacral nerve plexus is formed largely on the surface of the piriformis muscle within the pelvis. In the gluteal region, the sciatic nerve may pass through the piriformis muscle; more often, it emerges just inferior to the muscle's belly.

Clinical: Because of the close relationship of the piriformis muscle to the large sciatic nerve, hypertrophy or spasm of this muscle can compress the sciatic nerve, causing significant pain. This is most common in athletes who use these muscles frequently (e.g., ice hockey players, figure skaters, rock climbers, cyclists).



WWW.YAZDANPRESS.COM

Superior Gemellus and Inferior Gemellus

1. Superior gemellus
2. Inferior gemellus

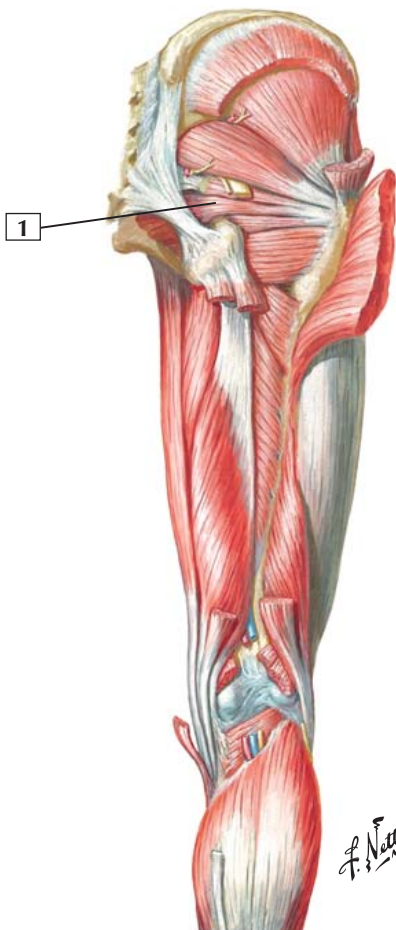Origin (proximal): The superior gemellus arises from the spine of the ischium. The inferior gemellus arises from the ischial tuberosity.

Insertion (distal): Both muscle tendons blend with the tendon of the obturator internus to insert on the medial aspect of the greater trochanter of the femur.

Action: Both muscles laterally rotate the extended thigh and abduct the flexed thigh at the hip. They also steady the femoral head in the acetabulum.

Innervation: The superior gemellus is supplied by the nerve to the obturator internus (L5 and S1). The inferior gemellus is innervated by a branch of the nerve to the quadratus femoris (L5 and S1).

Comment: The 2 small gemelli lie parallel to the obturator internus tendon in the gluteal region. Although each muscle varies in size, the superior gemellus is usually smaller.



1. Obturator internus

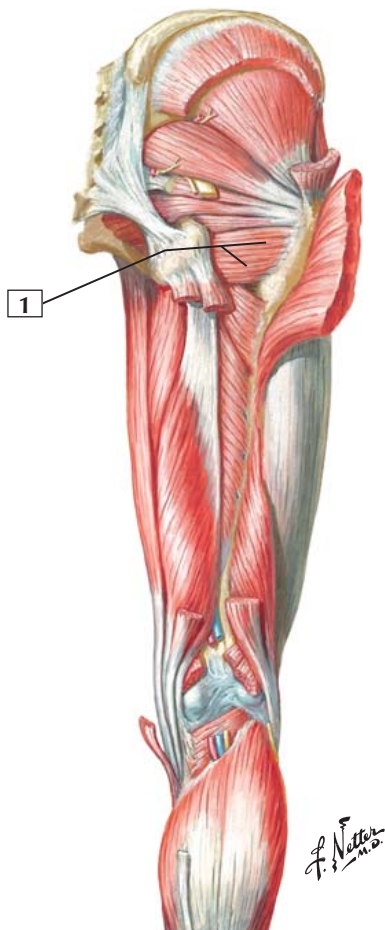
Origin (proximal): Arises from the pelvic aspect of the obturator membrane and the pelvic bones surrounding the obturator foramen.

Insertion (distal): Medial surface of the greater trochanter of the femur.

Action: Laterally rotates the extended thigh at the hip joint and abducts the flexed thigh at the hip. The muscle also steadies the femoral head in the acetabulum.

Innervation: Nerve to the obturator internus (L5 and S1).

Comment: The obturator internus has an extensive area of origin from within the pelvis, but it quickly tapers into a narrow muscle belly and tendon. The muscle leaves the pelvis through the lesser sciatic foramen and courses to its insertion. Its sides are bounded by the 2 gemelli.



1. Quadratus femoris

Origin (proximal): Arises from the lateral border of the ischial tuberosity.

Insertion (distal): Inserts on the quadrate tubercle on the intertrochanteric crest of the femur and inferior to it.

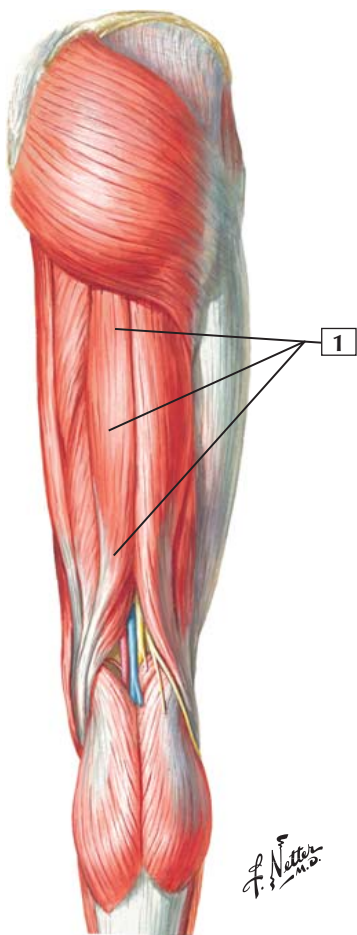
Action: Rotates the thigh laterally.

Innervation: Nerve to the quadratus femoris (L5 and S1).

Comment: As its name implies, this small, flat muscle is quadrilateral in shape.

The piriformis, obturator internus, superior and inferior gemelli, and quadratus femoris function as short lateral rotators at the hip. All of these muscles insert near the trochanteric fossa and help rotate the extended femur laterally. They also stabilize the hip joint by steadying the head of the femur in the acetabulum.

Clinical: A trochanteric bursa protects the muscles that insert at or near the greater trochanter, and inflammation of this bursa (bursitis) is common. The pain is especially acute when the patient abducts and laterally rotates the thigh at the hip against resistance.



1. Semitendinosus

Origin (proximal): Arises from the ischial tuberosity of the pelvis.

Insertion (distal): Its prominent tendon inserts on the medial surface of the superior portion of the tibia.

Action: Flexes the leg at the knee and, when the knee is flexed, medially rotates the tibia. It also is an extensor of the thigh at the hip joint. When the hip and knee both are flexed, it can extend the trunk.

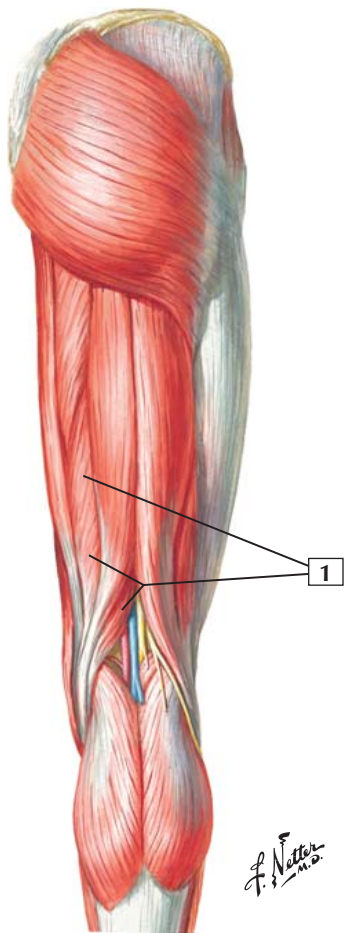
Innervation: Sciatic nerve, tibial division (L5, S1, and S2).

Comment: The semitendinosus is 1 of the 3 muscles making up the hamstrings. This slender muscle has a long tendon of insertion.

The tendon of insertion combines with the tendons of the gracilis and sartorius to form the pes anserinus (goose's foot) on the medial aspect of the knee joint.

Clinical: The hamstrings are collectively tested by having the supine patient flex the limb 90° at the hip and knee and then further flexing the knee against resistance. Hamstring muscle pulls or tears are common athletic injuries because these muscles stretch across 2 joints. Stretching these muscles before vigorous exercise is recommended.

Superficial
dissection



1. Semimembranosus

Origin (proximal): Arises by a thick tendon from the ischial tuberosity.

Insertion (distal): Its tendon inserts on the posteromedial aspect of the medial condyle of the tibia. The tendon of insertion also gives rise to a lateral expansion into the knee joint capsule, forming much of the oblique popliteal ligament. A few fascial expansions may reinforce the medial patellar retinaculum.

Action: The muscle flexes the leg at the knee and rotates the flexed leg medially. It also extends the thigh at the hip joint. With the hip and knee flexed, it extends the trunk.

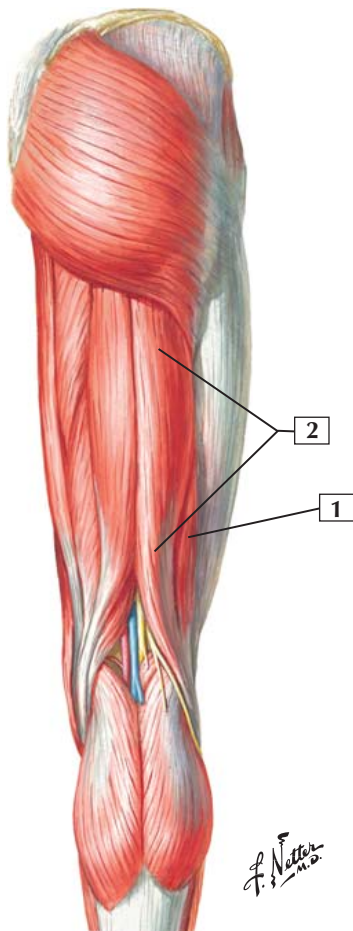
Innervation: Sciatic nerve, tibial division (L5, S1, and S2).

Comment: The semimembranosus is 1 of the 3 muscles making up the hamstrings. Although the muscle is tendinous at its origin and its insertion, the middle portion is long and flat, resembling a membrane.

Clinical: The hamstrings are collectively tested by having the supine patient flex the limb 90° at the hip and knee and then further flexing the knee against resistance. Hamstring muscle pulls or tears are common athletic injuries because these muscles stretch across 2 joints. Stretching these muscles before vigorous exercise is recommended.

**Biceps Femoris:
Short Head and Long Head**

Superficial
dissection



Biceps Femoris: Short Head and Long Head

1. Biceps femoris: Short head
2. Biceps femoris: Long head

Origin (proximal): The long head of this muscle arises from the ischial tuberosity. The short head arises from the linea aspera and lateral supracondylar line of the femur.

Insertion (distal): The 2 heads of this muscle unite, and their common tendon inserts on the lateral side of the head of the fibula. Just before this attachment, the tendon is split by the fibular collateral ligament of the knee.

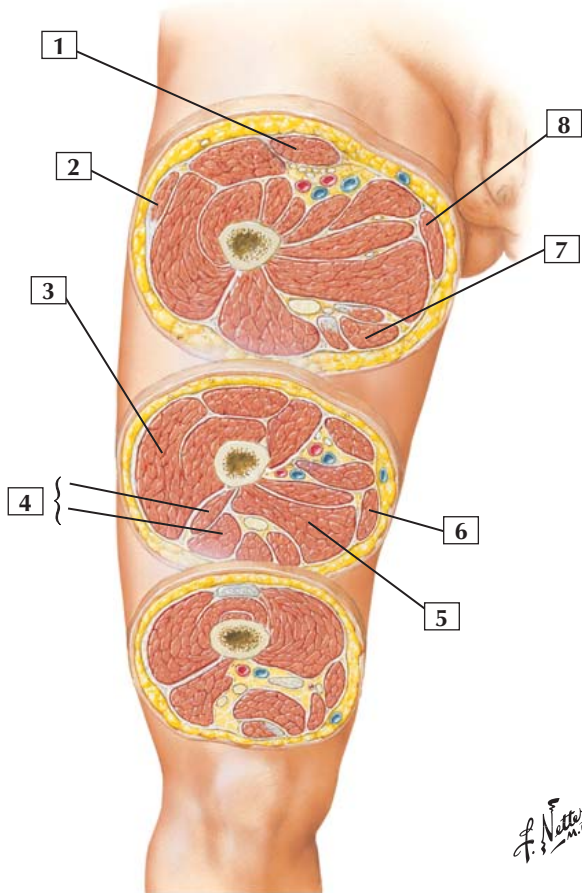
Action: The biceps femoris flexes the leg at the knee, and, after the knee is flexed, the muscle rotates the tibia laterally from the femur. The long head (but not the short head) also extends the thigh at the hip.

Innervation: The long head is innervated by the sciatic nerve, tibial division (L5, S1, and S2). The short head is innervated by the sciatic nerve, common fibular (peroneal) division (L5, S1, and S2).

Comment: The long head of the biceps femoris is 1 of the 3 muscles making up the hamstrings. Similar to the other 2 hamstring muscles, the long head of the biceps femoris extends the thigh at the hip and flexes the leg at the knee. The long head also laterally rotates the leg at the knee.

The short head of the biceps does not cross 2 joints and is not innervated by the tibial division of the sciatic nerve.

Clinical: The hamstrings are collectively tested by having the supine patient flex the limb 90° at the hip and knee and then further flexing the knee against resistance.



*F. Netter
M.D.*

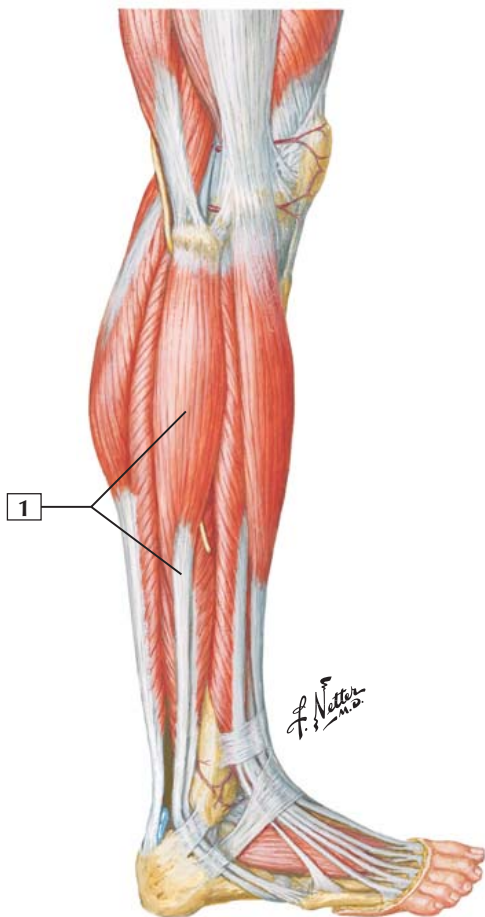
Thigh Muscles

1. Sartorius
2. Tensor fasciae latae
3. Vastus lateralis
4. Biceps femoris (Short head; Long head)
5. Adductor magnus
6. Gracilis
7. Semitendinosus
8. Gracilis

Comment: The thigh muscles are divided into 3 compartments. The anterior compartment contains the quadriceps femoris group, which extend the knee. The medial compartment contains the adductors of the thigh at the hip. The posterior compartment contains the hamstring muscles, which flex the knee and extend the hip.

In general, muscles of the anterior compartment are innervated by the femoral nerve; muscles of the medial compartment, by the obturator nerve; and muscles of the posterior compartment, by the sciatic nerve (mostly the tibial portion of the sciatic nerve). These generalizations are a good way to categorize these thigh muscles and remember their innervations, but exceptions to each of these generalizations exist for each compartment.

Clinical: Sensory changes to the femoral nerve can be detected over the anterior thigh, medial knee, and medial aspect of the leg. Obturator sensory changes are detected over the medial thigh and the sciatic nerve over the mid-posterior thigh, knee, posterolateral leg and entire sole of the foot.



1. Fibularis (peroneus) longus

Origin (proximal): Arises from the head and upper two-thirds of the lateral surface of the fibula.

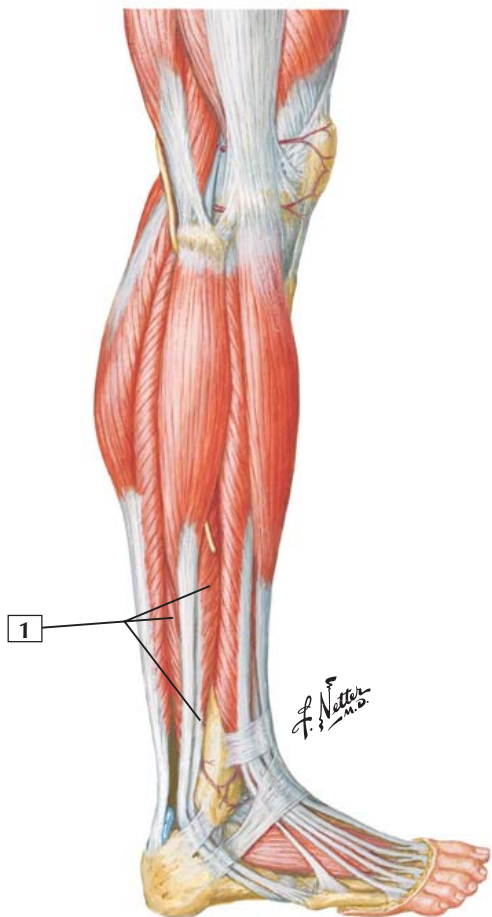
Insertion (distal): This muscle ends in a long tendon that runs behind the lateral malleolus and crosses obliquely on the plantar surface of the foot to insert at the base of the 1st metatarsal and medial cuneiform bone.

Action: Everts the foot and is a weak plantarflexor of the foot at the ankle.

Innervation: Superficial fibular (peroneal) nerve (L5, S1, and S2).

Comment: The oblique course of the tendon across the plantar aspect of the foot helps maintain the foot's lateral longitudinal and transverse arches.

Clinical: This muscle is tested clinically by having the patient evert the foot against resistance. In some individuals with excessively mobile ankle joints, hypereversion can irritate the lateral compartment muscles (fibularis longus and fibularis brevis), causing pain, swelling, and compression of the neurovascular bundle.



1. Fibularis (peroneus) brevis

Origin (proximal): Arises from the distal two-thirds of the lateral surface of the fibula.

Insertion (distal): Fibers of this muscle course downward, ending as a tendon that passes behind the lateral malleolus and runs forward to insert into the tuberosity on the lateral side of the base of the 5th metatarsal.

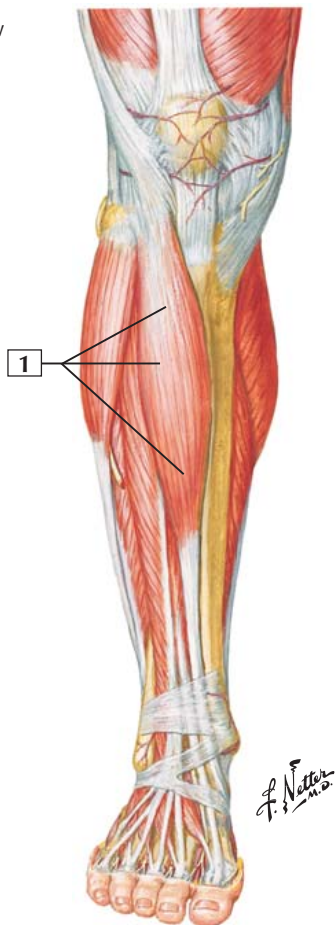
Action: Everts the foot and acts as a weak plantarflexor of the foot at the ankle joint.

Innervation: Superficial fibular (peroneal) nerve (L5, S1, and S2).

Comment: During walking, this muscle helps balance the foot and support weight by compensating for inversion.

Clinical: This muscle is tested clinically by having the patient evert the foot against resistance. In some individuals with excessively mobile ankle joints, hypereversion can irritate the lateral compartment muscles (fibularis longus and fibularis brevis), causing pain, swelling, and compression of the neurovascular bundle.

Anterior View



1. Tibialis anterior

Origin (proximal): Arises from the lateral condyle and superior half of the lateral surface of the tibia and from the interosseous membrane.

Insertion (distal): Inserts into the medial and inferior surfaces of the medial cuneiform tarsal and the base of the 1st metatarsal.

Action: Dorsiflexes the foot at the ankle and inverts the foot at the subtalar and midtarsal joints.

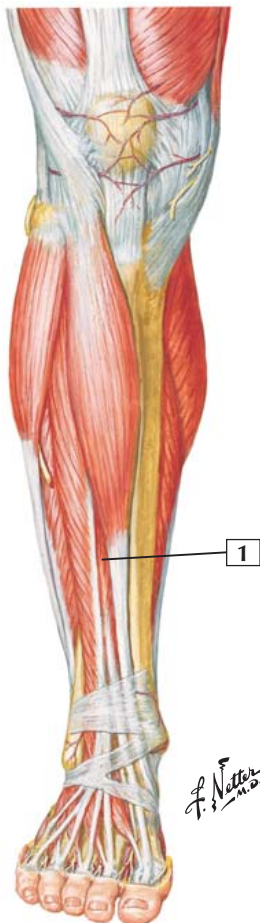
Innervation: Deep fibular (peroneal) nerve (L4 and L5).

Comment: The tibialis anterior is the largest muscle in the anterior compartment of the leg. In general, muscles of this compartment dorsiflex the foot at the ankle and extend the toes. Their blood supply comes largely from the anterior tibial artery and its branches.

Clinical: This muscle is clinically tested by having the patient dorsiflex the foot against resistance. The muscle tendon and belly will be evident over the anterior leg.

Anterior (tibial) compartment syndrome (or anterior or lateral “shin splints”) occurs from excessive contraction of anterior compartment muscles. Pain radiates down the ankle and dorsum of the foot overlying the extensor tendons of these muscles.

Anterior View



1. Extensor hallucis longus

Origin (proximal): Arises from the middle portion of the anterior surface of the fibula and the interosseous membrane.

Insertion (distal): Inserts on the dorsal aspect of the base of the distal phalanx of the big toe.

Action: Extends the big toe, assists in dorsiflexion of the foot at the ankle, and is a weak invertor.

Innervation: Deep fibular (peroneal) nerve (L5 and S1).

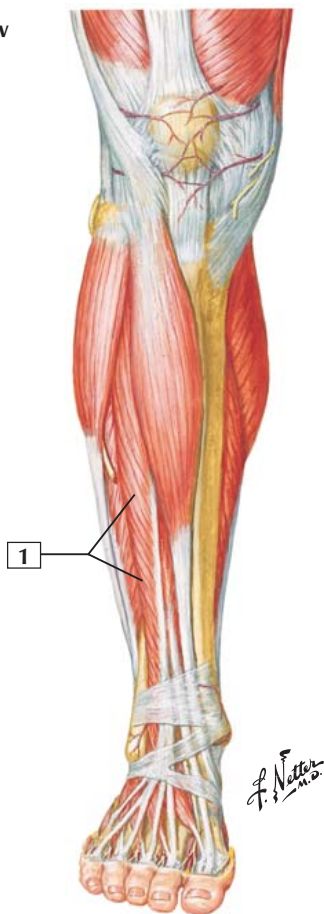
Comment: Most of the muscular belly of the extensor hallucis longus is covered by the tibialis anterior and the extensor digitorum longus.

There is also a small extensor hallucis brevis on the dorsum of the foot. It sends its tendon to the proximal phalanx of the big toe. This muscle is innervated by the deep fibular nerve and extends the proximal phalanx of the big toe.

Clinical: This muscle is clinically tested by having the patient dorsiflex (extend) the big toe against resistance. The tendon is seen passing to the great toe.

Anterior (tibial) compartment syndrome (or anterior or lateral “shin splints”) occurs from excessive contraction of anterior compartment muscles. Pain radiates down the ankle and dorsum of the foot overlying the extensor tendons of these muscles.

Anterior View



1. Extensor digitorum longus

Origin (proximal): Arises from the lateral condyle of the tibia, most of the upper anterior surface of the body of the fibula, and the interosseous membrane.

Insertion (distal): After passing beneath the superior and inferior extensor retinacula, the tendon divides into 4 slips that insert into the middle and distal phalanges of toes 2 through 5.

Action: Extends the proximal phalanges of the lateral 4 toes and is a dorsiflexor of the foot at the ankle.

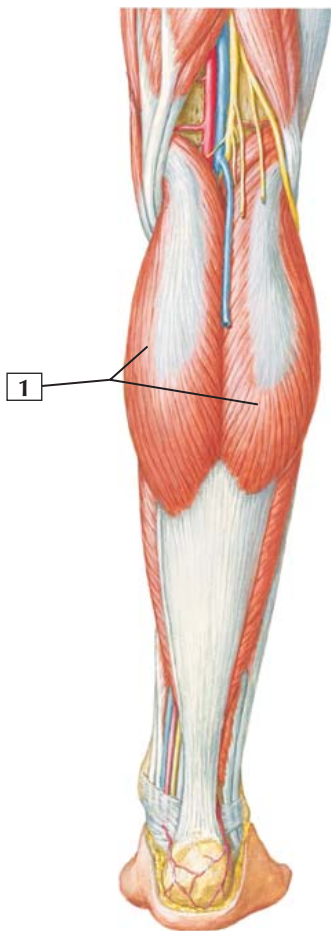
Innervation: Deep fibular (peroneal) nerve (L5 and S1).

Comment: This penniform muscle lies in the lateral part of the anterior compartment of the leg. Variations are frequent. Although described as dividing into 4 slips, or small tendons, it may send multiple slips to the toes.

There is also an extensor digitorum brevis on the dorsum of the foot. It sends 4 small muscle slips to the 4 lateral toes. This muscle helps the extensor digitorum longus extend the toes. It is also innervated by the deep fibular nerve.

Clinical: This muscle is tested clinically by having the patient dorsiflex (extend) the 4 lateral toes against resistance.

Anterior (tibial) compartment syndrome (or anterior or lateral “shin splints”) occurs from excessive contraction of anterior compartment muscles. Pain radiates down the ankle and dorsum of the foot overlying the extensor tendons of these muscles.



*F. Netter
M.D.*

1. Gastrocnemius

Origin (proximal): This muscle has 2 heads. The lateral head arises from the lateral aspect of the lateral condyle of the femur. The medial head arises from the posterior part of the medial condyle and the popliteal surface of the femur above the medial condyle.

Insertion (distal): The fibers of this muscle unite to form a tendinous raphe. The raphe expands into a broad aponeurosis that unites with the tendon of the soleus and forms the calcaneal tendon. The tendon attaches to the posterior surface of the calcaneus.

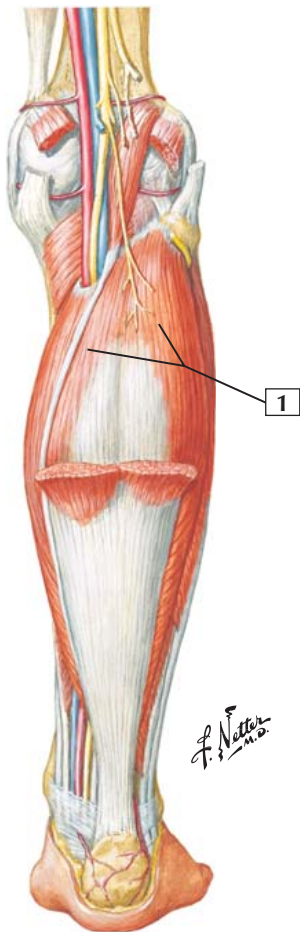
Action: Plantarflexes the foot at the ankle, flexes the leg at the knee, and raises the heel during walking.

Innervation: Tibial nerve (S1 and S2).

Comment: The tendon blends with that of the soleus muscle to form the calcaneal tendon (tendo calcaneus, or Achilles tendon).

Clinical: One tests this muscle clinically by having a supine patient extend the leg and plantarflex the foot against resistance. The muscle bellies in the calf should be obvious.

Tendinitis of the calcaneal tendon is a painful inflammation that often occurs in runners who run on hills or uneven surfaces. Repetitive stress on the tendon occurs as the heel strikes the ground and when plantarflexion lifts the foot and toes. Rupture of the tendon is a serious injury.



1. Soleus

Origin (proximal): Arises from the posterior aspect of the head of the fibula, the proximal third of the posterior body of the fibula, the soleal line, and the medial border of the tibia.

Insertion (distal): The muscle fibers end in an aponeurosis that thickens, narrows, and joins the gastrocnemius. The resulting calcaneal tendon inserts on the posterior surface of the calcaneus.

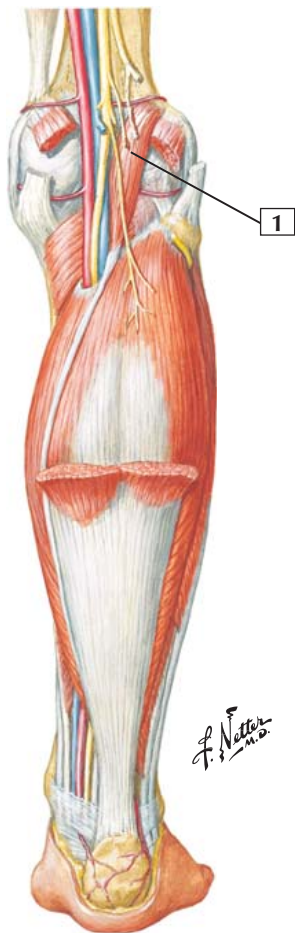Action: This muscle plantarflexes the foot at the ankle and is an important postural muscle. Apparently, it is constantly active, even during quiet standing, and it aids in maintaining balance.

Innervation: Tibial nerve (S1 and S2).

Comment: The upper portion of the soleus is covered largely by the gastrocnemius muscle.

Clinical: The soleus is tested clinically by having the supine patient flex the limb at the hip and knee and then plantarflex the foot against resistance.

Tendinitis of the calcaneal tendon is a painful inflammation that often occurs in runners who run on hills or uneven surfaces. Repetitive stress on the tendon occurs as the heel strikes the ground and when plantarflexion lifts the foot and toes. Rupture of the tendon is a serious injury.





1. Plantaris

Origin (proximal): Arises from the inferior end of the lateral supracondylar line of the femur and oblique popliteal ligament.

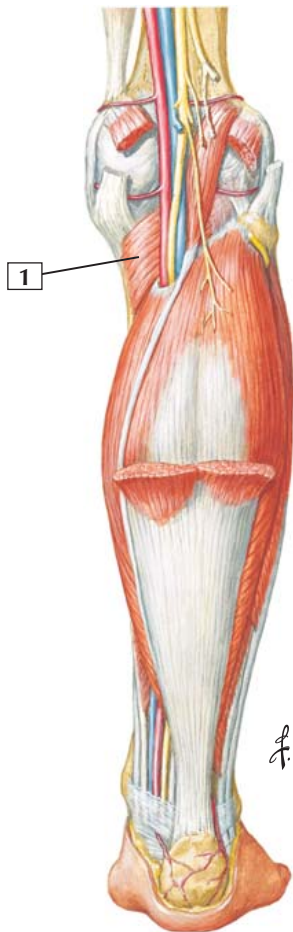Insertion (distal): This muscle's long, slender tendon crosses obliquely between the gastrocnemius and soleus and inserts into the posterior part of the calcaneus, often fusing with the calcaneal tendon.

Action: Weakly assists the gastrocnemius in plantarflexion of the foot at the ankle and flexion of the leg at the knee.

Innervation: Tibial nerve (S1 and S2).

Comment: The gastrocnemius, soleus, and plantaris form the superficial group of muscles in the posterior compartment of the leg. The tibial nerve and posterior tibial vessels run just deep to these 3 muscles.

Clinical: The plantaris muscle is absent in a small proportion of the population (5-10%) and is vestigial in humans. The small tendon may be used for grafting, especially in reconstructive surgery of the hand where tendons may have been damaged beyond repair.





1. Popliteus

Origin (proximal): Arises from the lateral surface of the lateral condyle of the femur and the capsule of the knee joint. This muscle has a tendinous attachment to the lateral meniscus of the knee.

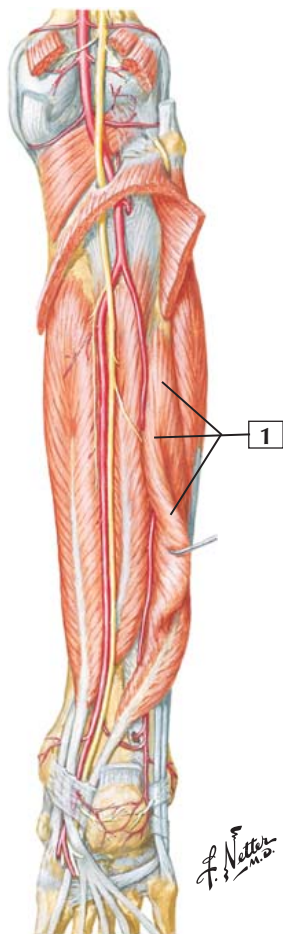
Insertion (distal): Posterior surface of the tibia, superior to the soleal line.

Action: Flexes and medially rotates the leg at the knee. When the limb is supporting weight, the popliteus rotates the femur laterally on the tibia to “unlock” the knee joint.

Innervation: Tibial nerve (L4, L5, and S1).

Comment: This thin, flat, triangular muscle forms the distal part of the floor of the popliteal fossa.

Clinical: A small bursa lies between the tendon of this muscle and the lateral tibial condyle.



1. Flexor hallucis longus

Origin (proximal): Arises from the inferior two-thirds of the posterior surface of the fibula and from the inferior portion of the interosseous membrane.

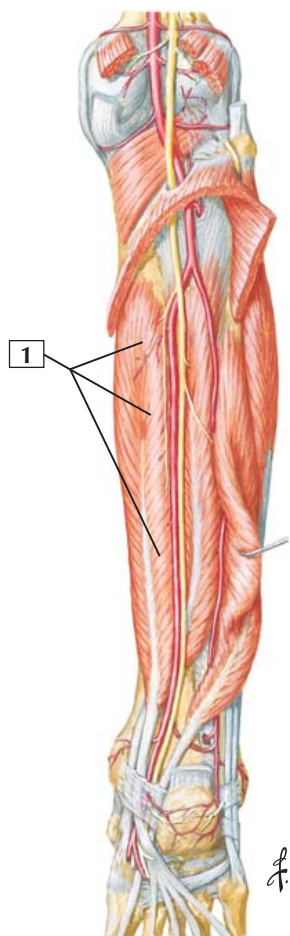
Insertion (distal): Its tendon enters the foot with the tendons of the flexor digitorum longus and tibialis posterior. It inserts on the base of the distal phalanx of the big toe.

Action: Flexes the distal phalanx of the big toe, plantarflexes the foot at the ankle, and helps propel the foot during walking or running.

Innervation: Tibial nerve (S2 and S3).

Comment: This muscle also helps support the medial longitudinal arch of the foot.

Clinical: This muscle is tested clinically by having the patient flex the big toe, especially against resistance. As this is done, one can palpate the tendon of the muscle on the plantar aspect of the base of the big toe.



1. Flexor digitorum longus

Origin (proximal): Arises from the middle portion of the posterior surface of the tibia inferior to the soleal line and from the fascia covering the tibialis posterior.

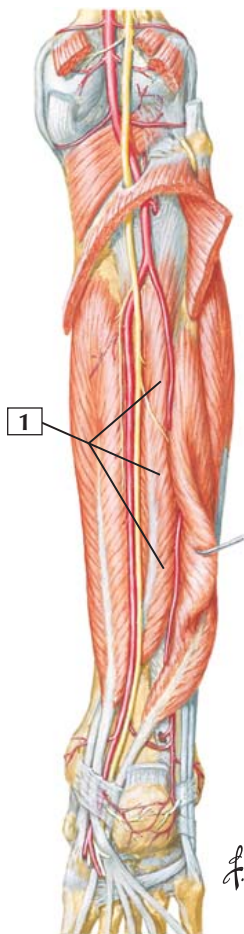
Insertion (distal): In the sole of the foot, the tendon divides into 4 slips that insert on the bases of the distal phalanges of the 4 lateral toes.

Action: Flexes the 4 lateral digits, especially the distal phalanges, allowing them to grip the ground during walking. This muscle also plantarflexes the foot at the ankle, aids with inversion, and helps support the foot's longitudinal arches.

Innervation: Tibial nerve (S2 and S3).

Comment: This muscle is situated on the tibial side of the leg. Along with the flexor hallucis longus tendon and tibialis posterior tendon, the tendon of the flexor digitorum longus courses posteriorly to the medial malleolus, passing deep to the flexor retinaculum.

Clinical: This muscle is tested by having the patient plantarflex the toes against resistance. As this is done, one can palpate the tendons to the 4 lateral toes on the plantar aspect of the distal foot.



*F. Netter
M.D.*

1. Tibialis posterior

Origin (proximal): Arises from the posterior surface of the interosseous membrane, the posterior aspect of the tibia inferior to the soleal line, and the posterior surface of the fibula.

Insertion (distal): Inserts on the tuberosity of the navicular bone; the plantar surfaces of the cuboid and cuneiform bones; and the bases of the 2nd, 3rd, and 4th metatarsals.

Action: Plantarflexes the foot at the ankle and inverts the foot when the foot is not bearing weight.

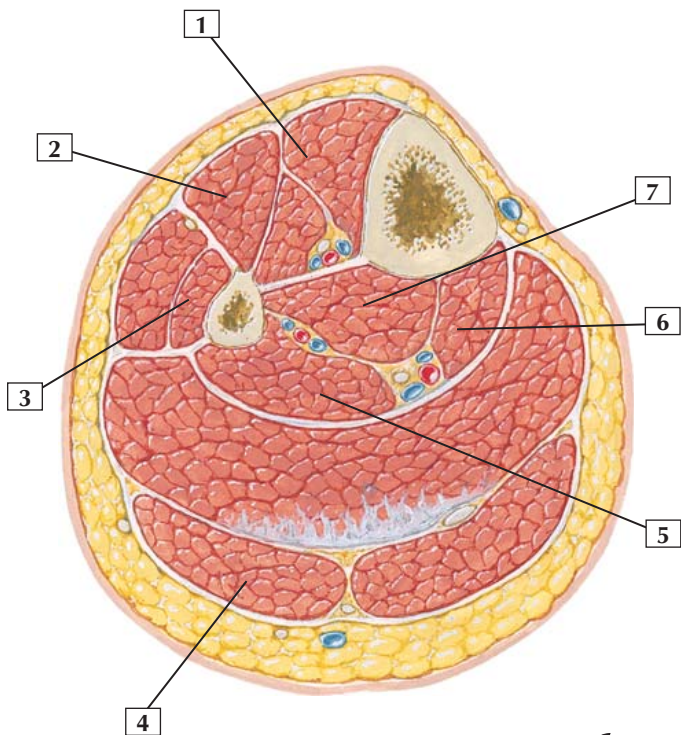
Innervation: Tibial nerve (L4 and L5).

Comment: When the foot is bearing weight, the tibialis posterior, along with several other muscles, helps distribute the weight on the foot and helps maintain balance.

Clinical: One can test this muscle by having the patient invert the foot against resistance.

“Shin splints” refers to pain along the inner distal two-thirds of the tibial shaft and is a common syndrome in athletes. The primary cause is repetitive pulling of the tibialis posterior tendon as one pushes off the foot during running. Stress on the muscle occurs at its attachment proximally to the tibia and interosseous membrane.

Cross section just above middle of leg



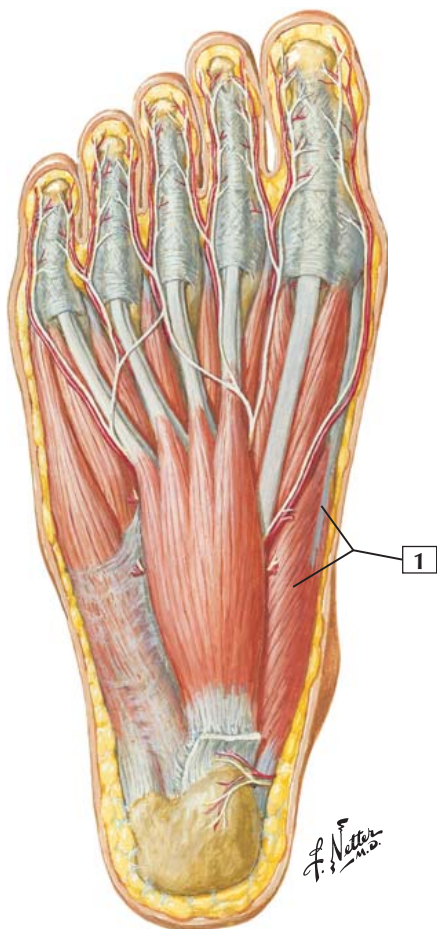
F. Netter M.D.

1. Tibialis anterior
2. Extensor digitorum longus
3. Fibularis (peroneus) brevis
4. Gastrocnemius muscle (lateral head)
5. Flexor hallucis longus
6. Flexor digitorum longus
7. Tibialis posterior

Comment: Similar to the thigh, the leg has 3 compartments. The anterior compartment contains the dorsiflexors of the foot. The lateral compartment contains the everters of the foot. The posterior compartment contains muscles that are largely plantarflexors of the foot at the ankle, flexors of the toes, and invertors of the foot.

The anterior compartment muscles are innervated by the deep fibular nerve and supplied by the anterior tibial artery. The lateral compartment muscles are innervated by the superficial fibular nerve and supplied by the fibular artery. The posterior compartment muscles are innervated by the tibial nerve and supplied by the posterior tibial artery.

Clinical: The sensory area of the common fibular nerve is over the lateral and anterolateral aspect of the leg and dorsum of the foot. Deep fibular nerve sensation can be tested over the skin between the great toe and second toe dorsally.



1. Abductor hallucis

Origin (proximal): Arises from the medial process of the tuberosity of the calcaneus and from the flexor retinaculum and plantar aponeurosis.

Insertion (distal): Inserts into the medial aspect of the base of the proximal phalanx of the big toe.

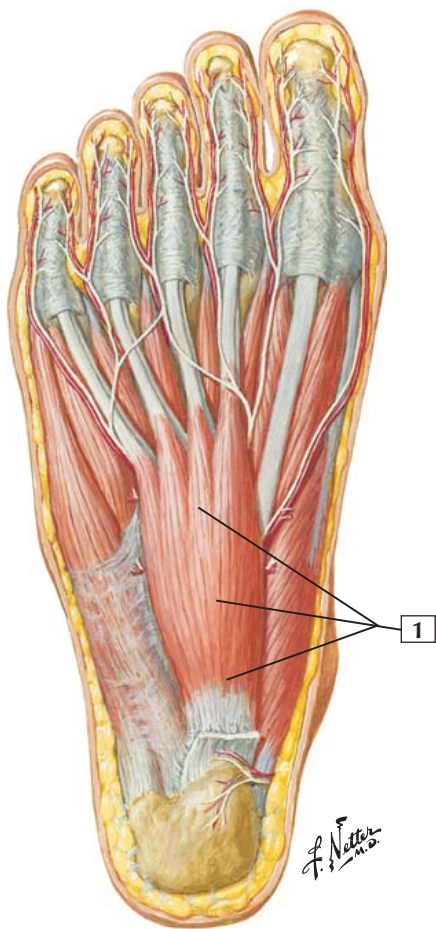
Action: Abducts the big toe at the metatarsophalangeal joint and can flex the toe.

Innervation: Medial plantar nerve (S2 and S3).

Comment: The tendon of the abductor hallucis and the medial tendon of the flexor hallucis brevis muscle insert together.

The first layer of foot muscles are covered by a medial and lateral plantar fascia and a central thickened plantar aponeurosis (fascia).

Clinical: Plantar fasciitis (heel spur syndrome) is a common cause of heel pain, especially in joggers, and results from inflammation of the plantar aponeurosis at its attachment point to the calcaneus (cut in this figure).



1. Flexor digitorum brevis

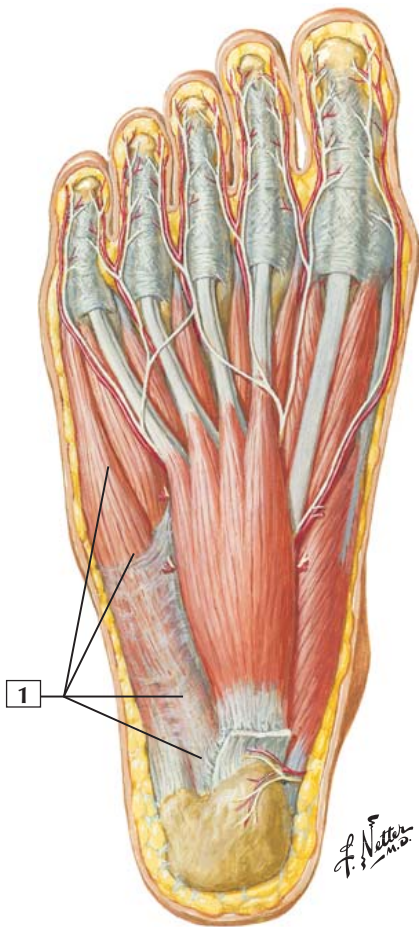
Origin (proximal): Arises from the medial tubercle of the tuberosity of the calcaneus and from the plantar aponeurosis and intermuscular septa.

Insertion (distal): This muscle gives rise to 4 tendons that are superficial to the tendons of the flexor digitorum longus. Within their digital tendon sheaths, the tendons of the brevis split to allow the long flexor tendons to pass to the distal phalanges. The brevis tendons insert on both sides of the middle phalanges of the 4 lateral toes.

Action: This muscle flexes the 2nd (middle) phalanx of the 4 lateral toes.

Innervation: Medial plantar nerve (S2 and S3).

Comment: The arrangement of the flexor digitorum longus and brevis tendons in the foot is similar to that of the superficial and deep digital flexors in the hand.



1. Abductor digiti minimi

Origin (proximal): Arises from the medial and lateral tubercles of the tuberosity of the calcaneus, the plantar aponeurosis, and the intermuscular septa.

Insertion (distal): Its tendon and the tendon of the flexor digiti minimi brevis insert together into the lateral side of the base of the proximal phalanx of the 5th, or little, toe.

Action: Abducts and helps flex the little toe at the metatarsophalangeal joint.

Innervation: Lateral plantar nerve (S2 and S3).

Comment: Some fibers of this muscle often insert onto the tuberosity at the base of the 5th metatarsal as well. These fibers can constitute a separate muscle named the abductor ossis metatarsi quinti.



1. Flexor hallucis brevis

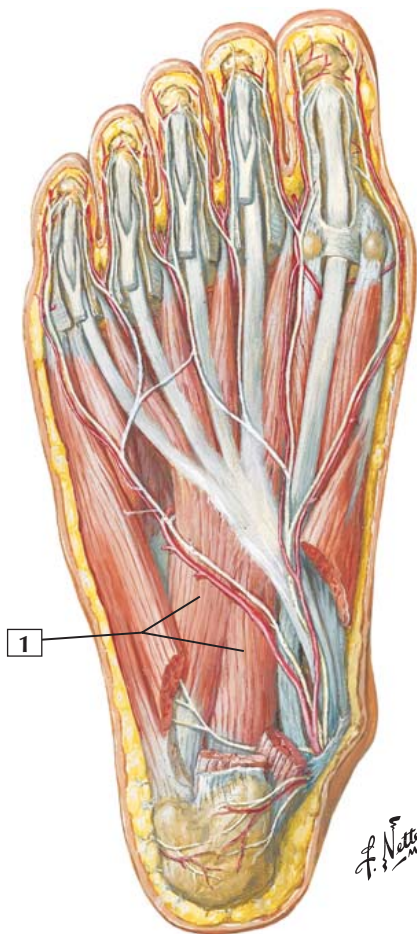
Origin (proximal): Arises from the plantar surfaces of the cuboid and lateral cuneiform bones.

Insertion (distal): The muscle belly divides into 2 parts. The medial portion blends with the abductor hallucis and shares a medial sesamoid bone of the big toe to insert on the medial aspect of the base of the proximal phalanx. The lateral portion blends with the 2 heads of the adductor hallucis, sharing a lateral sesamoid bone and inserting on the lateral side of the base of the proximal phalanx.

Action: Flexes the proximal phalanx of the big toe at the metatarsophalangeal joint.

Innervation: Medial plantar nerve (S2 and S3).

Comment: The tendons of insertion of this muscle are associated with the 2 sesamoid bones of the big toe.



1. Quadratus plantae

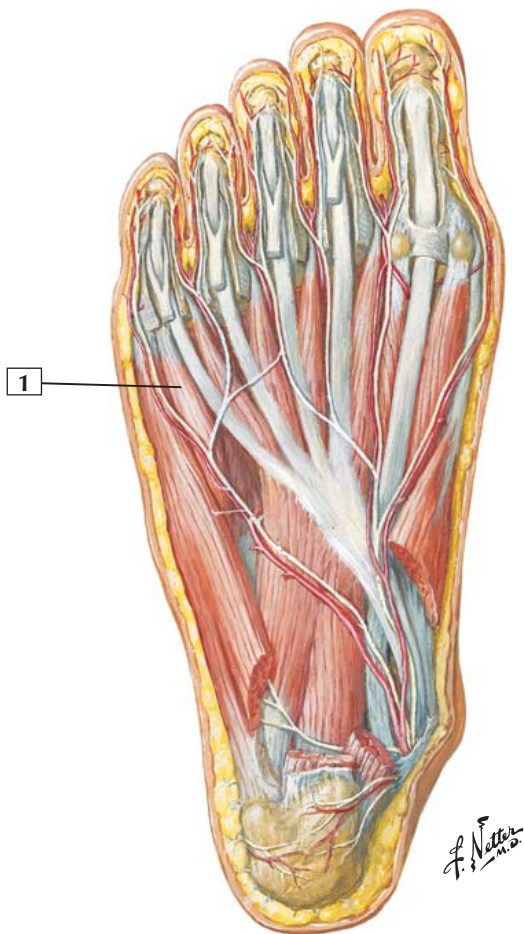
Origin (proximal): This muscle has 2 heads. The larger medial head arises from the medial surface of the calcaneus; the lateral head arises from the lateral border of the calcaneus.

Insertion (distal): The 2 portions of this muscle join into a flattened muscular band that inserts into the posterolateral margin of the tendon of the flexor digitorum longus.

Action: This muscle helps the flexor digitorum longus flex the terminal phalanges of the 4 lateral toes.

Innervation: Lateral plantar nerve (S2 and S3).

Comment: The quadratus plantae is unique, having no equivalent in the hand. Its primary role is to modify the effect of the flexor digitorum longus, which tends to pull obliquely across the foot. The quadratus plantae corrects this oblique motion.



1. Flexor digiti minimi brevis

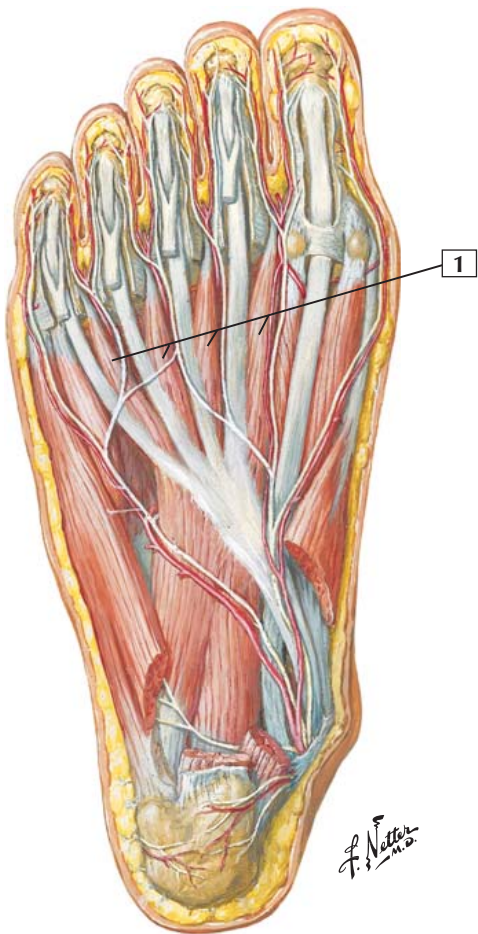
Origin (proximal): Arises from the base of the 5th metatarsal bone and the long plantar ligament.

Insertion (distal): Inserts onto the base of the proximal phalanx of the little toe.

Action: Flexes the proximal phalanx of the little toe at the metatarsophalangeal joint.

Innervation: Superficial branch of lateral plantar nerve (S2 and S3).

Comment: This muscle often resembles one of the interossei. Its tendon of insertion may blend laterally with that of the abductor digiti minimi.



1. Lumbrical muscles

Origin (proximal): Arise from the tendons of the flexor digitorum longus. The 1st, or most medial, lumbrical arises from the medial side of the tendon to the 2nd toe. The 2nd lumbrical arises from the 2 tendons that flank it, and the other 2 lumbricals arise from their flanking tendons.

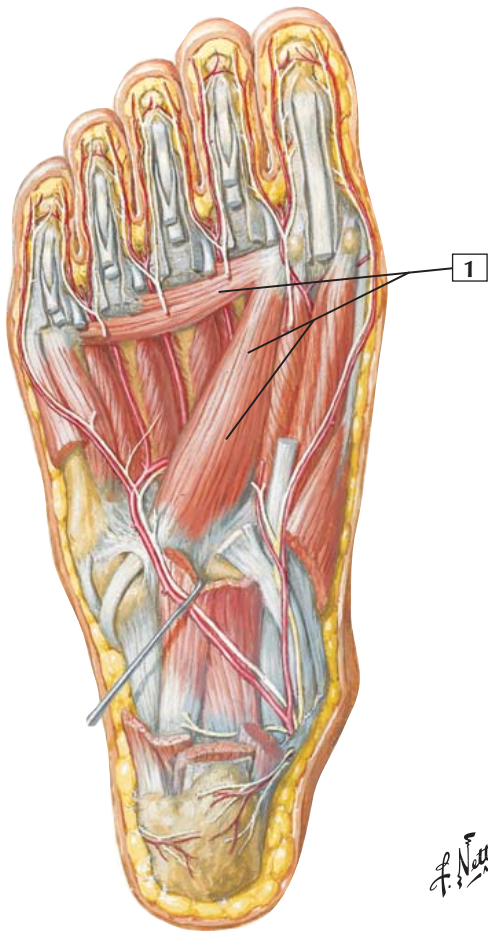
Insertion (distal): The tendons pass below the deep transverse metatarsal ligaments. They are inserted into the extensor expansions of the extensor digitorum longus on the dorsal surface of the proximal phalanges.

Action: Similar to the lumbricals in the hand, the lumbricals in the foot flex the proximal phalanges at the metatarsophalangeal joints and extend the 2 distal phalanges of the 4 lateral digits.

Innervation: The 1st lumbrical is innervated by the medial plantar nerve (S2 and S3). The 3 lateral lumbricals are innervated by the lateral plantar nerve (S2 and S3).

Comment: The lumbrical muscles in the foot act in a similar manner to those in the hand, which arise from the flexor digitorum profundus muscle tendons.

**Adductor Hallucis
(Transverse and Oblique Heads)**



*F. Netter
M.D.*

Adductor Hallucis (Transverse and Oblique Heads)

1. Adductor hallucis (transverse and oblique heads)

Origin (proximal): The oblique head arises from the bases of the 2nd to 4th metatarsal bones and the long plantar ligament. The transverse head arises from the plantar metatarsophalangeal ligaments of the 3rd, 4th, and 5th toes.

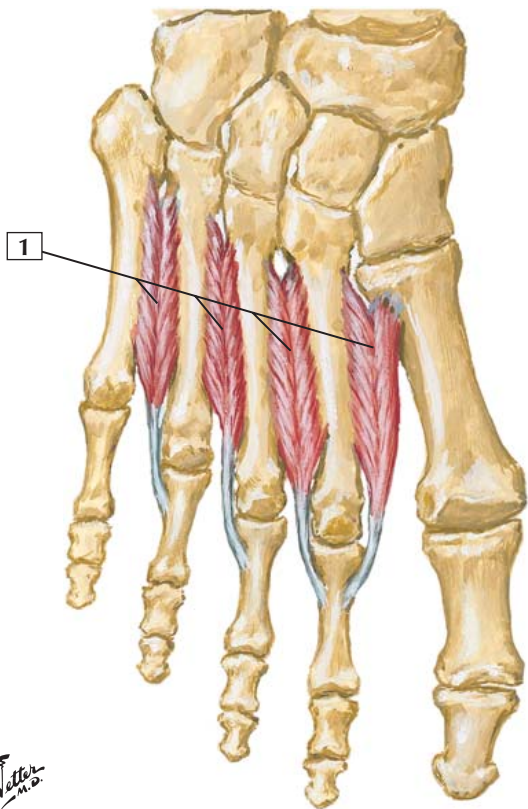
Insertion (distal): The 2 heads of the muscle converge, and their central tendon blends with that of the flexor hallucis brevis and shares the lateral sesamoid bone with that muscle. The common tendon inserts on the lateral side of the base of the proximal phalanx of the big toe.

Action: Adducts the big toe and flexes the proximal phalanx at the metatarsophalangeal joint. Also helps to maintain the transverse metatarsal arch of the foot.

Innervation: Deep branch of lateral plantar nerve (S2 and S3).

Comment: The transverse head of this muscle does not arise from a bone but from plantar ligaments.

Clinical: A bunion (hallux valgus) often occurs in women who wear shoes that are too narrow. In this deformity, the first metatarsal bone is displaced medially (varus) and the proximal phalanx is partially dislocated and displaced laterally (valgus). The lateral sesamoid bone also is displaced laterally.



1. Dorsal interosseous muscles

Origin (proximal): These 4 bipennate muscles arise by 2 heads from adjacent sides of the metatarsal bones.

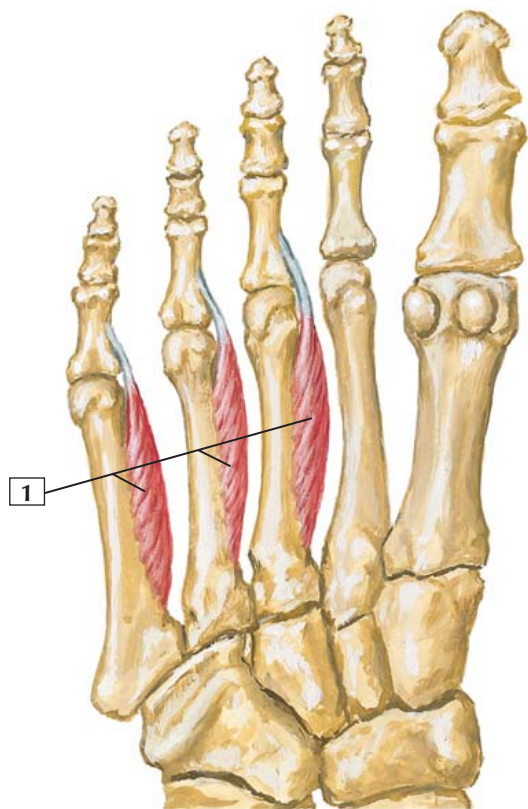
Insertion (distal): The 1st interosseous inserts into the medial aspect of the proximal phalanx of the 2nd toe. The 2nd through 4th interossei insert into the lateral sides of the 2nd to 4th toes.

Action: The dorsal interossei abduct the toes in relation to an imaginary longitudinal axis of the foot drawn through the 2nd toe. They also flex the proximal phalanx at the metatarsophalangeal joint and extend the distal phalanges.

Innervation: Lateral plantar nerve (S2 and S3).

Comment: Plantar and dorsal interosseous muscles form the 4th layer of the foot. Similar to the interossei of the hand, the dorsal interossei abduct the digits (toes) and extend the distal phalanges.

Clinical: One can test the dorsal interossei muscles by asking the patient to spread the toes against resistance. Likewise, one can place a finger between the toes, ask the patient to adduct the toes (done by the plantar interossei muscles), and feel the resistance (muscle strength) against one's finger.



1. Plantar interosseous muscles

Origin (proximal): These 3 muscles arise from the bases and medial sides of the bodies of the 3rd, 4th, and 5th metatarsal bones.

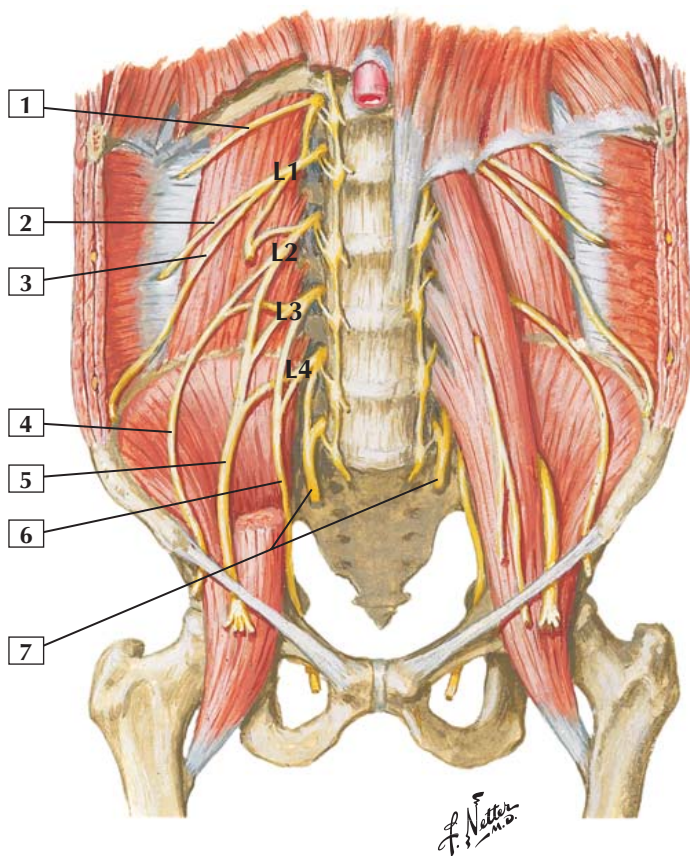
Insertion (distal): They insert into the medial sides of the bases of the proximal phalanges of the same toes and into the dorsal digital aponeurosis of the tendons of the extensor digitorum longus.

Action: Plantar interossei adduct the 3rd, 4th, and 5th toes toward the axis of the foot, an imaginary longitudinal line extending through the 2nd toe. They also flex the proximal phalanx at the metatarsophalangeal joint and extend the distal phalanges.

Innervation: Lateral plantar nerve (S2 and S3).

Comment: Similar to the interossei of the hand, the plantar interosseous muscles adduct the digits (toes) and flex the proximal phalanges while extending the distal phalanges.

Clinical: One can test these muscles by placing a finger between the toes and asking the patient to adduct the toes and feel the resistance (muscle strength) against the finger.



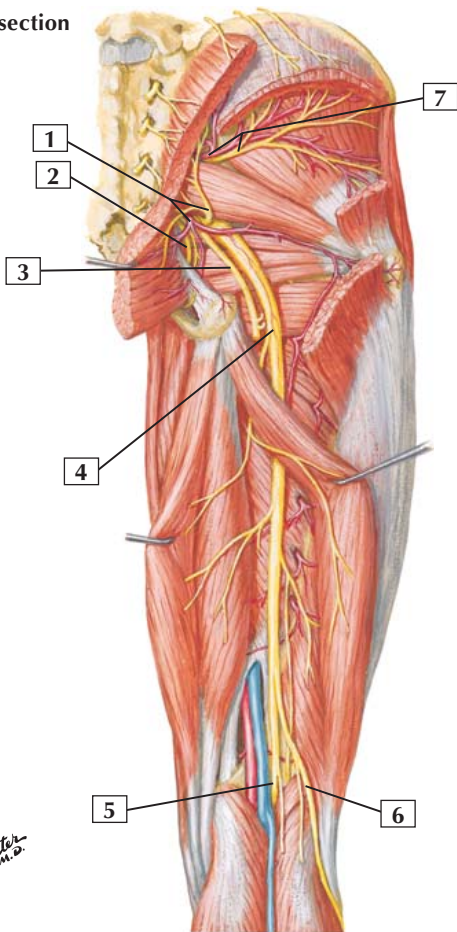
1. Subcostal nerve (T12)
2. Iliohypogastric nerve
3. Ilioinguinal nerve
4. Lateral femoral cutaneous nerve
5. Femoral nerve
6. Obturator nerve
7. Lumbosacral trunks

Comment: Nerves of the lumbar plexus arise from the ventral rami of L1-4. These nerves, along with the subcostal nerve (T12), innervate the muscles of the lower trunk and send branches to muscles of the anterior and medial compartments of the thigh (femoral and obturator nerves).

The femoral nerve arises from L2, L3, and L4 and innervates the extensors of the knee. Likewise, the obturator nerve arises from L2, L3, and L4. In the thigh, it innervates the medial compartment muscles, which are adductors of the hip.

Similar to the cervical plexus (C1-4) and the brachial plexus (C5-T1), the lumbar plexus is a somatic nerve plexus that innervates skeletal muscles and conveys sensation from the skin, muscles, and joints. Similar to all somatic nerves, postganglionic sympathetic fibers of the autonomic nervous system also travel within these nerves and innervate vasomotor smooth muscle and the arrector pili smooth muscle associated with the hair follicles in the skin.

Deep dissection



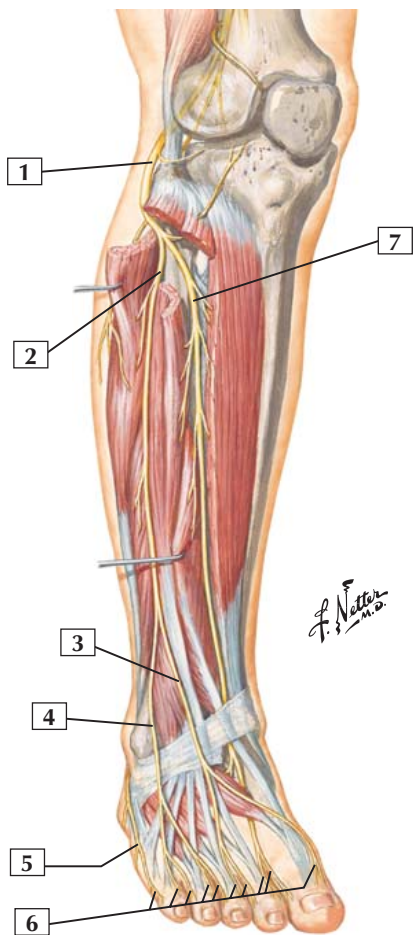
Nerves of Gluteal Region and Thigh: Posterior View

1. Inferior gluteal artery and nerve
2. Pudendal nerve
3. Posterior cutaneous nerve of thigh
4. Sciatic nerve
5. Tibial nerve
6. Common fibular (peroneal) nerve
7. Superior gluteal artery and nerve

Comment: Nerves to the gluteal region and posterior thigh arise from the sacral plexus. They come largely from the ventral rami of L4-S4.

The major nerves of the gluteal region are the superior and inferior gluteal nerves. The largest nerve of the sacral plexus is the sciatic nerve, made up of ventral roots of L4-S3. The sciatic nerve innervates all muscles of the posterior compartment of the thigh. Through its 2 terminal branches, the tibial and common fibular (peroneal) nerves, it also innervates all muscles below the knee.

Clinical: Intramuscular gluteal injections are given in the upper outer quadrant of the buttock to avoid injuring the sciatic nerve, which passes just inferior to or through the piriformis muscle in the middle of the gluteal region.

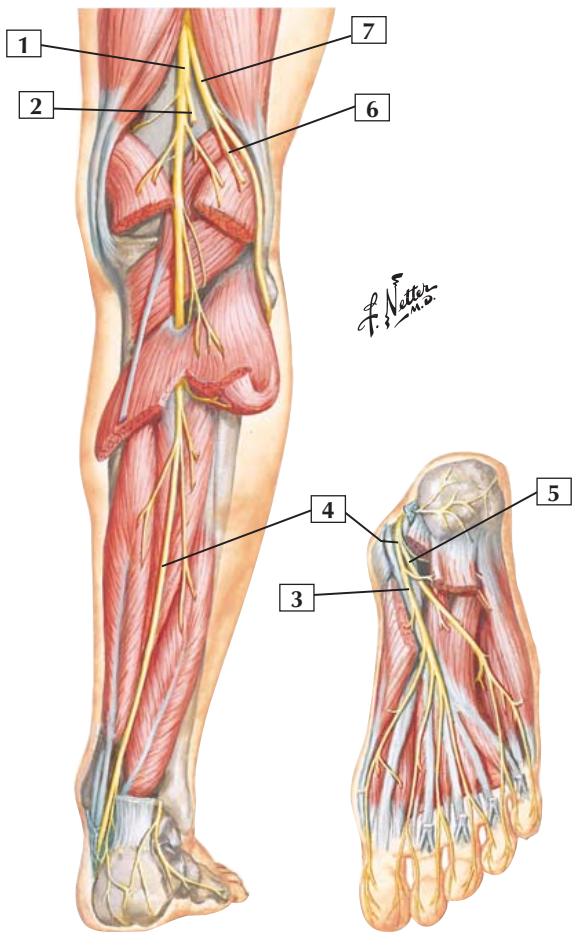


1. Common fibular (peroneal) nerve (L4, L5, S1, S2)
2. Superficial fibular (peroneal) nerve
3. Medial dorsal cutaneous nerve
4. Intermediate dorsal cutaneous nerve
5. Lateral dorsal cutaneous nerve (branch of sural nerve)
6. Dorsal digital nerves
7. Deep fibular (peroneal) nerve

Comment: The common fibular nerve is a direct extension of the sciatic nerve. It wraps superficially around the head of the fibula and divides into a superficial branch and a deep branch.

The superficial fibular nerve innervates muscles of the lateral compartment of the leg, which are essentially involved in eversion of the foot. The deep fibular nerve innervates muscles of the anterior compartment of the leg and muscles on the dorsum of the foot. These muscles are essentially dorsiflexors of the foot at the ankle and extensors of the toes.

Clinical: The common fibular nerve is the most commonly injured nerve of the lower limb. This nerve is vulnerable to compression injury, usually from direct trauma, where it wraps around the head of the fibula. When injured, the patient may present with footdrop (inability to dorsiflex at the ankle) and an inability to evert the foot.



Tibial Nerve

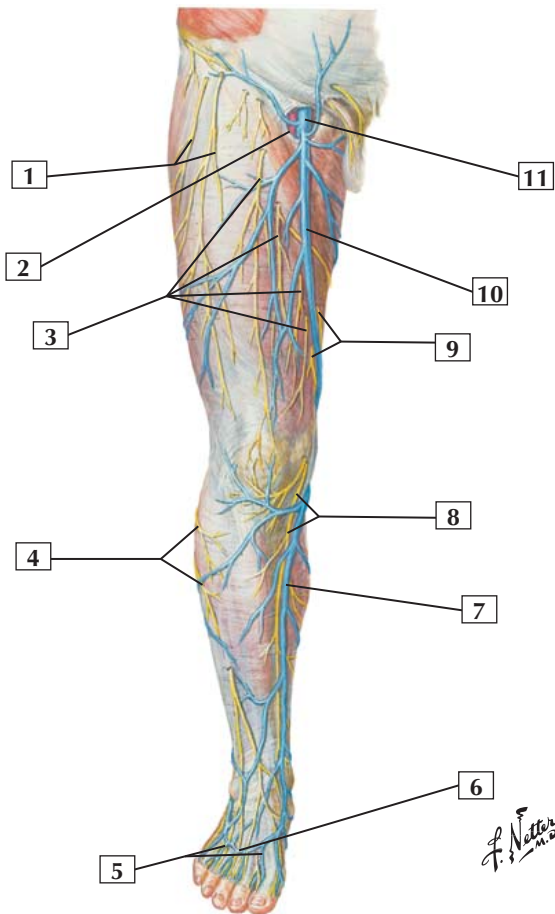
1. Tibial nerve (L4, L5, S1, S2, S3)
2. Medial sural cutaneous nerve (cut)
3. Medial plantar nerve
4. Tibial nerve
5. Lateral plantar nerve
6. Lateral sural cutaneous nerve (cut)
7. Common fibular (peroneal) nerve

Comment: The tibial nerve is a direct extension of the sciatic nerve. It innervates muscles of the posterior compartment of the leg and the intrinsic muscles on the plantar surface of the foot. The muscles of the posterior compartment of the leg are essentially plantarflexors at the ankle and flexors of the toes. These muscles also can participate in inversion.

Clinical: Because of its deep location in the posterior compartment of the leg, this nerve is relatively protected from direct trauma. It can be injured during inflammation of the muscles of the posterior compartment (compartment syndromes) when swelling occurs sufficient to compress the tibial nerve.

A lesion to the tibial nerve may result in loss of plantarflexion and weakened inversion of the foot, leading to a shuffling gait.

Lacerations on the sole of the foot may damage the terminal branches of the tibial nerve, the medial and lateral plantar nerves, which innervate the intrinsic muscles of the foot.



F. Netter M.D.

WWW.YAZDANPRESS.COM
**Superficial Nerves and Veins of Lower
Limb: Anterior View**

1. Lateral femoral cutaneous nerve
2. Saphenous opening (fossa ovalis)
3. Anterior femoral cutaneous nerves of thigh (from femoral nerve)
4. Branches of lateral sural cutaneous nerve (from common fibular [peroneal] nerve)
5. Dorsal metatarsal veins
6. Dorsal venous arch
7. Great saphenous vein
8. Saphenous nerve (terminal branch of femoral nerve)
9. Cutaneous branches of obturator nerve
10. Great saphenous vein
11. Femoral vein

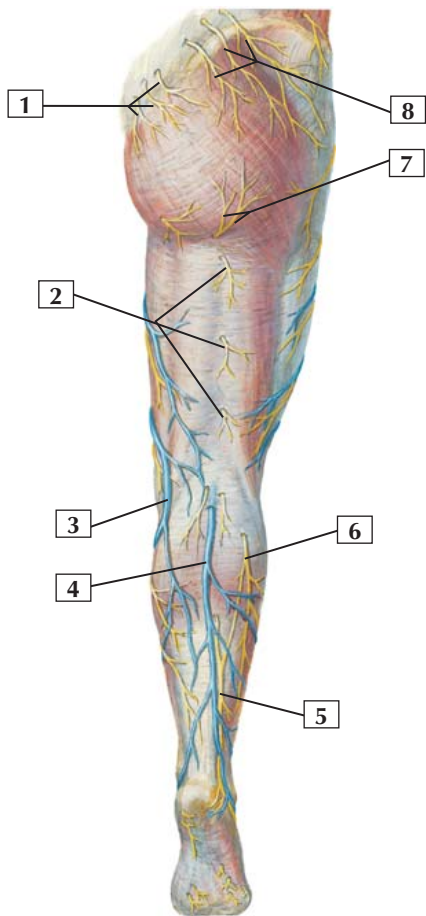
Comment: The cutaneous nerves of the thigh and leg are branches of the femoral, obturator, and sciatic nerves. The lateral cutaneous nerve of the thigh arises directly from the lumbar plexus.

The great saphenous vein arises from a plexus of dorsal veins over the foot. It ascends along the medial aspect of the leg, knee, and thigh to drain into the femoral vein. Numerous superficial tributaries drain into the great saphenous vein. Perforating branches from the saphenous and its tributaries communicate with deep veins accompanying the femoral and tibial arteries.

The superficial and deep veins of the lower limb, similar to the veins of the upper limb, possess venous valves to aid in venous return to the heart against gravity.

Clinical: The great saphenous vein may be harvested and used as a vessel graft (e.g., in coronary bypass).

The superficial veins of the lower limb may become varicose (dilated), usually because their valves become incompetent and allow venous blood to back up and reverse flow in the veins.



*F. Netter
M.D.*

Superficial Nerves and Veins of Lower Limb: Posterior View

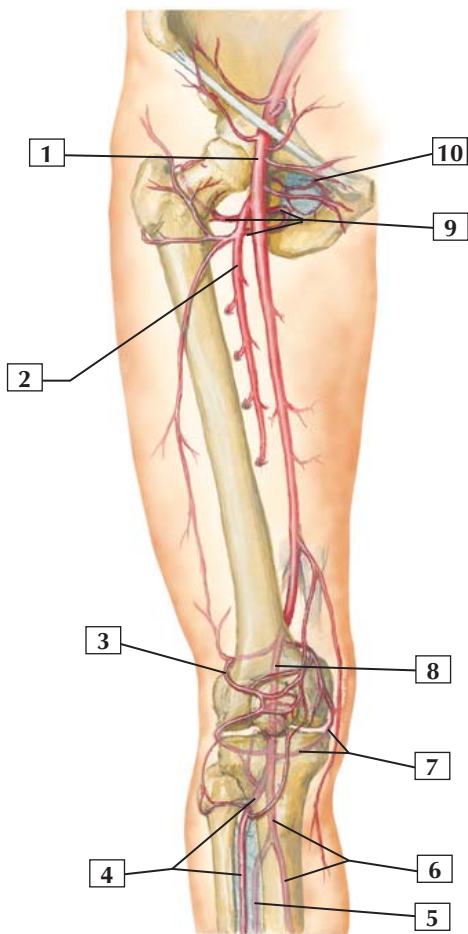
1. Middle cluneal nerves (from dorsal rami of S1, S2, S3)
2. Branches of posterior cutaneous nerve of thigh
3. Great saphenous vein
4. Small saphenous vein
5. Sural nerve
6. Lateral sural cutaneous nerve (from common fibular [peroneal] nerve)
7. Inferior cluneal nerves (from posterior cutaneous nerve of thigh)
8. Superior cluneal nerves (from dorsal rami of L1, L2, L3)

Comment: The sural nerve is formed by the union of cutaneous nerves from the tibial and common fibular (peroneal) nerves. It courses with the small saphenous vein.

The small saphenous vein receives numerous superficial tributaries. Perforating branches from the small saphenous vein and its tributaries communicate with deep veins accompanying the tibial artery and its branches. The small saphenous vein drains into the popliteal vein behind the knee.

The superficial and deep veins of the lower limb, similar to the veins of the upper limb, possess venous valves to aid in venous return to the heart against gravity.

Clinical: Inactivity and venous stasis can have grave consequences for the veins of the lower limb. Deep venous thrombosis can result and a thromboembolus can pass toward the heart and become lodged in the small capillary networks of the lung, obstructing a pulmonary artery.



F. Netter M.D.

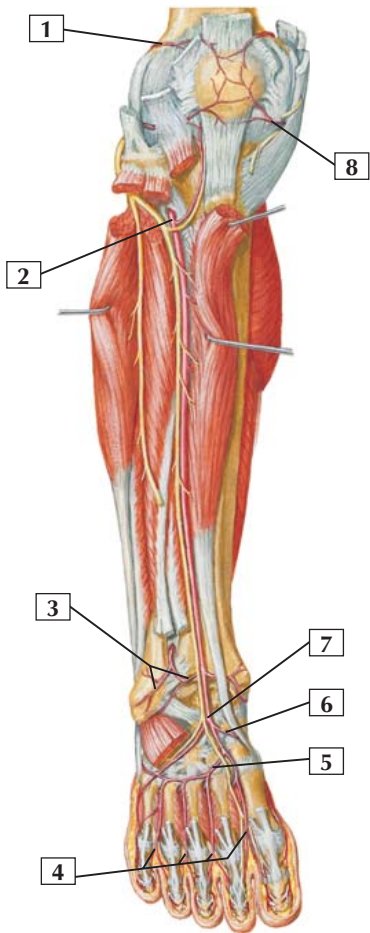
1. Femoral artery
2. Deep artery of thigh
3. Superior lateral genicular artery
4. Anterior tibial artery
5. Fibular (peroneal) artery (phantom)
6. Posterior tibial artery (phantom)
7. Inferior medial genicular artery (partially in phantom)
8. Popliteal artery (phantom)
9. Medial circumflex femoral artery
10. Obturator artery

Comment: The femoral artery is a continuation of the external iliac artery. Its deep branch provides blood to the deep muscles of the thigh.

Medial and lateral circumflex femoral branches provide a rich anastomosis around the hip joint. Similarly, a rich anastomosis around the knee joint is provided by medial and lateral pairs of genicular arteries.

When the femoral artery passes through the adductor hiatus of the adductor magnus muscle, it assumes a position behind the knee (popliteal fossa), becoming the popliteal artery. Inferior to the knee, the popliteal artery divides into anterior and posterior tibial branches.

Clinical: Arterial pulses may be taken over the proximal femoral artery in the femoral triangle or posterior to the knee in the popliteal fossa over the popliteal artery.



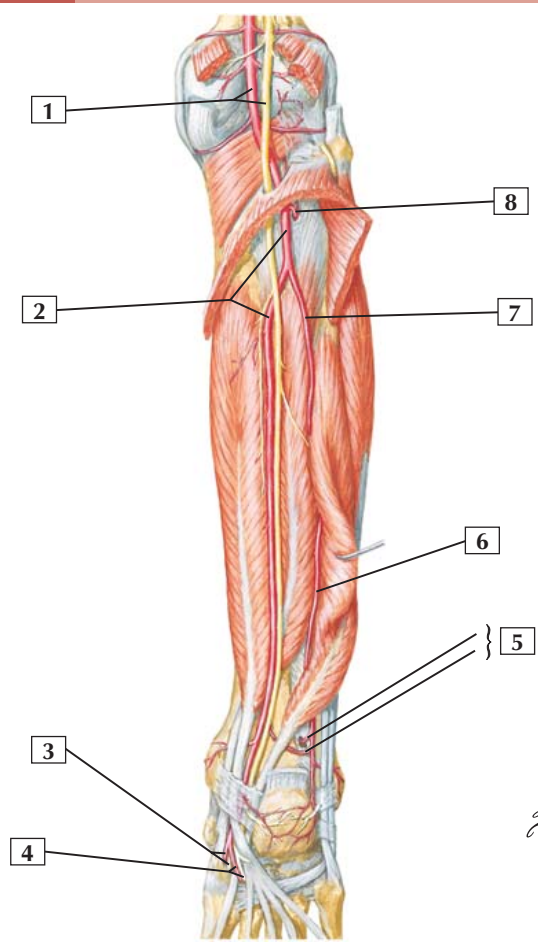
F. Netter M.D.

1. Superior lateral genicular artery
2. Anterior tibial artery
3. Anterior lateral malleolar artery
4. Dorsal digital arteries
5. Arcuate artery
6. Medial tarsal artery
7. Dorsalis pedis artery
8. Inferior medial genicular artery

Comment: The anterior tibial artery, a branch of the popliteal, supplies the anterior compartment of the leg and the dorsum of the foot. It is accompanied by the deep fibular (peroneal) nerve, which supplies the muscles of the anterior compartment.

At the ankle, there is a rich anastomosis from malleolar, tarsal, and arcuate arteries.

Clinical: Two pulses are commonly taken on the distal lower limb. The posterior tibial pulse is felt between the medial malleolus and the calcaneal tendon. The dorsalis pedis artery is a continuation of the anterior tibial artery, and its pulse may be palpated on the dorsum of the foot just lateral to the tendon of the extensor hallucis longus as it emerges from the extensor retinaculum.



F. Natter
M.D.

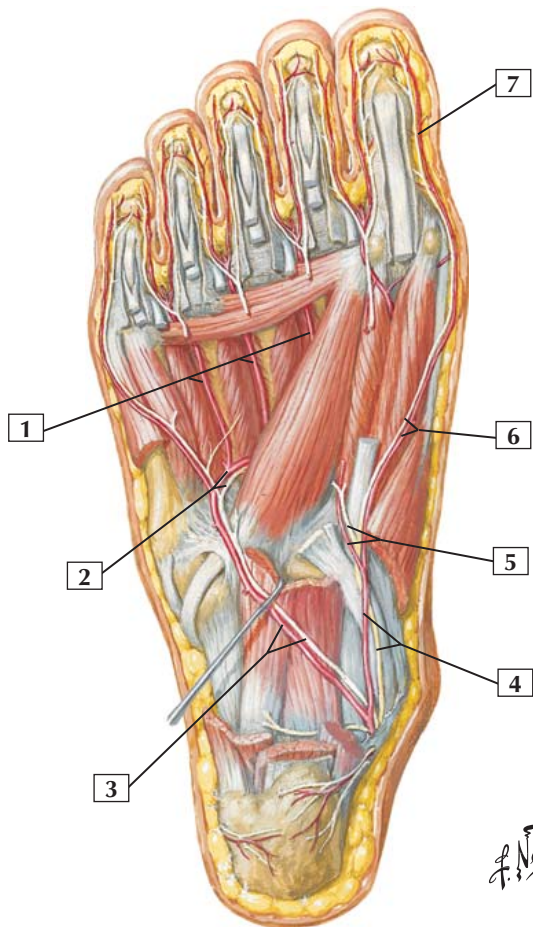
1. Popliteal artery and tibial nerve
2. Posterior tibial artery
3. Medial plantar artery and nerve
4. Lateral plantar artery and nerve
5. Fibular (peroneal) artery (Perforating branch and Communicating branch)
6. Fibular (peroneal) artery
7. Fibular (peroneal) artery
8. Anterior tibial artery

Comment: The posterior tibial artery is a continuation of the popliteal artery. Below the knee, it gives rise to the fibular (peroneal) artery, which courses deep to the flexor hallucis longus muscle.

As the posterior tibial artery passes inferiorly to the medial malleolus and enters the sole of the foot, it divides into medial and lateral plantar arteries.

The tibial nerve accompanies the posterior tibial artery along most of its course.

Clinical: The tibial artery pulse can be felt midway between the medial malleolus and the calcaneal tendon. This artery passes beneath the sustentaculum tali of the calcaneus with the tibial nerve and long flexor tendons.



1. Plantar metatarsal arteries
2. Deep plantar arterial arch and deep branches of lateral plantar nerve
3. Lateral plantar artery and nerve
4. Medial plantar artery and nerve
5. Deep branches of medial plantar artery and nerve
6. Superficial branches of medial plantar artery and nerve
7. Proper plantar digital branch of superficial branch of medial plantar artery

Comment: The medial and lateral plantar arteries are continuations of the posterior tibial artery.

The lateral plantar artery is much larger than the medial branch. It forms the major portion of the plantar arch, which anastomoses with other plantar branches and the dorsalis pedis artery.

Plantar metatarsal arteries arise from this plantar arch and give rise to proper plantar digital branches.

Clinical: Puncture wounds or lacerations to the sole of the foot may bleed profusely because of the rich vascular anastomoses of the plantar arches. Moreover, because of the tight, deep compartments containing tendons, muscles and ligaments in the sole, controlling the bleeding may be problematic.